Red Rashes

Common Inflammatory Rashes Seen by Dermatologists

- Atopic dermatitis
- Seborrheic dermatitis
- Psoriasis
- Tinea

Atopic dermatitis

- Pathogenesis: immune mediated
- Epidemiology:
  - 10% of children
  - Most present before age 7
  - Atopic diathesis: 75% have a personal or family history of allergic disease

Atopic dermatitis

- Clinical: “the itch that rashes”
  - Lesions:
    - Acute: erythema and vesiculation
    - Subacute: papular
    - Chronic: brown/red, lichenification
  - Distribution:
    - Infancy: face, extensors of extremities
    - Childhood: neck, antecubital and popliteal fossae
    - Adulthood: fossae, hands/feet

Atopic dermatitis

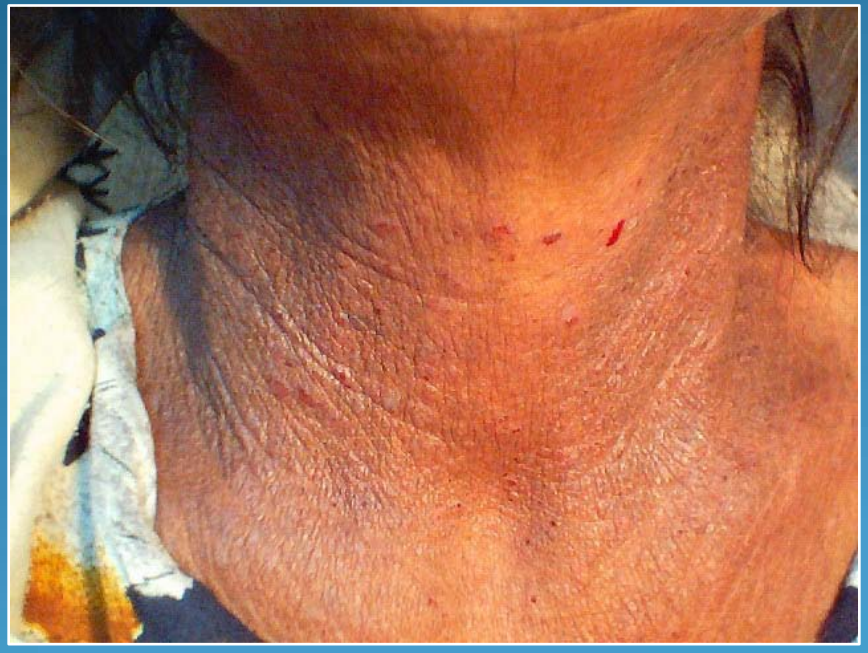

Chronic atopic dermatitis: lichenification

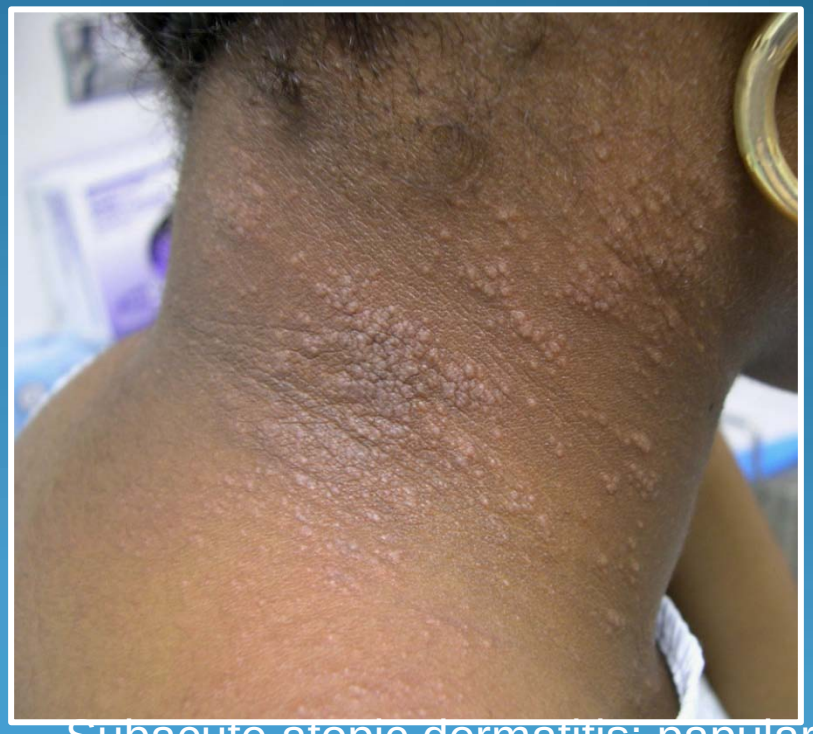

Subacute atopic dermatitis: papular

Atopic dermatitis

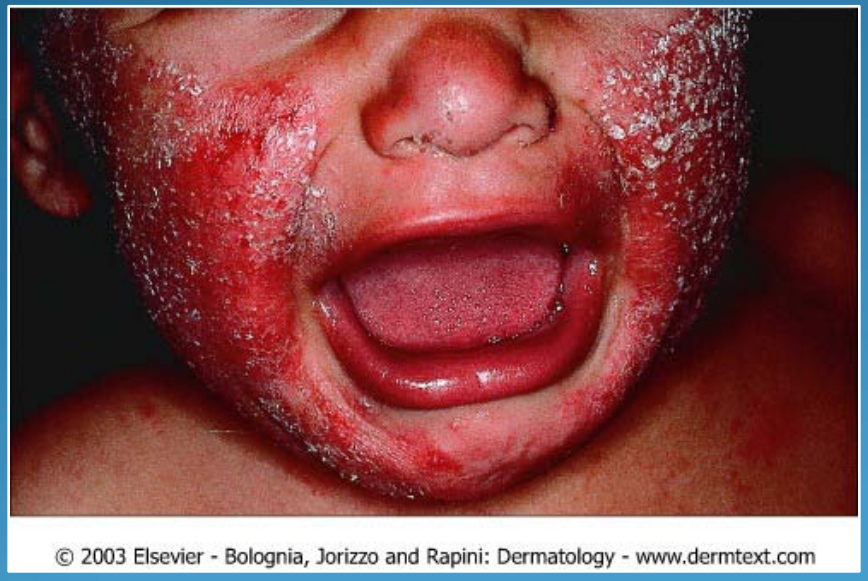

Atopic dermatitis: infant

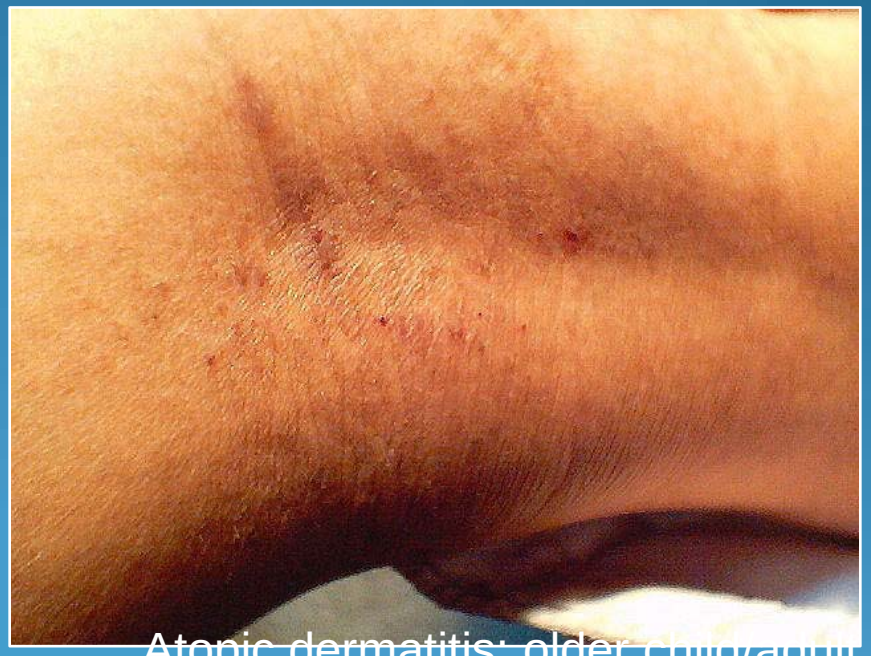

Atopic dermatitis: older child/adult

Atopic dermatitis

- Clinical:
  - Other findings:
    - Pityriasis alba
    - Dennie-Morgan lines, allergic shiners
    - Keratosis Pilaris
    - Icthyosis Vulgaris
    - Hyperlinear palms

Atopic dermatitis: associations

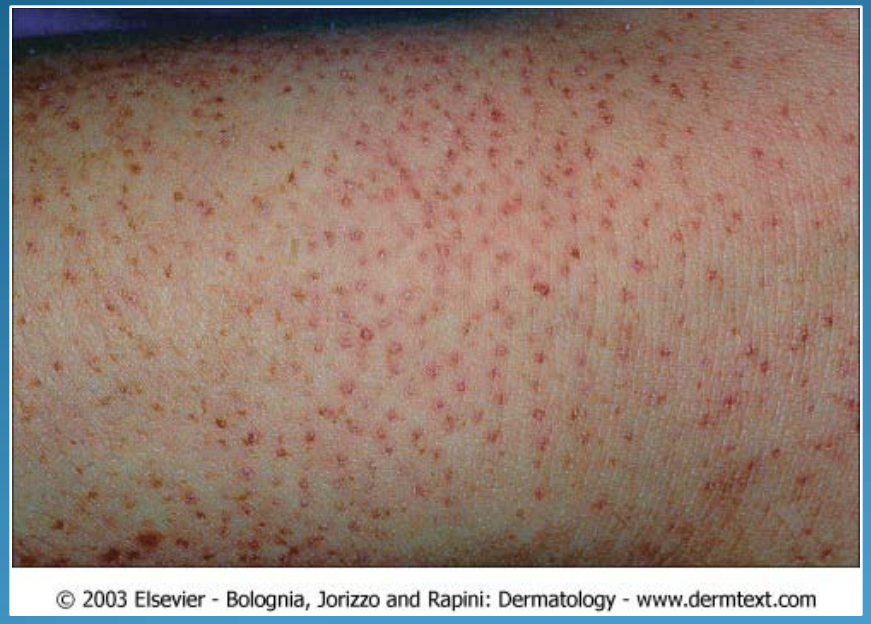

Keratosis Pilaris

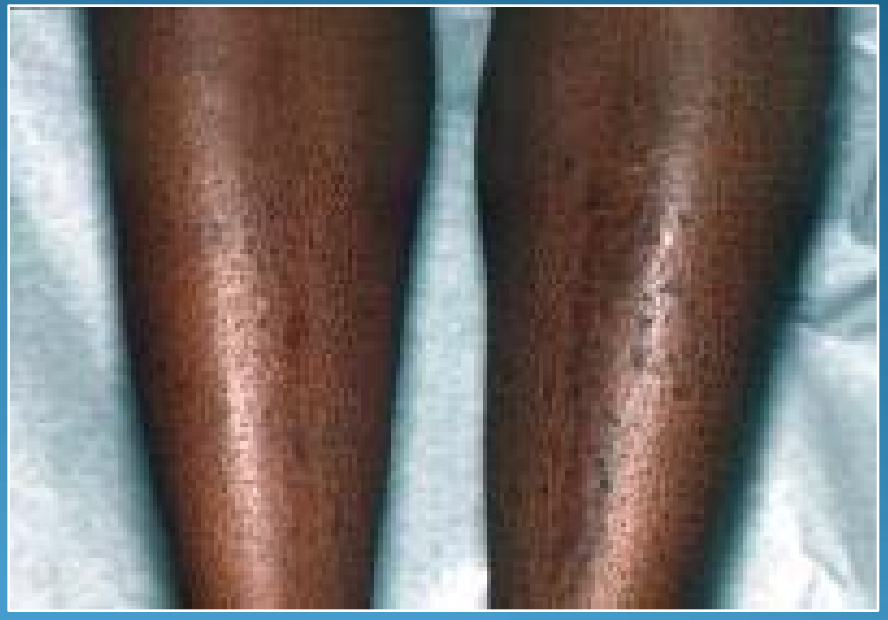

Icthyosis vulgaris

Atopic dermatitis: associations

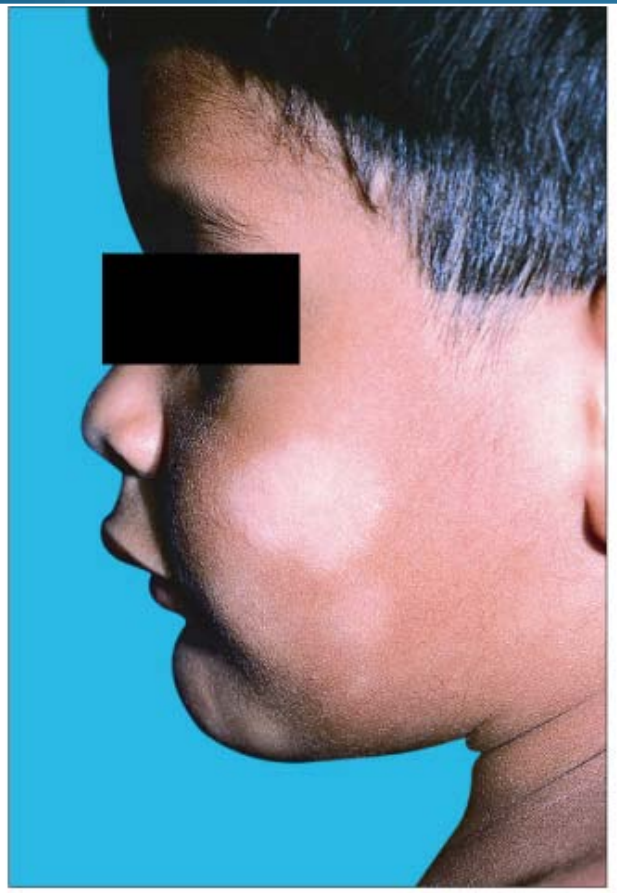

© 2003 Elsevier - Bolognia, Jorizzo and Rapini: Dermatology - www.dermtext.com

Pityriasis Alba

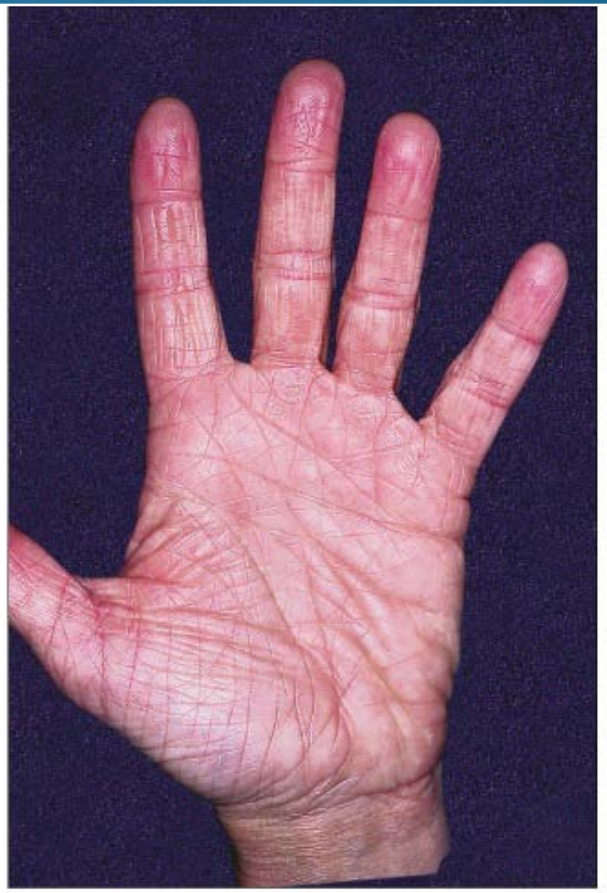

© 2003 Elsevier - Bolognia, Jorizzo and Rapini: Dermatology - www.dermtext.com

Hyperlinear palms

Atopic dermatitis

- Diagnosis
  - Clinical: pruritis, rash, chronicity, atopy
  - Supportive: elevated IgE, eosinophilia, RAST tests
- Differential Diagnosis
  - Allergic/contact dermatitis
  - Seborrheic dermatitis
  - Infections (fungal)
  - Congenital disorders (e.g. Netherton's, SCID, Wiskott-Aldrich, Chediak-Higashi)

Atopic dermatitis

- Treatments
  - “Soak and Grease”: hydration, steroid, +/-occlusion
    - Lowest potency possible
      - Role of immunomodulators unclear
      - Vaseline or other emollients additionally
    - Wet pajamas
    - Sauna suit

Atopic dermatitis

- Additional treatments:
  - Avoid irritants: wool, allergens, dryness
  - Systemic therapy: PUVA, azathioprine
  - Tar: anti-inflammatory
  - Antihistamine: sedation effect
  - Antibiotics: low threshold
    - Gm+ coverage (e.g. dicloxacillin, cephalexin)
    - Topical vioform

Atopic dermatitis

- Complications:
  - Id reaction
  - Bacterial infection
  - Fungal infection
  - Viral infection
    - Eczema herpeticum: HSV superinfection
    - Eczema vaccinatum: vaccinia superinfection; caution re: smallpox vaccine!

Atopic dermatitis

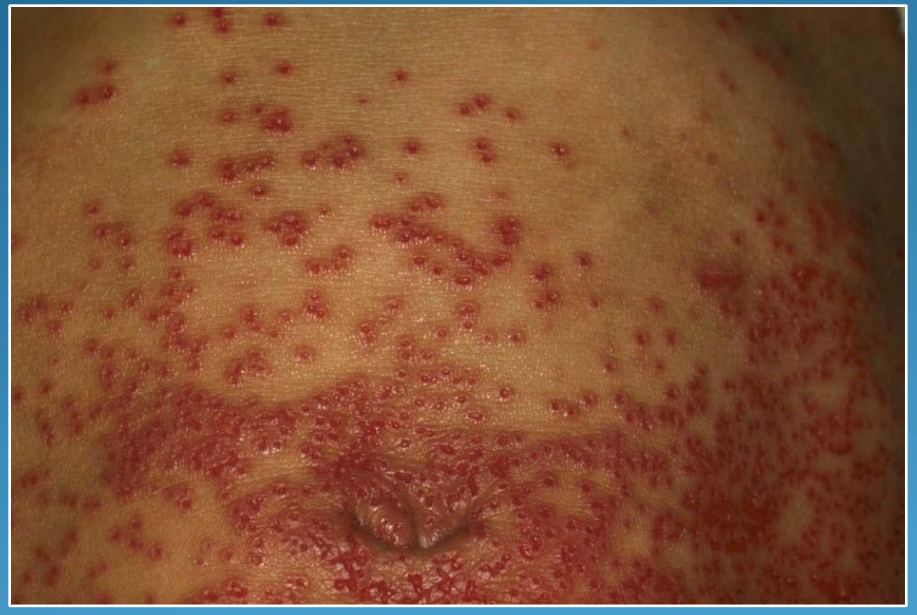

Eczema herpeticum: note the punched out erosions

Eczema vaccinatum

Atopic dermatitis

- What three components make-up the atopic diathesis?
- Where would you expect to see eczema in a 4-month old? Bonus: at what age to children have a coordinated scratch?
- Should I use steroids on infected appearing lesions?
- What is the concern about the smallpox vaccine and eczema?

???

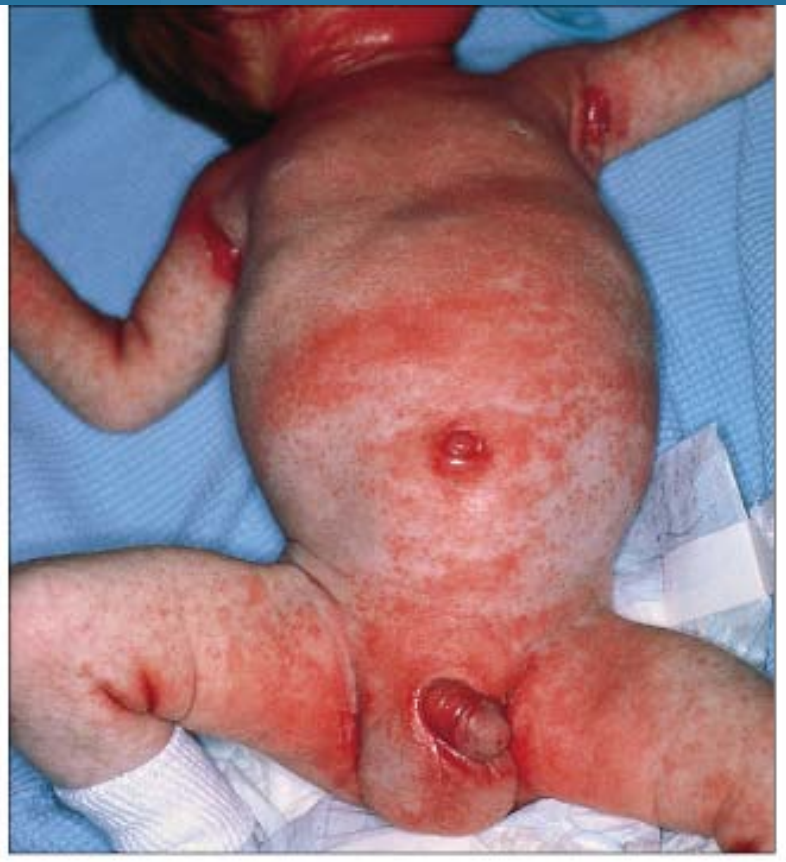

Seborrheic Dermatitis

- Pathogenesis: reaction to ubiquitous yeast, *pityrosporum ovale*
- Epidemiology:
  - Affects 3-5% of healthy population
  - Bimodal peaks: infancy (2-10 weeks, post-puberty)
  - Severe in HIV and Parkinson's disease

Seborrheic dermatitis

- Clinical:
  - Erythematous patches with oily scale
  - Bilaterally symmetric
  - Seborrheic areas:
    - Scalp (may be a dry scale)
    - Eyebrows
    - Nasolabial folds, central face
    - Ears
    - Axillae
    - Central chest
    - Groin

Seborrheic dermatitis

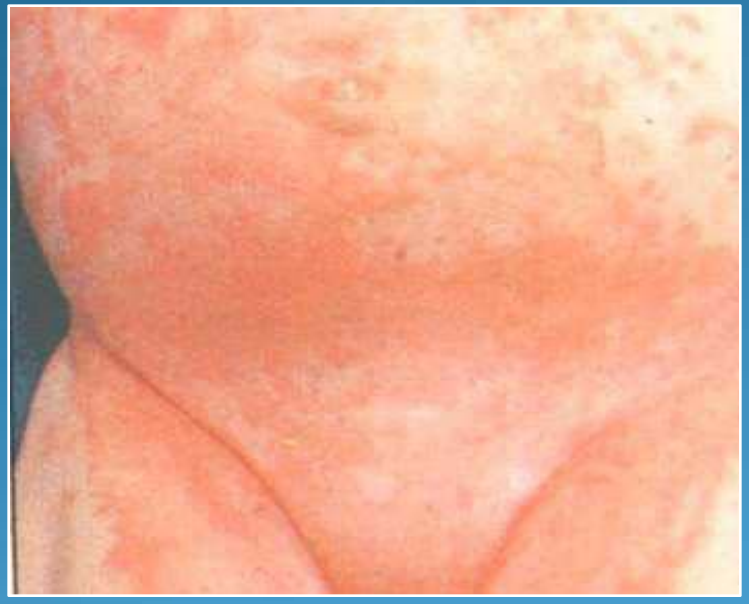

SebDerm: groin of child

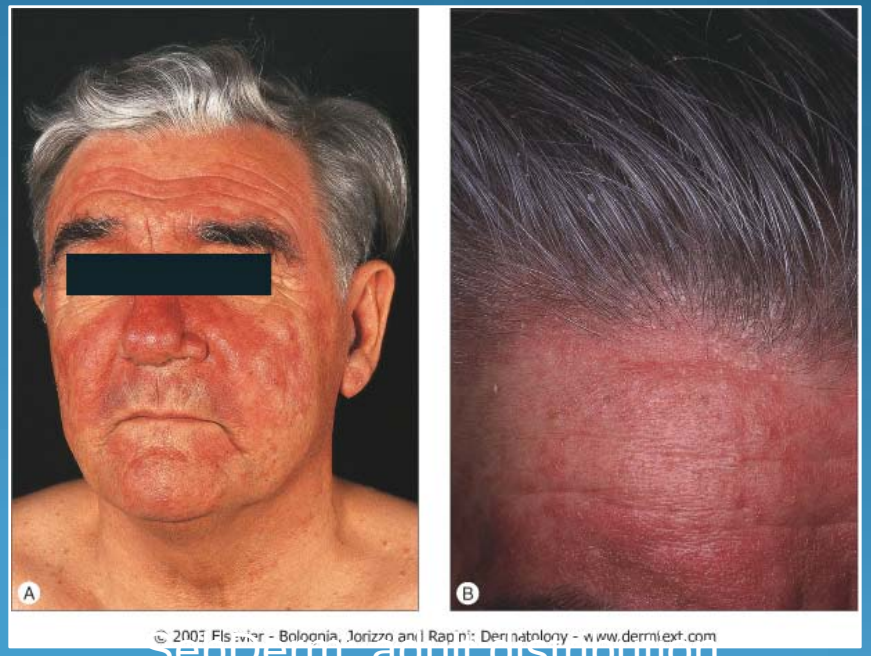

SebDerm: adult distribution

Seborrheic dermatitis

- Diagnosis:
  - Clinical
    - Distribution very helpful
- Differential diagnosis:
  - Atopic dermatitis
  - Psoriasis (overlap?)
  - Lupus
  - Rosacea
  - Congenital (e.g. Histiocytosis, Acrodermatitis enteropathica)

Seborrheic dermatitis

- Treatments:
  - Acute and maintenance
  - Keratolytics: salicylic acid, oils
  - Decrease yeast:
    - Selenium sulfide shampoo 2.5% or OTC 1%
    - Ketoconazole shampoo 2% or OTC 1%; may also add ketoconazole cream
    - Ciclopirox shampoo and/or cream
    - Zinc Pyrithione
  - Decrease inflammation:
    - Low potency steroid (e.g. 1% HC or desonide)
    - Steroid scalp solution
    - Steroid shampoo

Seborrheic dermatitis

- Complications:
  - Post inflammatory hypopigmentation
  - Cradle cap: thick, adherent scale of seb derm on the scalp in infancy; resolves by age 1
    - Treatment: frequent washings with baby shampoo or anti-fungals

Seborrheic dermatitis

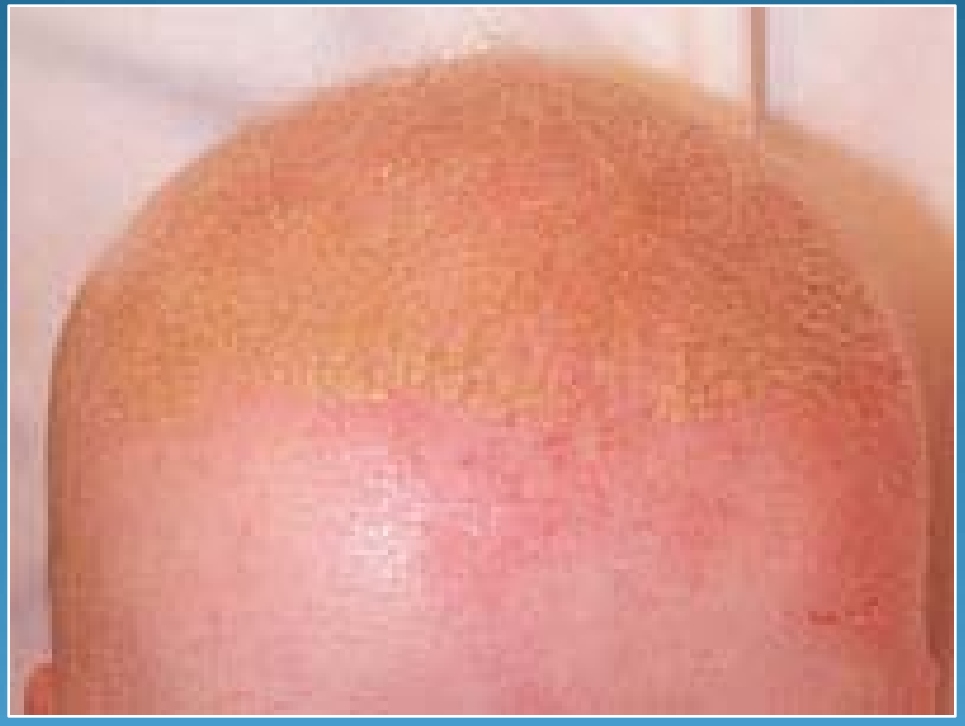

Cradle cap

Seborrheic dermatitis

- True or false: Seborrheic dermatitis may affect the eye lid margins?
- At what age does seborrheic dermatitis of infancy usually resolve?
- What is the presumed causative organism of seborrheic dermatitis?

What does this person have?

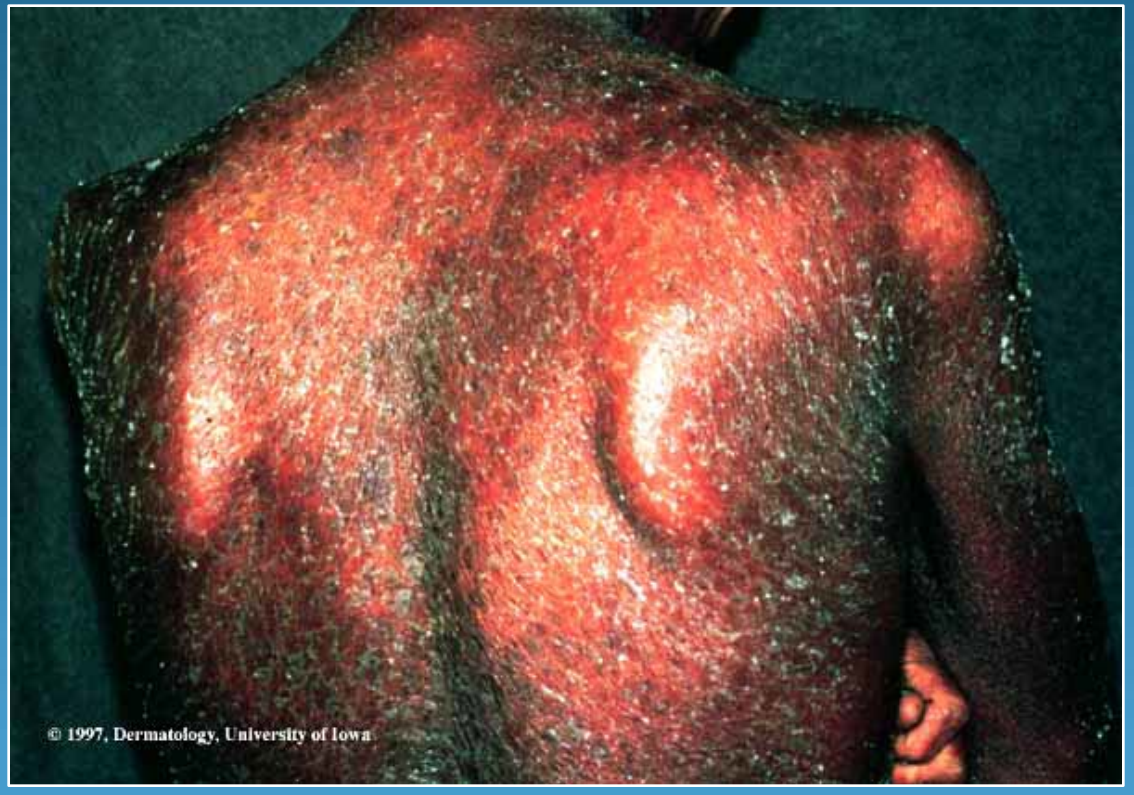

Psoriasis

- Pathogenesis
  - T-cell mediated
  - Increased epidermal turnover
  - Infectious?
- Epidemiology
  - Affects 1% of the population
  - Familial history, twin studies
  - Age of onset usually in 20s
    - Younger age, more severe presentation

Psoriasis

- Clinical: “classic”
  - Sharply demarcated erythematous plaques with thick, silvery scale
  - Locations: scalp, elbows, knees; ears, intergluteal cleft
  - Nails involved in close to 50%

Psoriasis: classic plaque

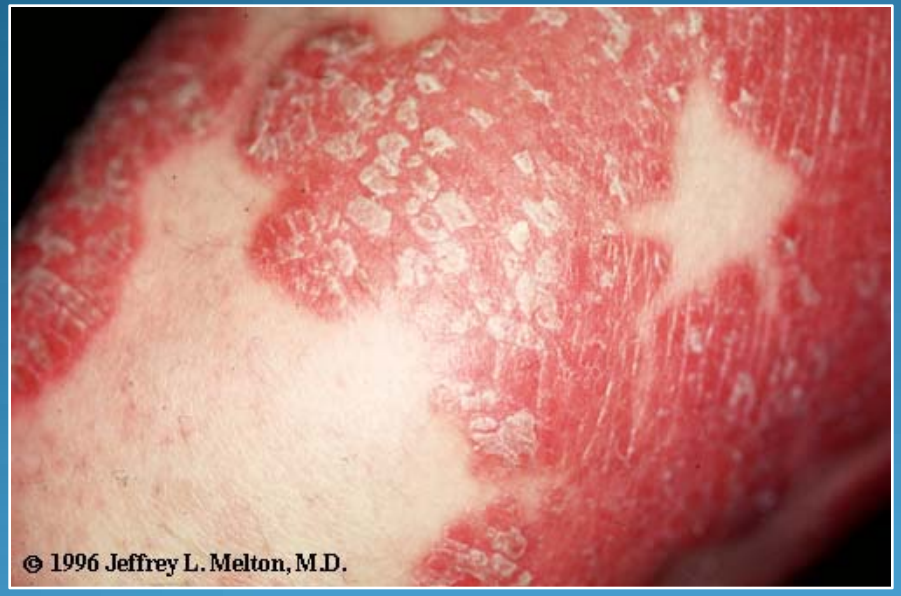

Red plaque with micaceous scale

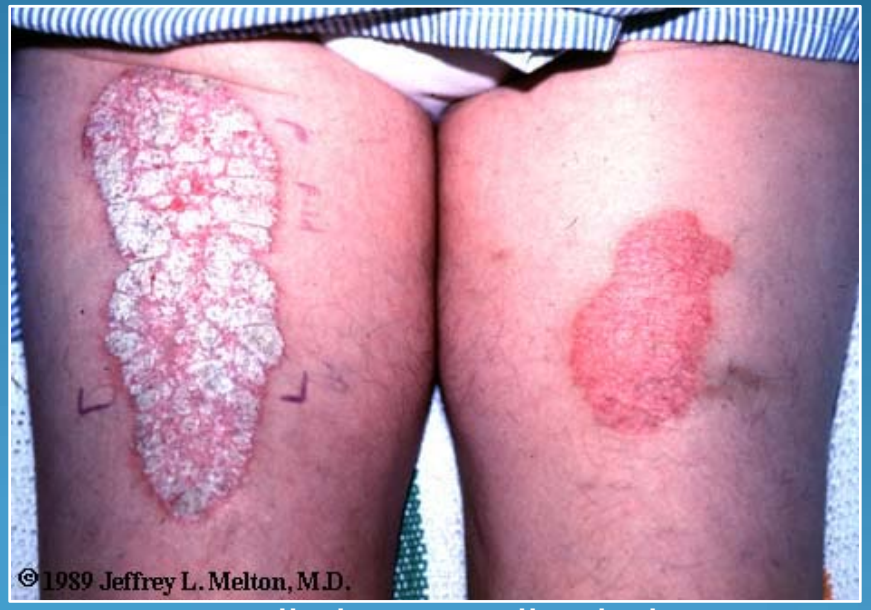

Well circumscribed plaques

Psoriasis: classic plaque

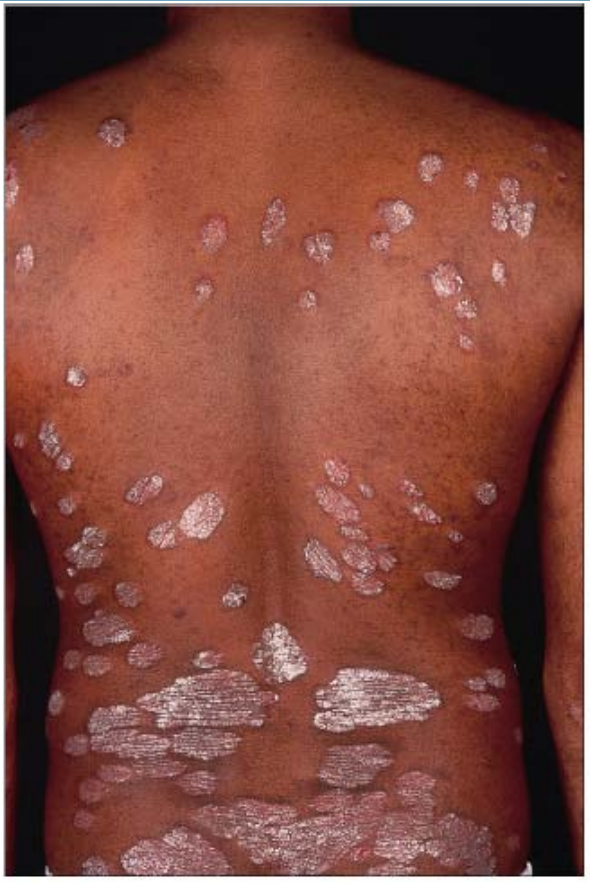

Widespread psoriasis: gluteal involvement

Psoriasis: nails

- Nails:
  - Pitting
  - Onycholysis
  - Oil spots

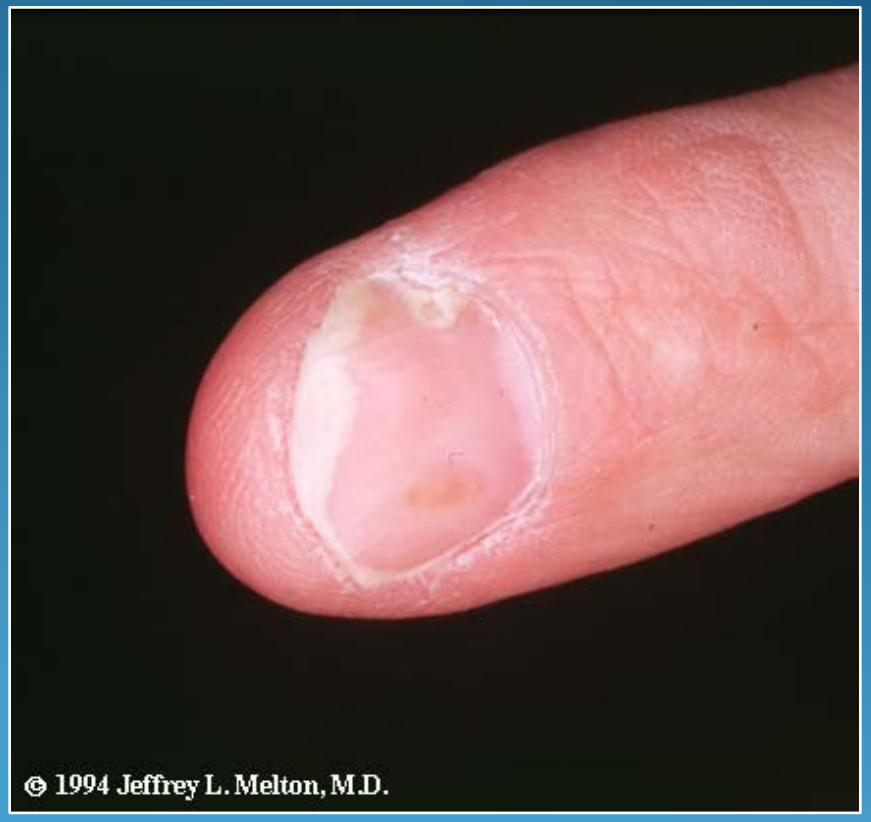

Psoriasis

- Clinical:
  - Variants
    - Guttate
    - Erythrodermic
    - Pustular:
      - Palmoplantar
      - Localized
      - Generalized (Von Zombusch)

Psoriasis: variants

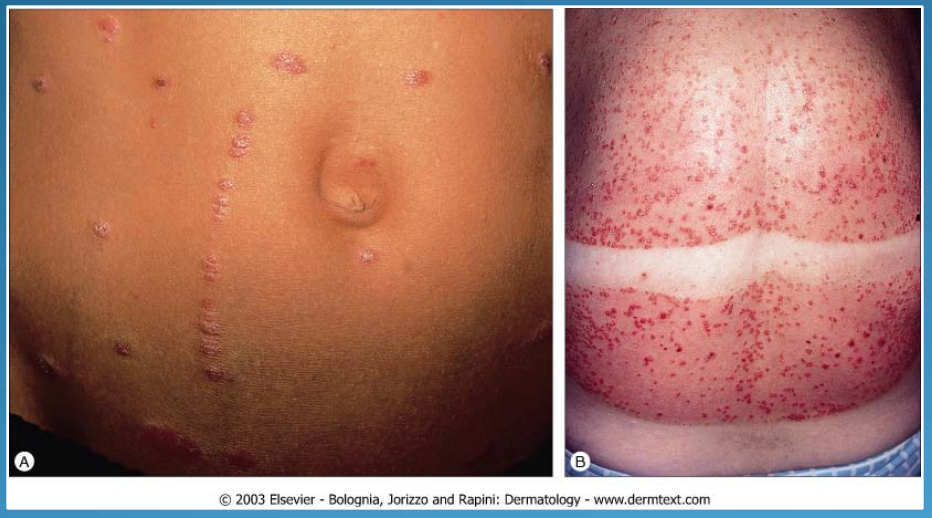

Guttate psoriasis

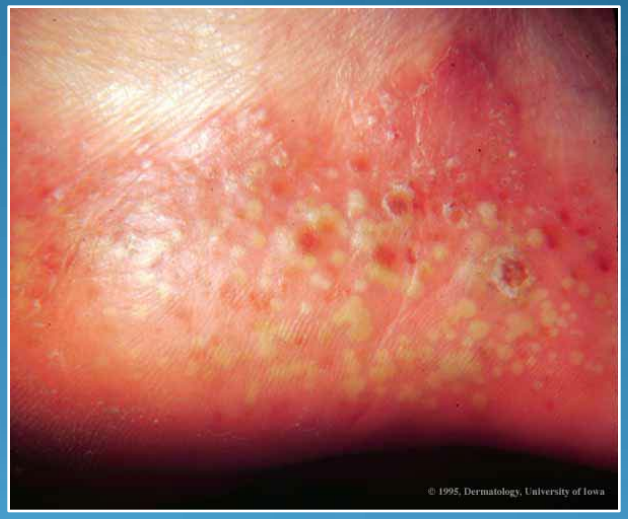

Pustular psoriasis

Psoriasis

- Treatments: cell turnover, inflammation
  - Topical:
    - Steroids
    - Tar
    - Vitamin D
    - Retinoids
    - UV light: UVB, excimer laser

Psoriasis

- Treatments:
  - Systemic:
    - Methotrexate
    - Acitretin
    - Cyclosporine
    - PUVA
    - Biologics

Psoriasis

- Complications
  - Acute exacerbations: DRUGS, infection
  - Staph aureus colonization
  - Arthritis: 5-10%
    - 1) asymmetric monarthritis
    - 2) DIP joint disease
    - 3) RA-like: DIPs and MCPs
    - 4) ankylosing spondylitis: sacroilitis, HLA-B27
    - 5) arthritis mutilans: osteolysis of the digits

Psoriatic arthritis

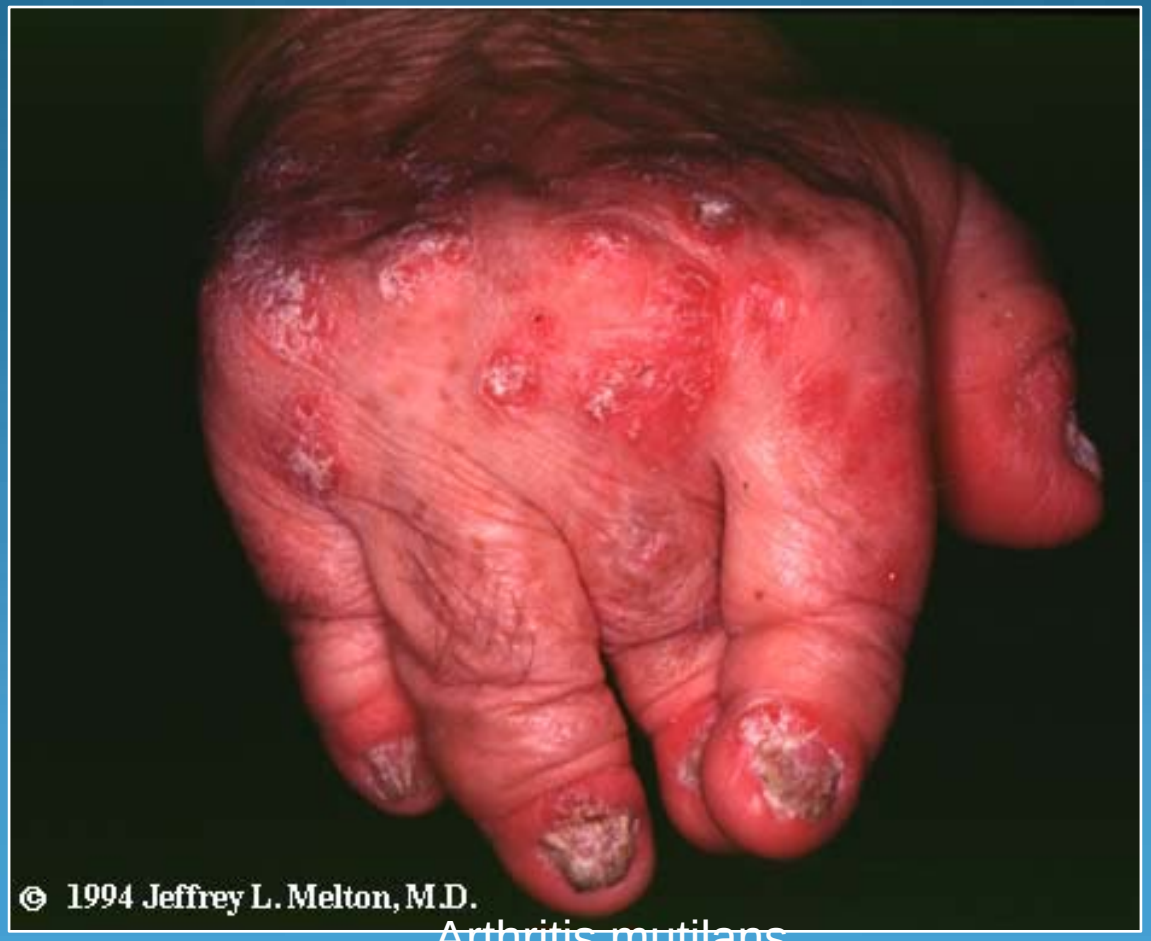

Arthritis mutilans

Psoriasis

- What is Koebner's phenomenon?
- What is Auspitz sign?
- What is the mechanism of methotrexate?
- Name two drugs that may exacerbate a psoriasis flare?

Tinea

- Pathogenesis: superficial skin infection with dermatophyte organism
  - Microsporum
  - Epidermophyton
  - Trichophyton
- Epidemiology: very common! Sources include other humans, animals, and plant matter

Tinea

- Diagnosis: clinical and KOH
- Differential diagnosis: depends on location
  - Tinea capitis: SebDerm, alopecia areata, discoid lupus, folliculitis
  - Tinea cruris: SebDerm, candida
  - Tinea corporis: nummular eczema, psoriasis, lupus
  - Tinea pedis: ezcema, psoriasis, bacterial infn
  - ETC….

Tinea: corporis

- Pathogenesis:
  - T. rubrum
  - T. mentagrophytes
  - M. canis
- Clinical:
  - Annular, scaly patch
  - Single or multiple or polycyclic
  - Leading scale

Tinea: corporis

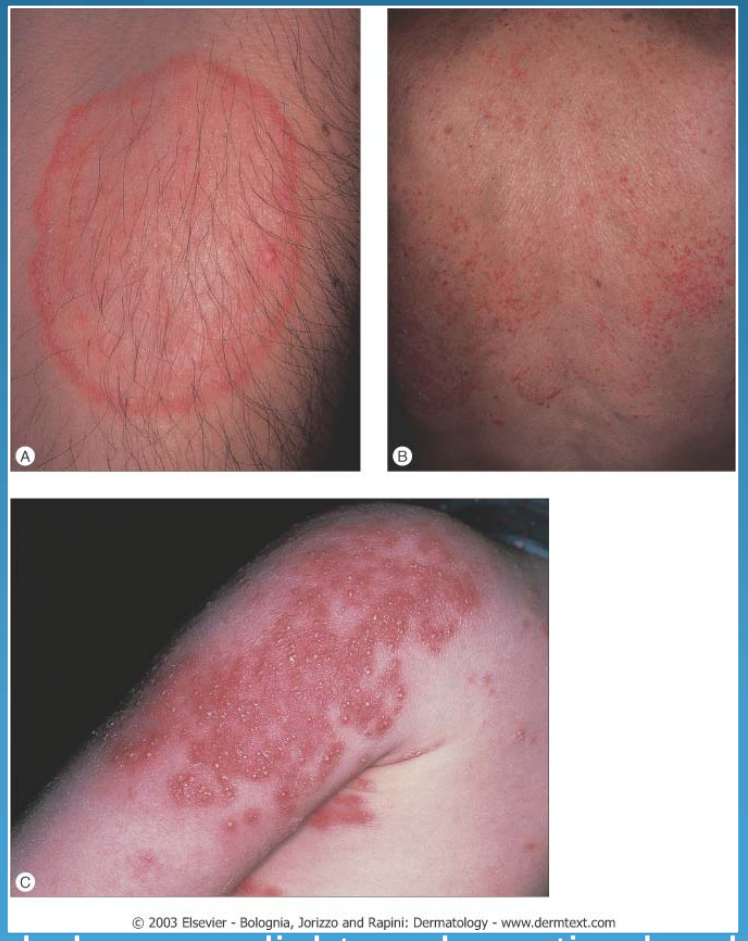

Red plaques, slight scale, active border

Tinea: corporis

- Treatment:
  - Topical antifungal, BID for 2-4 weeks
  - Rarely need oral therapy

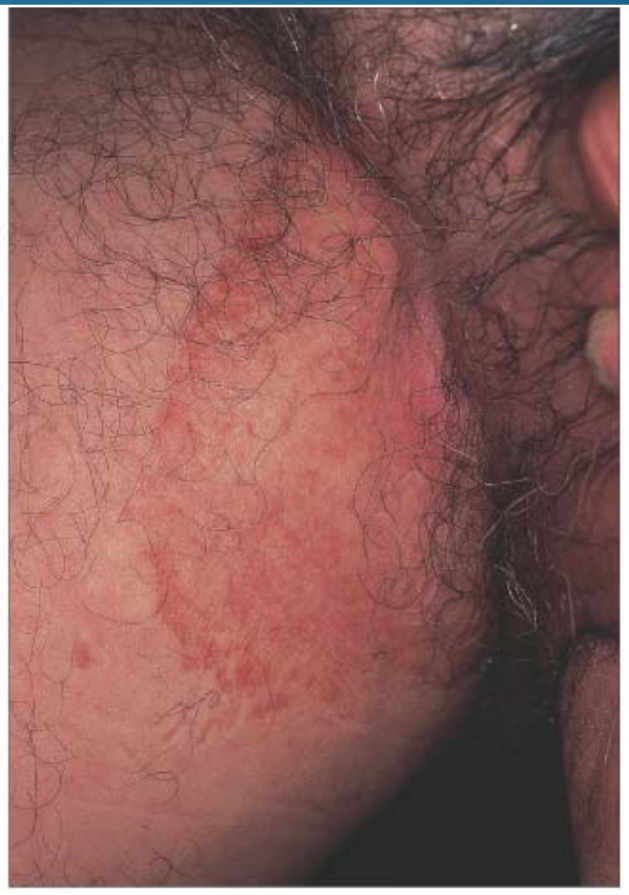

Tinea: capitis

- Pathogenesis:
  - T. tonsurans
  - M. canis
  - M. andouinni
- Clinical:
  - Seborrheic
  - Black dot
  - Kerion

Tinea: capitis

Tinea capitis: broken hairs

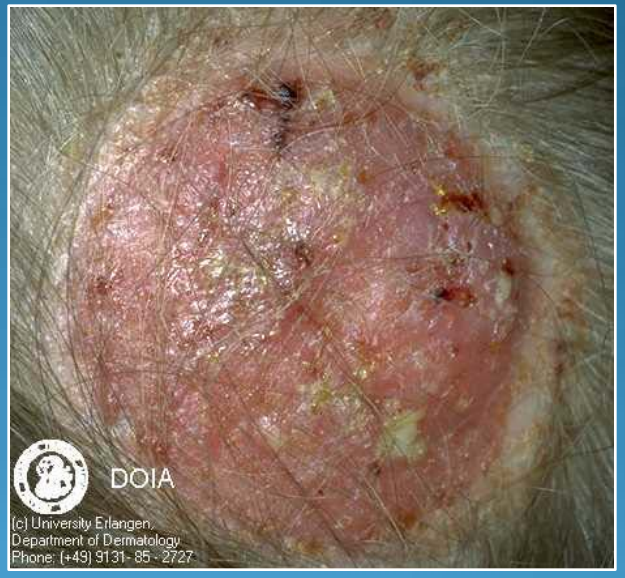

Kerion

Tinea: capitis

- Treatment:
  - Oral therapy indicated. Usually require 6-12 weeks.
  - Choice depends on organism
    - KOH: endothrix, ectothrix, favus
    - Wood's lamp: green flourescence
    - Culture

Tinea

- What is the most common cause of tinea capitis in the United States?
- What dermatophyte causes “tinea” versicolor?
- Your wood’s lamp exam of the scalp flouresces green. What is the most likely organism?
- What would you call a dermatophyte infection of the hands?