Dermatopathology Slide Review Part 33

Paul K. Shitabata, M.D.
Dermatopathology Institute

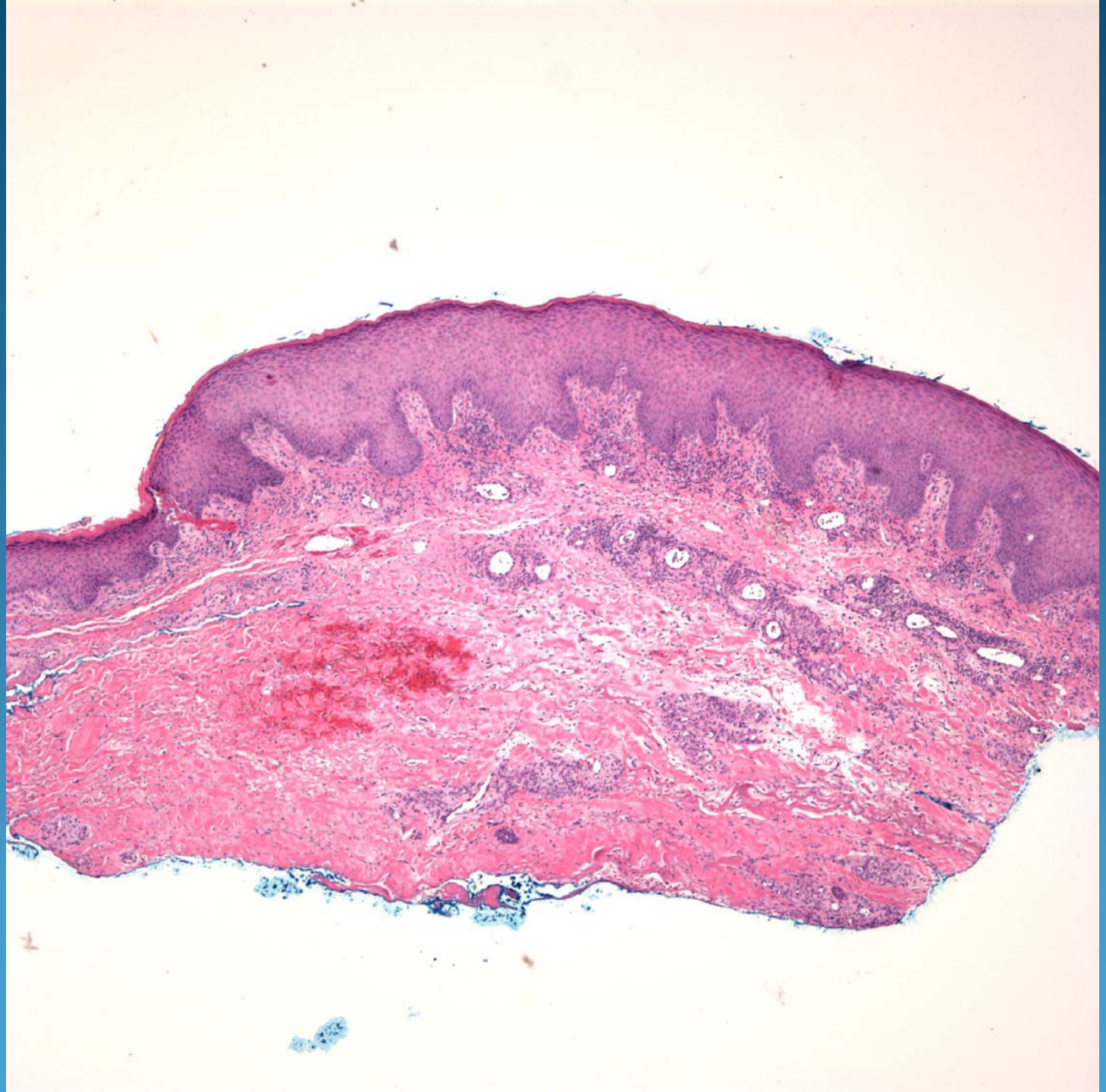

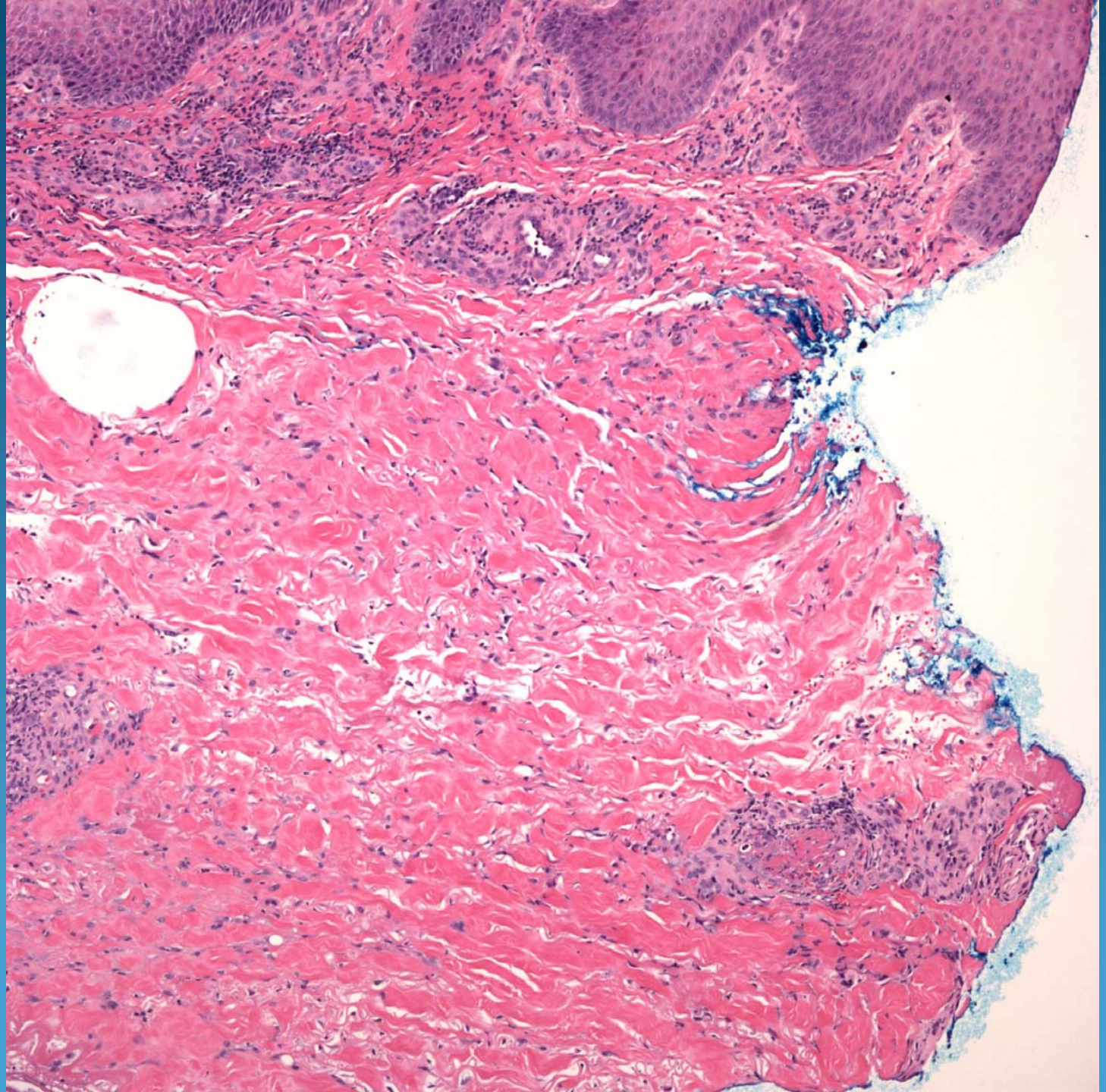

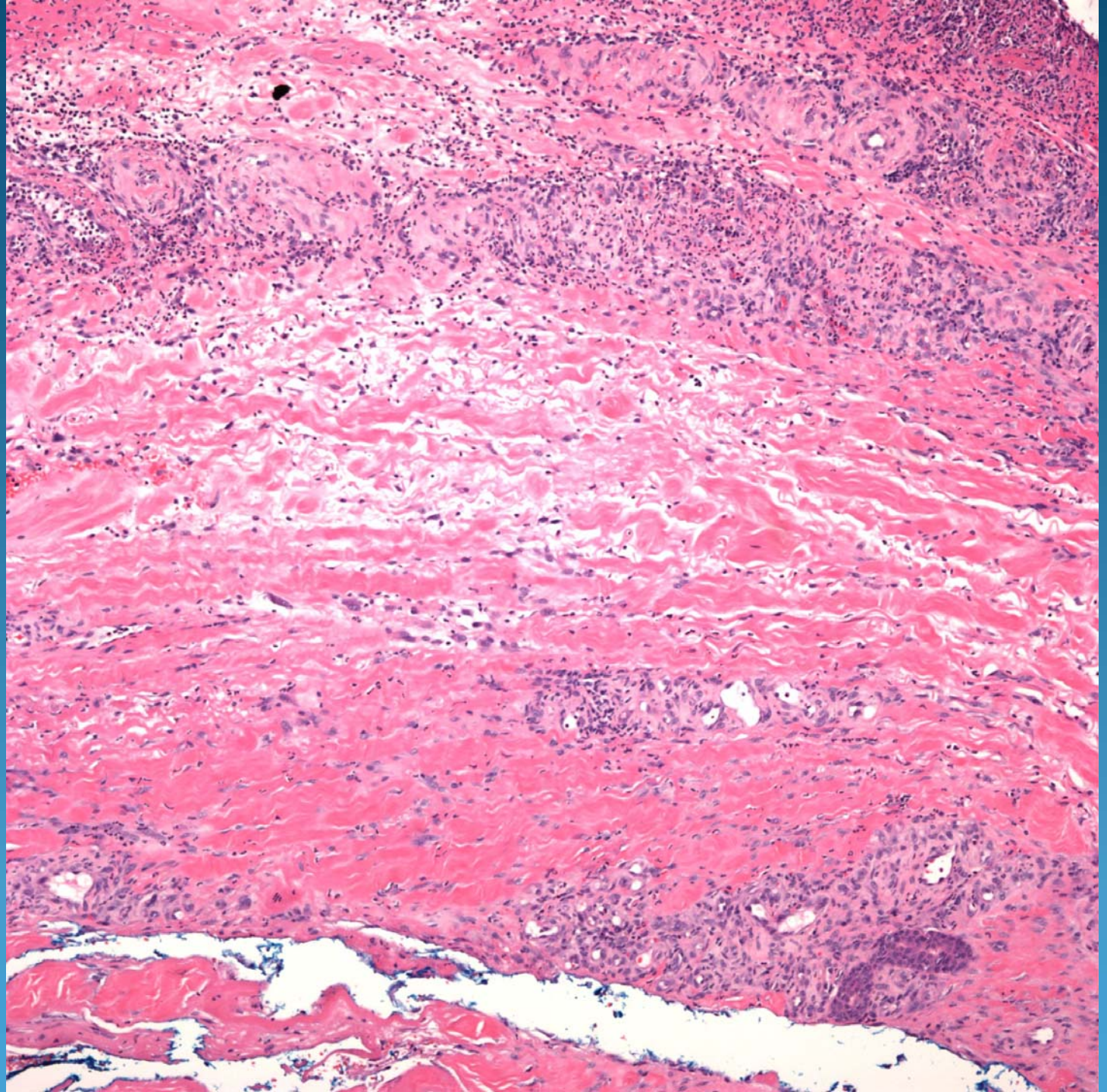

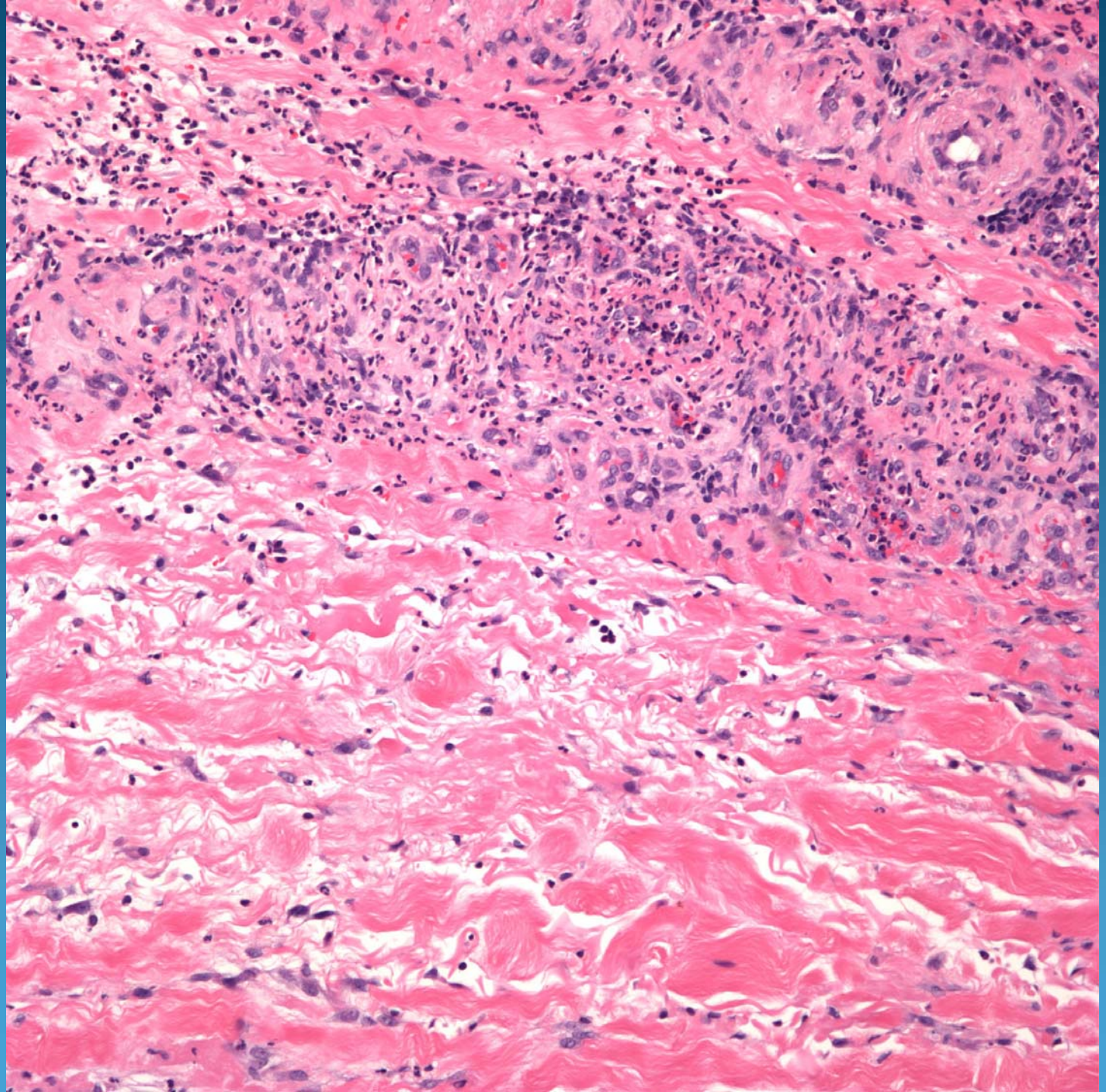

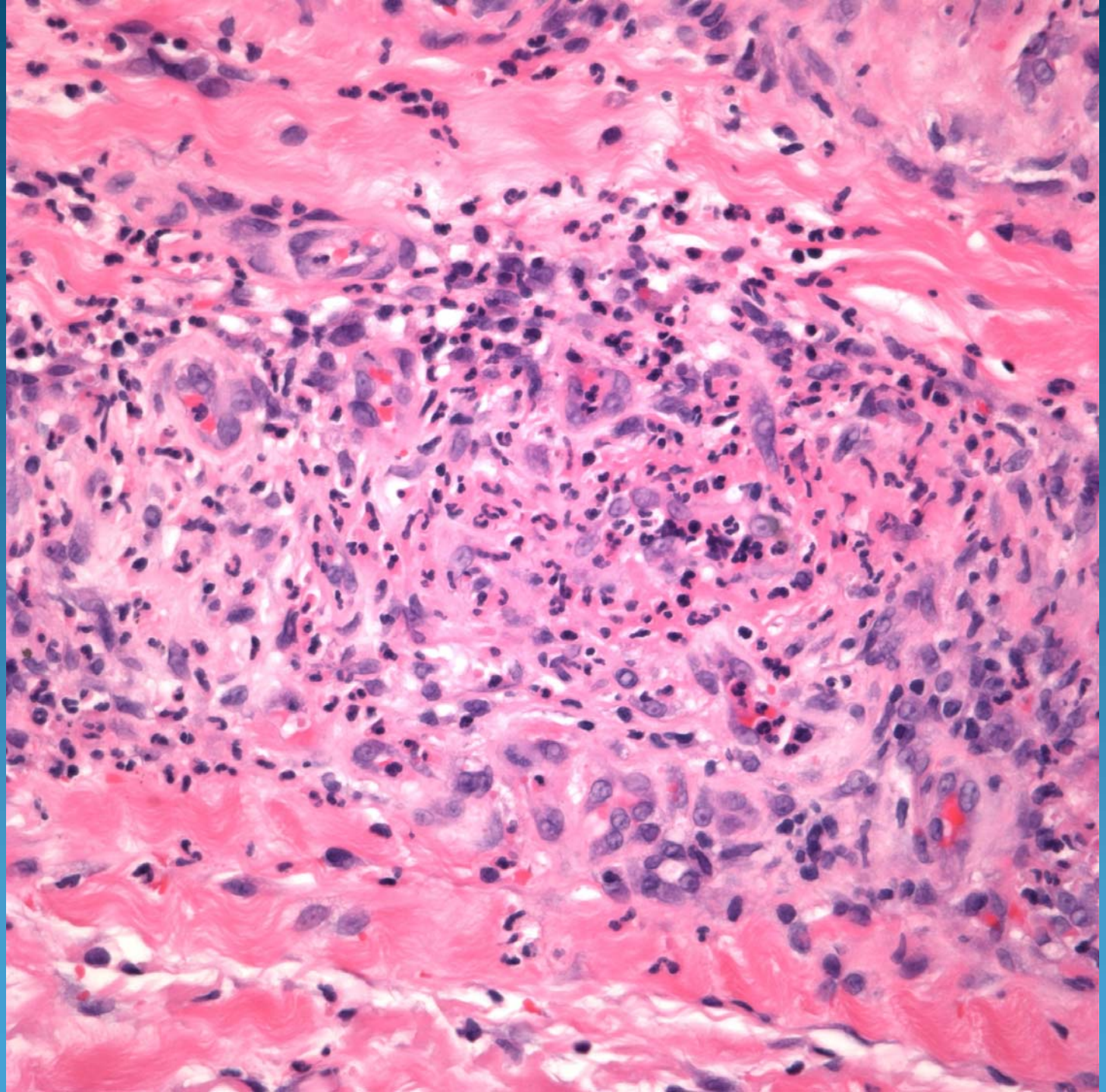

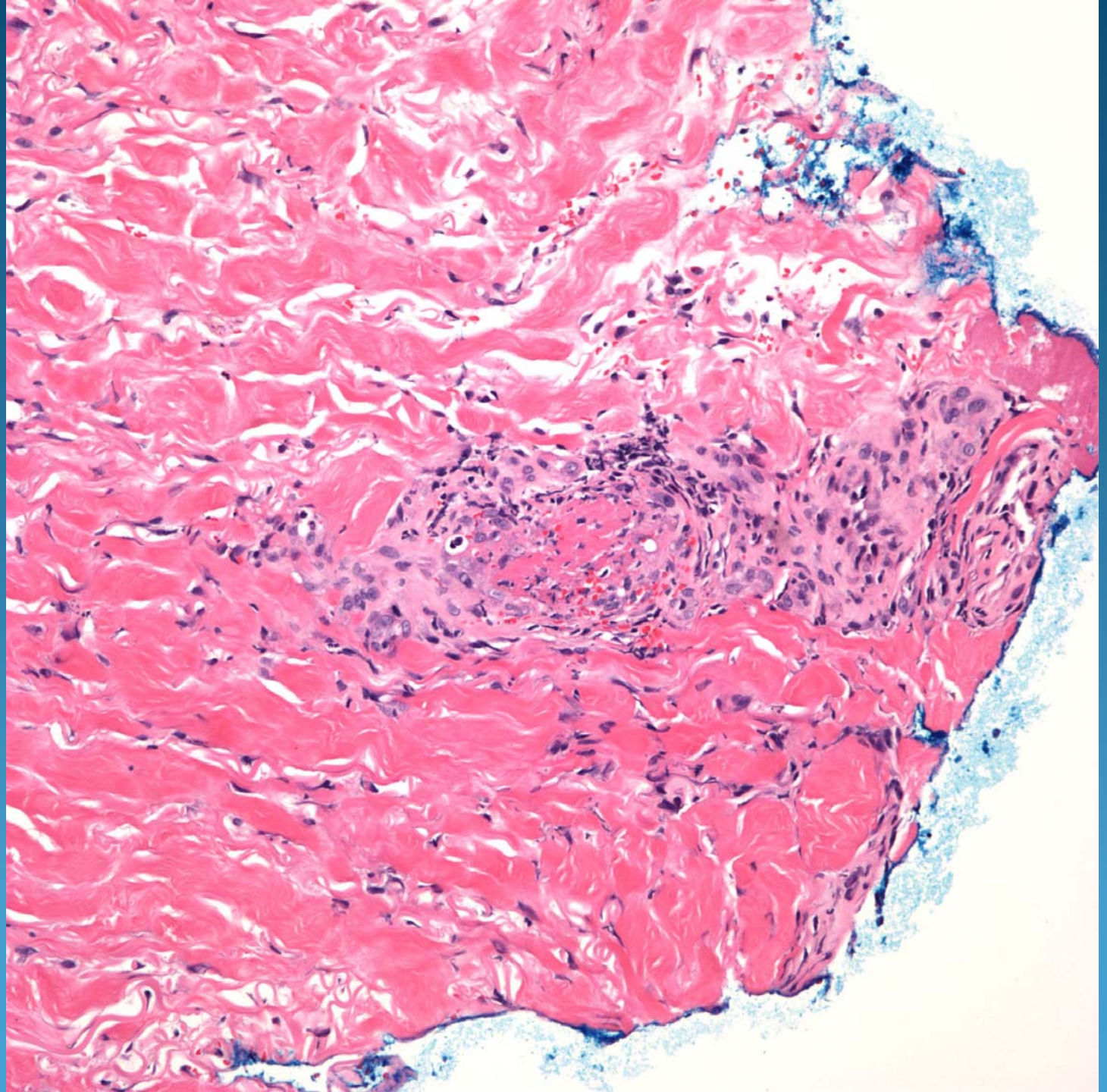

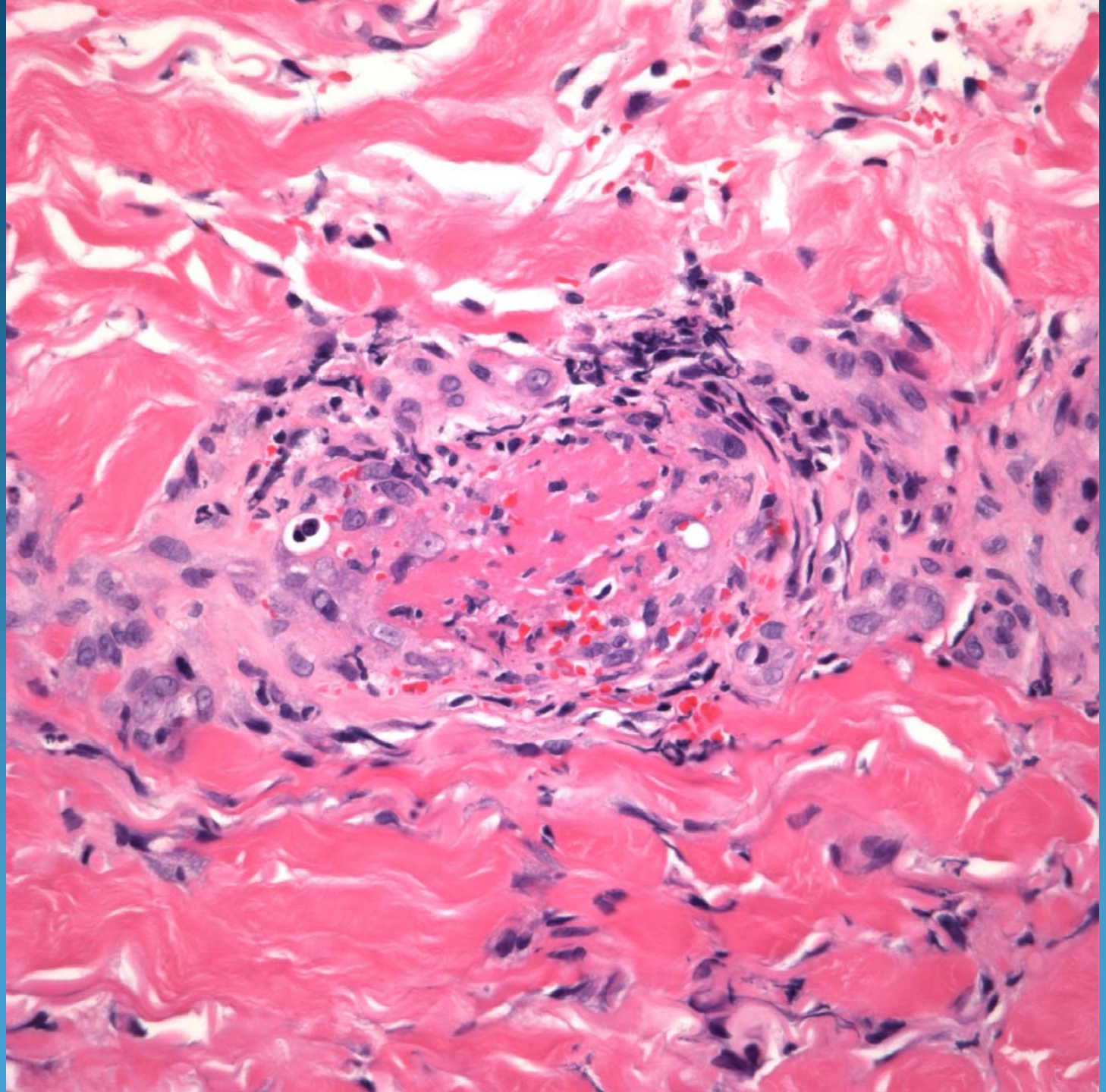

Systemic Lupus Erythematosus with Thrombotic Vasculopathy

Pearls

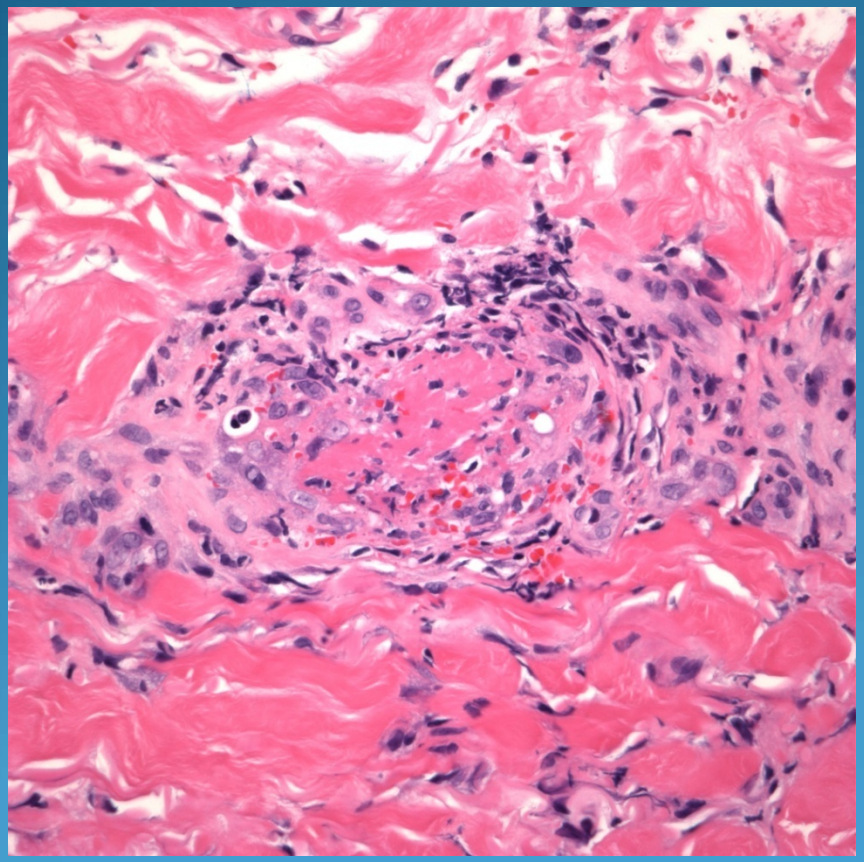

- Look for evidence of a cutaneous infarct with ulceration and extensive necrosis
- Examine vessels away from necrosis and ulcer for evidence of thrombosis
- Coagulation work-up mandatory

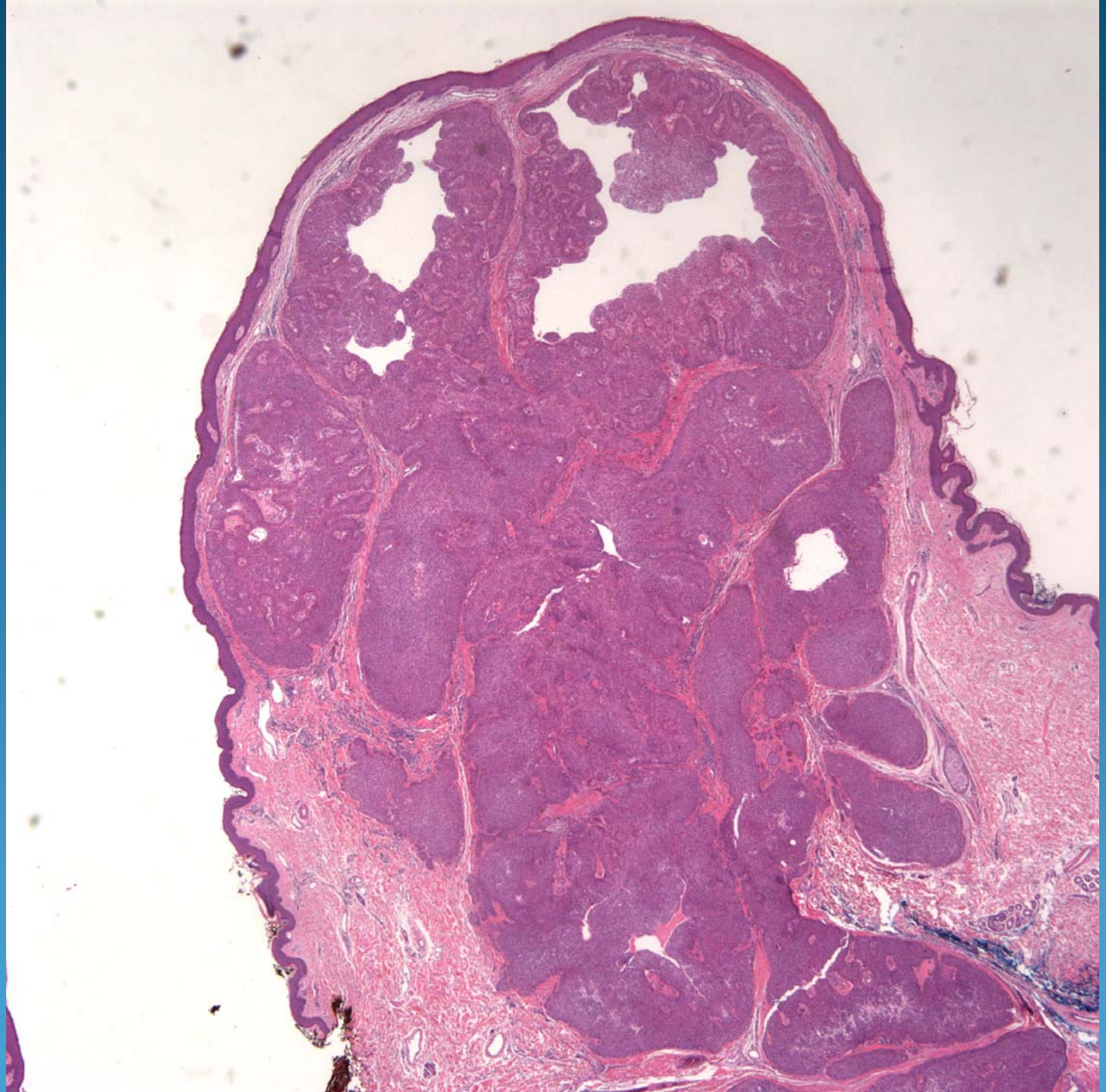

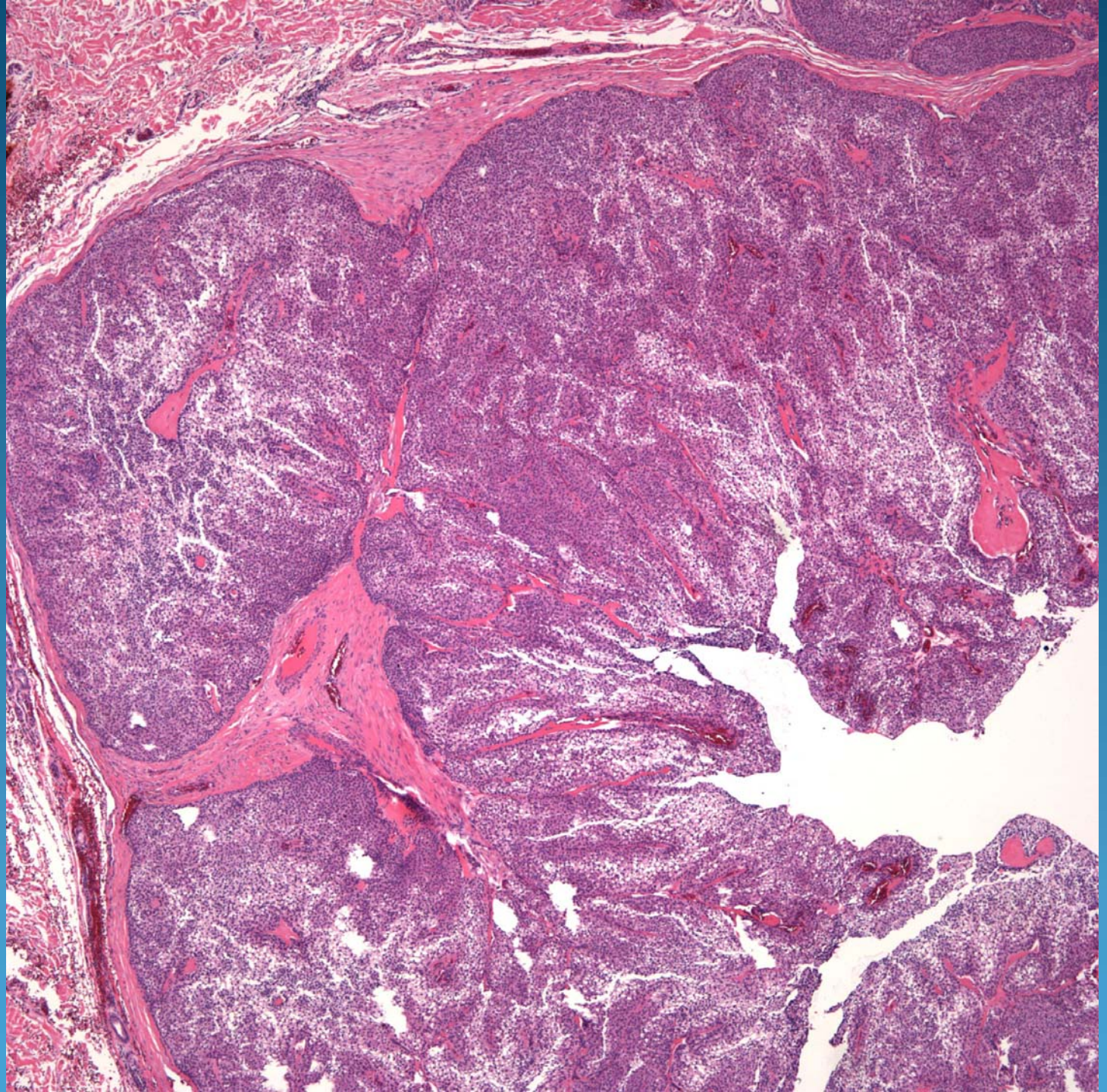

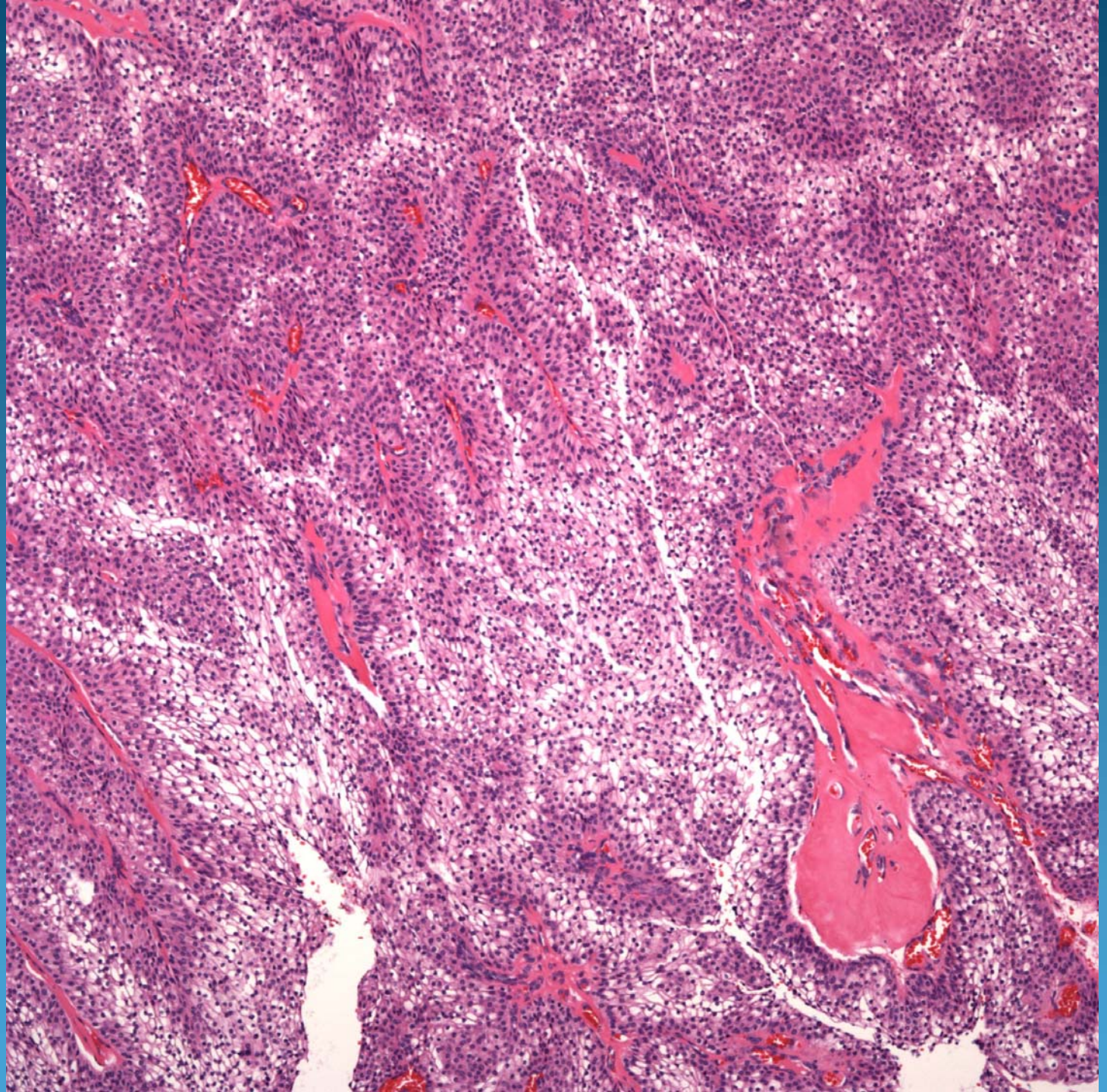

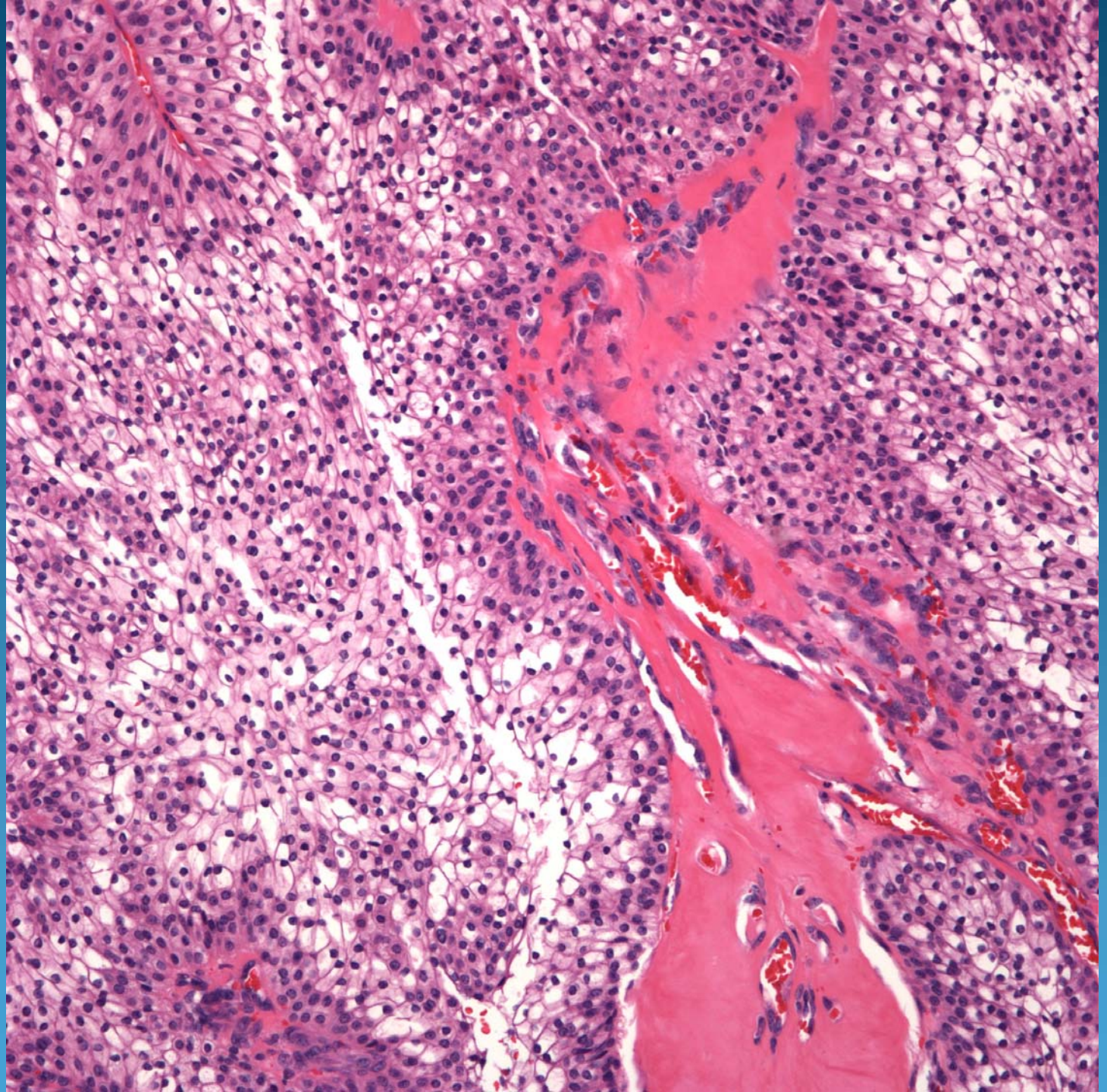

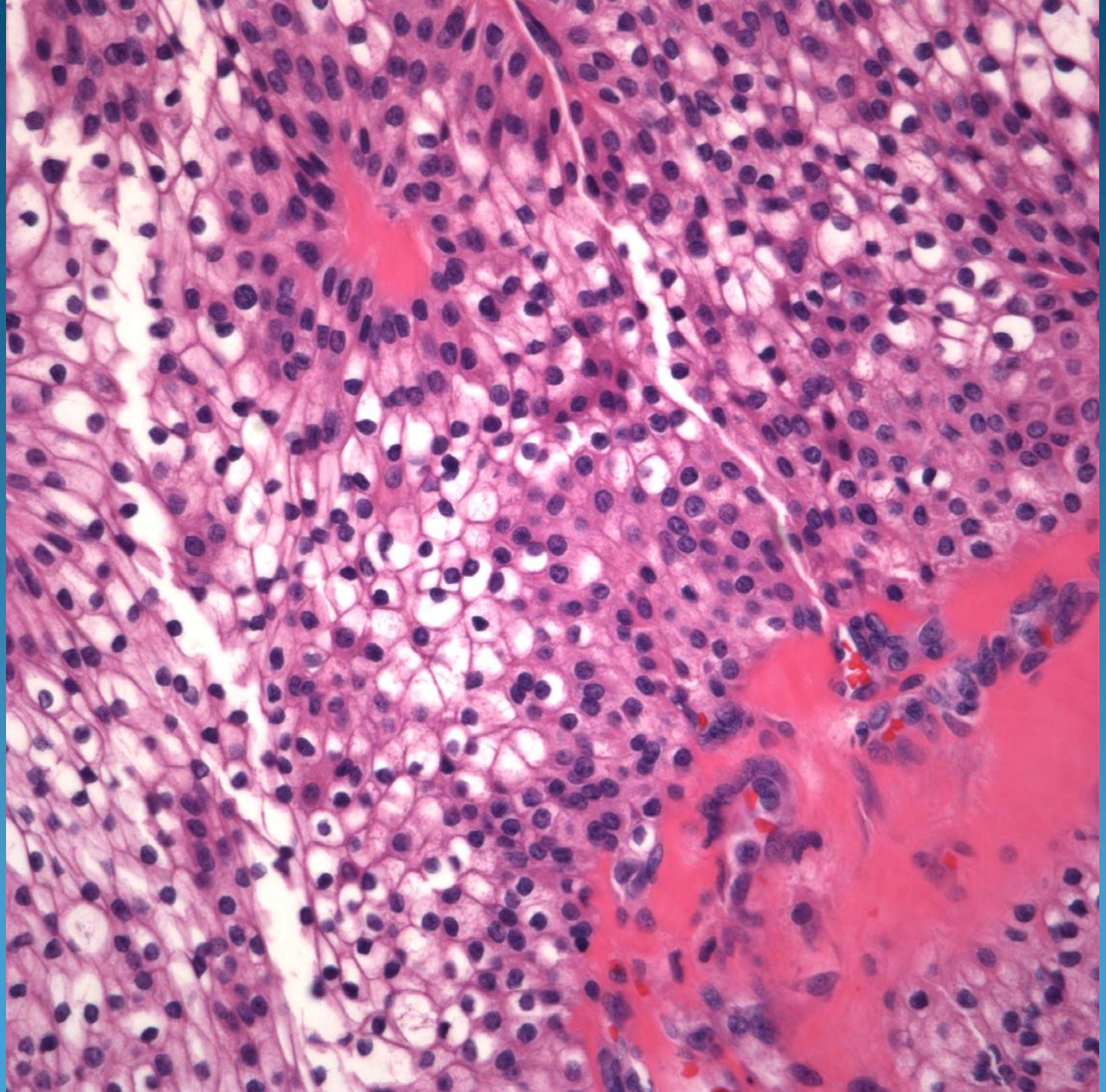

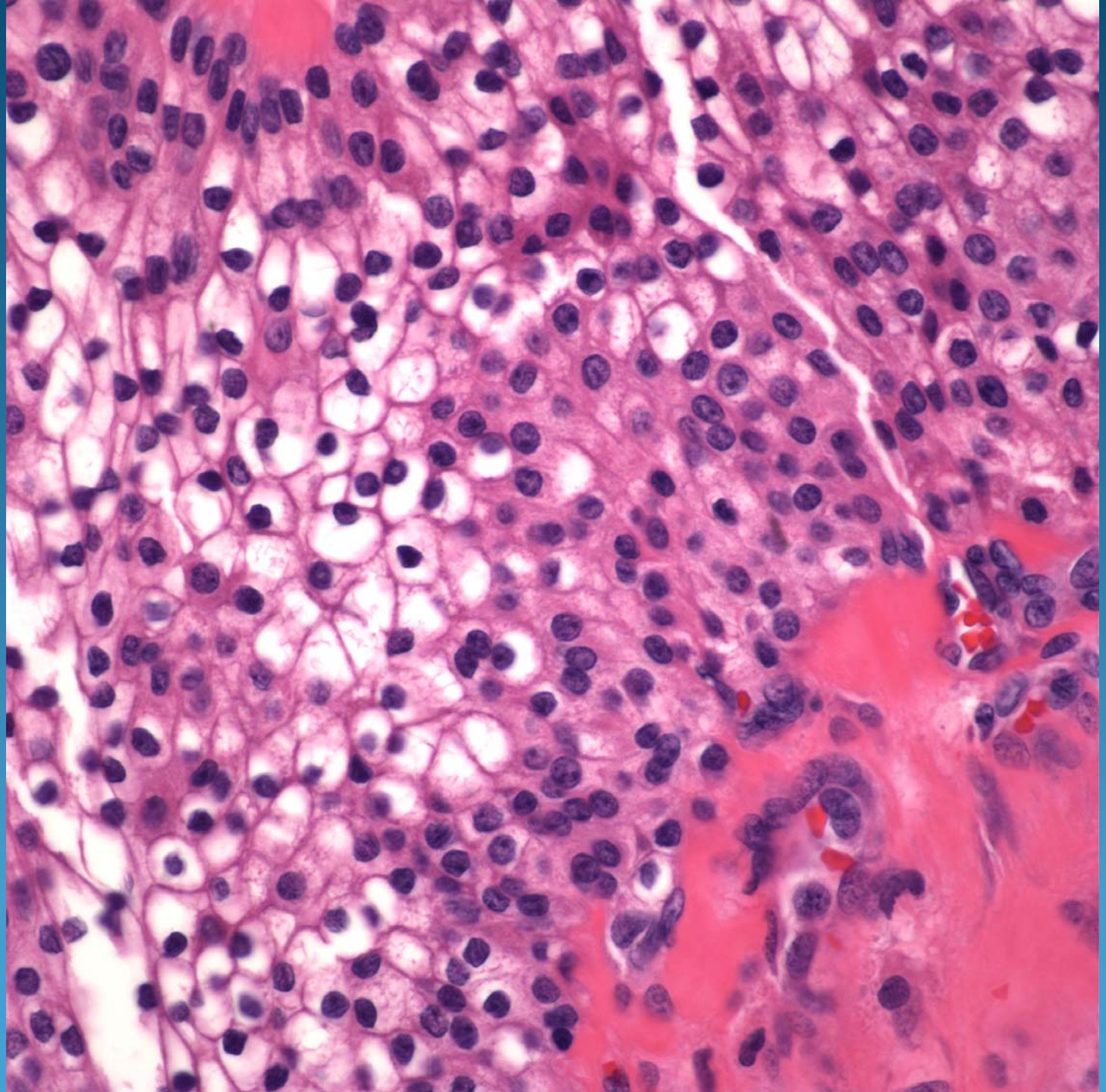

Nodular and Cystic Hidradenoma with Clear Cell Features

Pearls

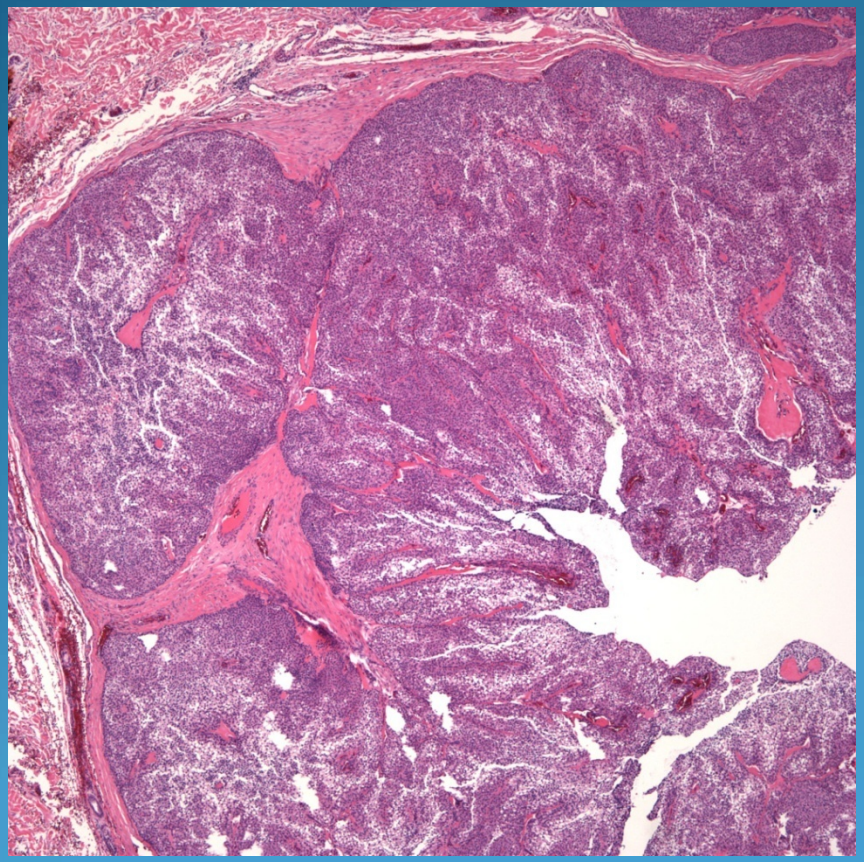

- Circumscribed epithelial tumor which may have epidermal attachment
- Composed of squamous cells with clear cytoplasmic features
- Focal ducts coalescing to form larger cysts
- Hyalinization around vessels
- Rule out metastatic renal cell carcinoma

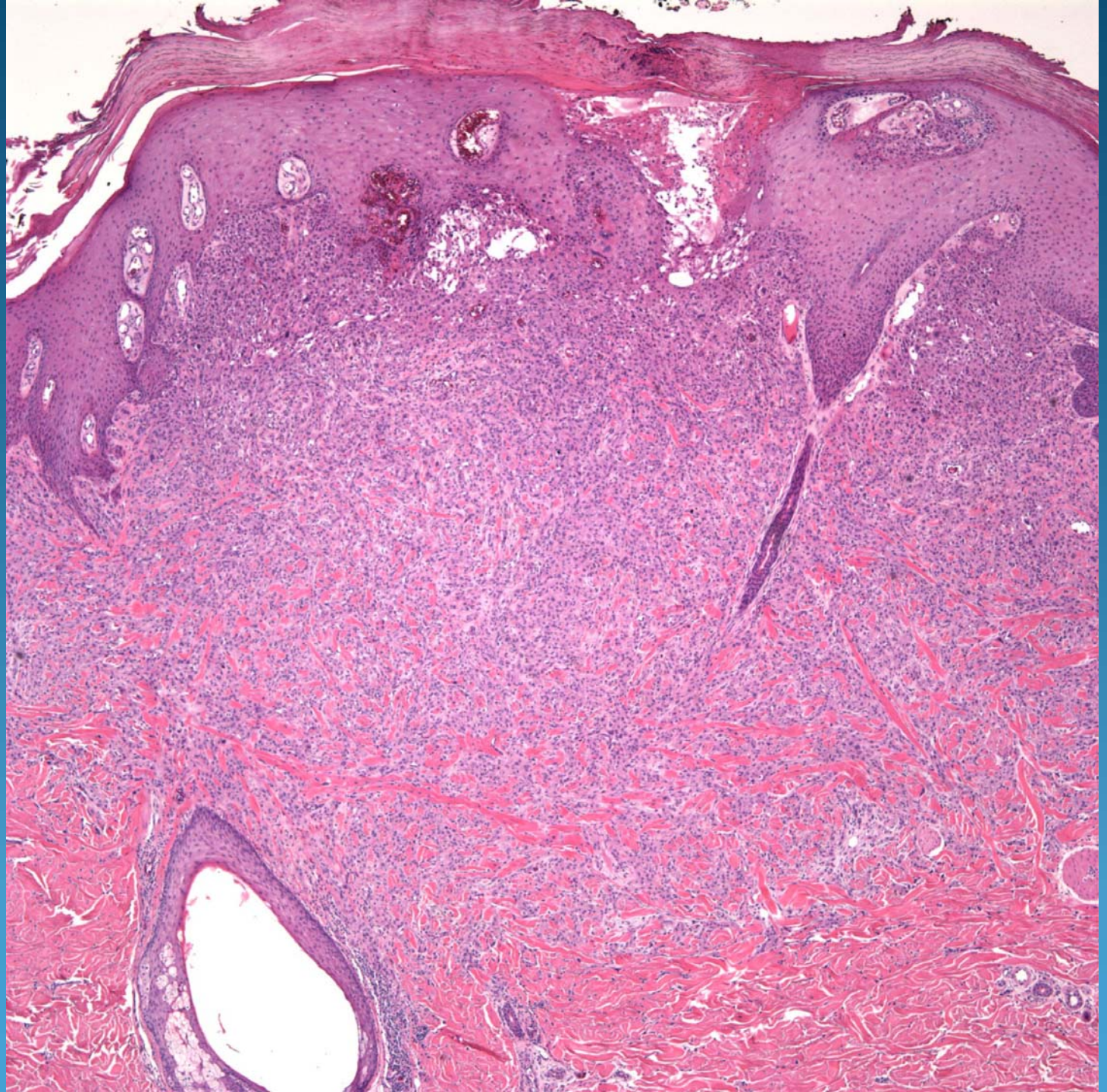

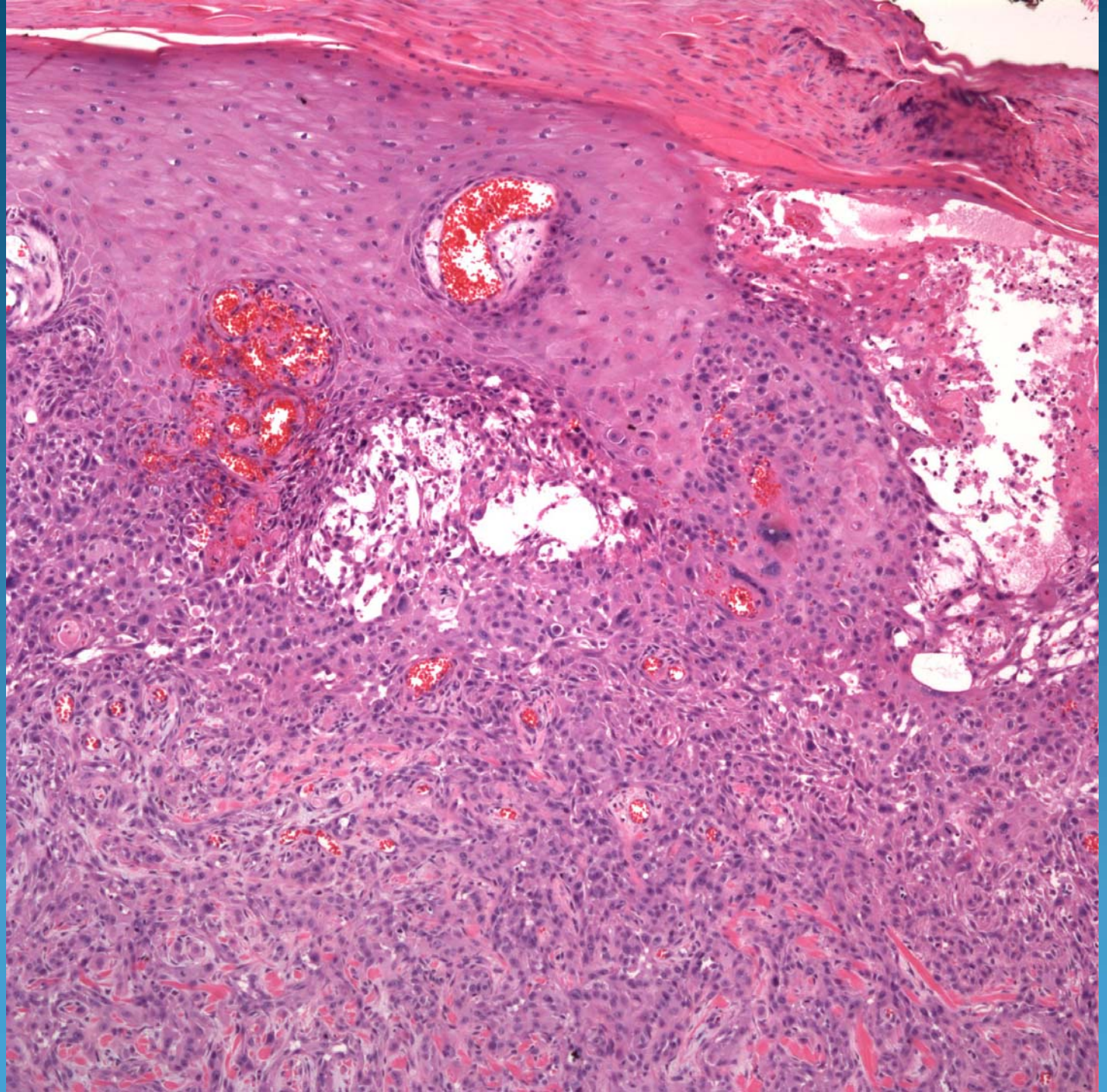

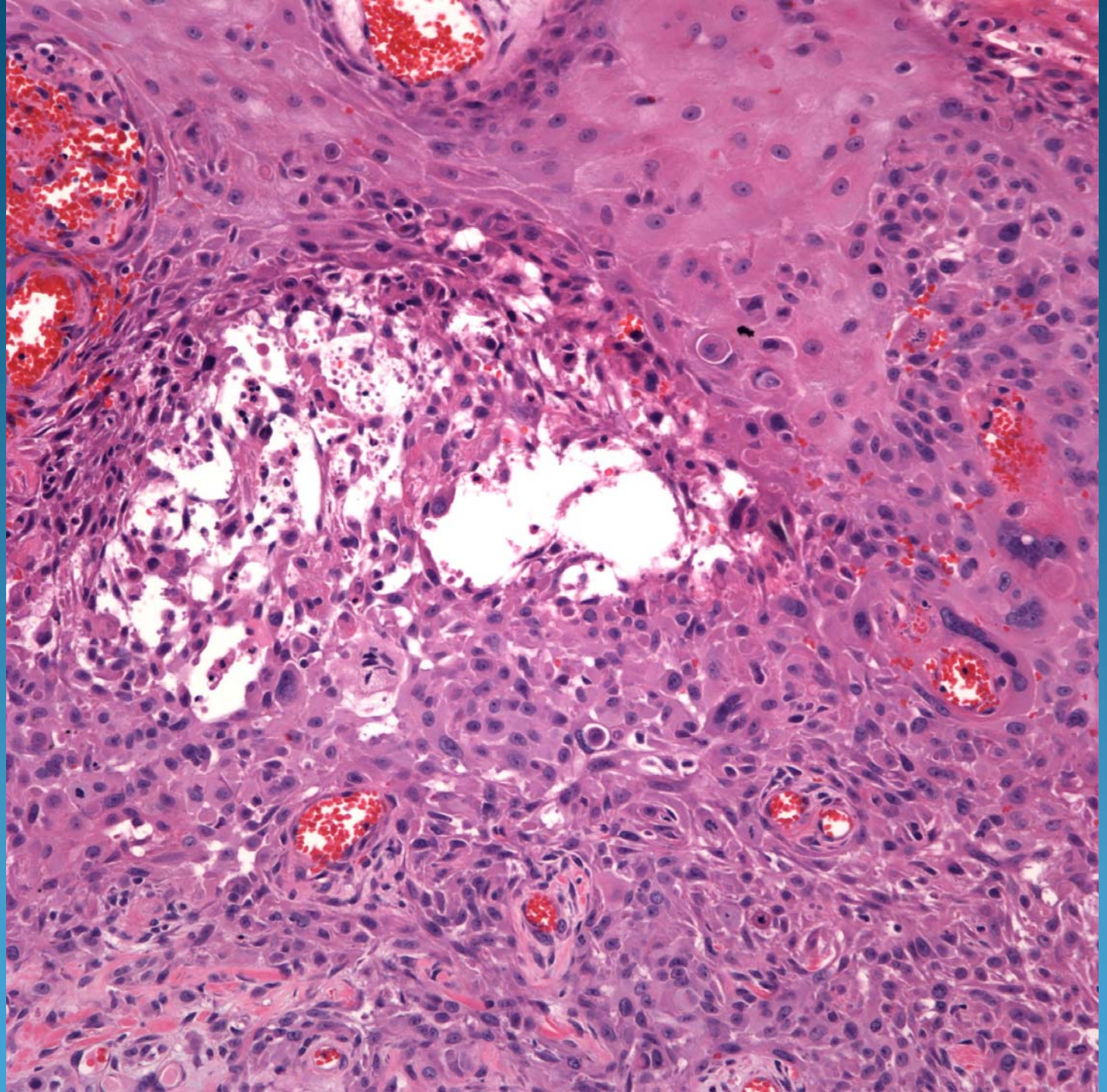

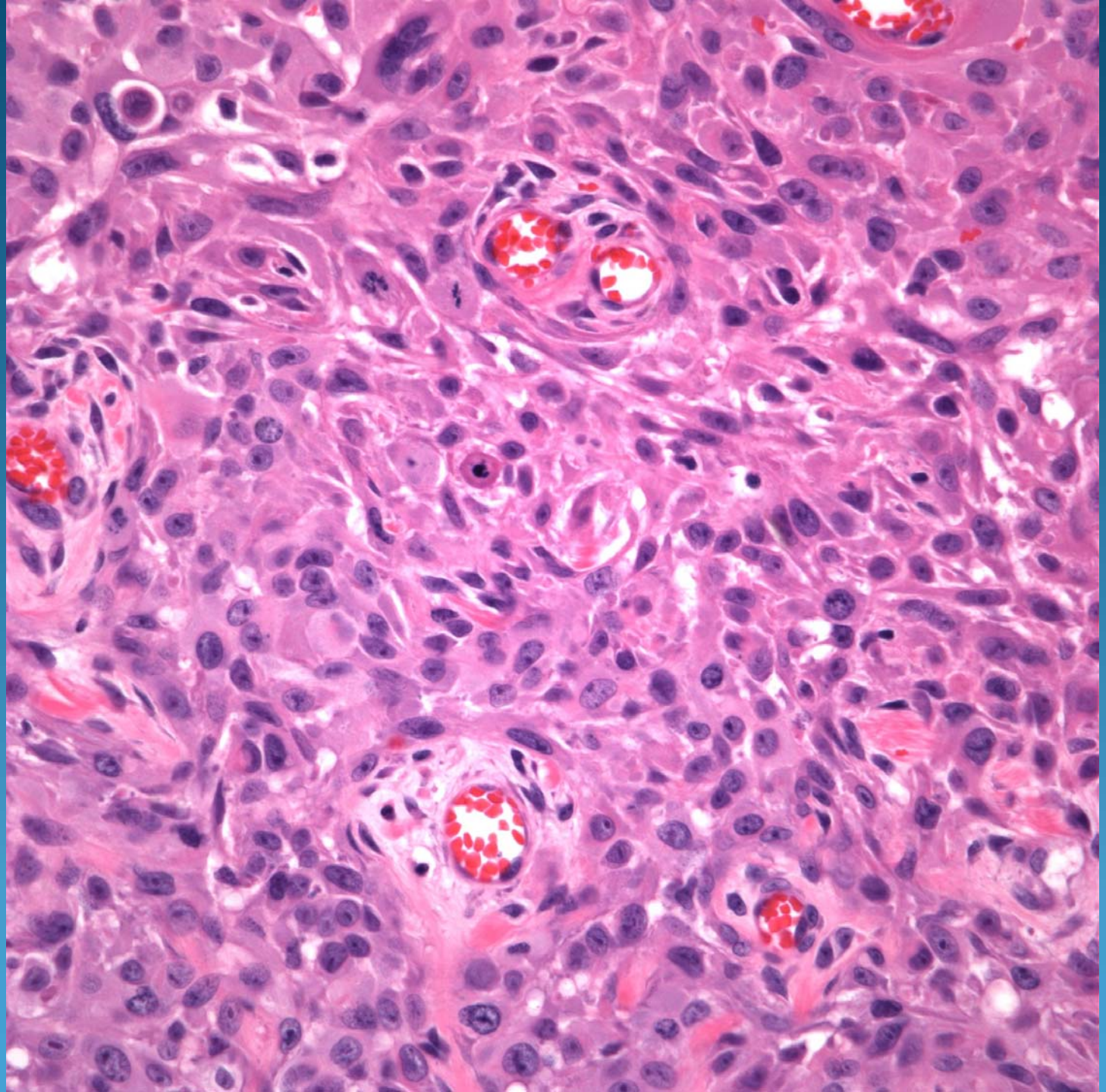

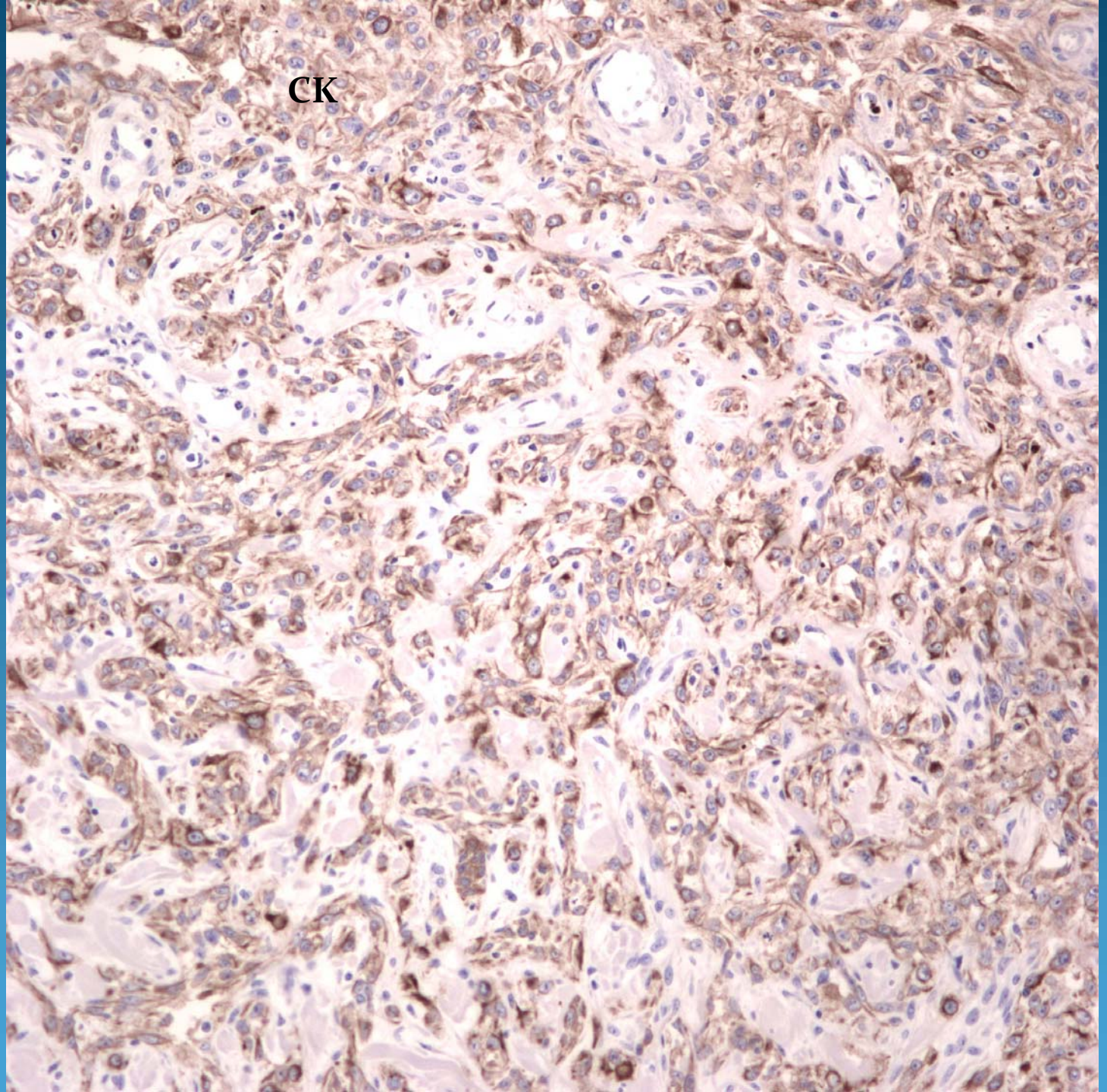
CK

Invasive Squamous Cell Carcinoma, Poorly Differentiated

Pearls

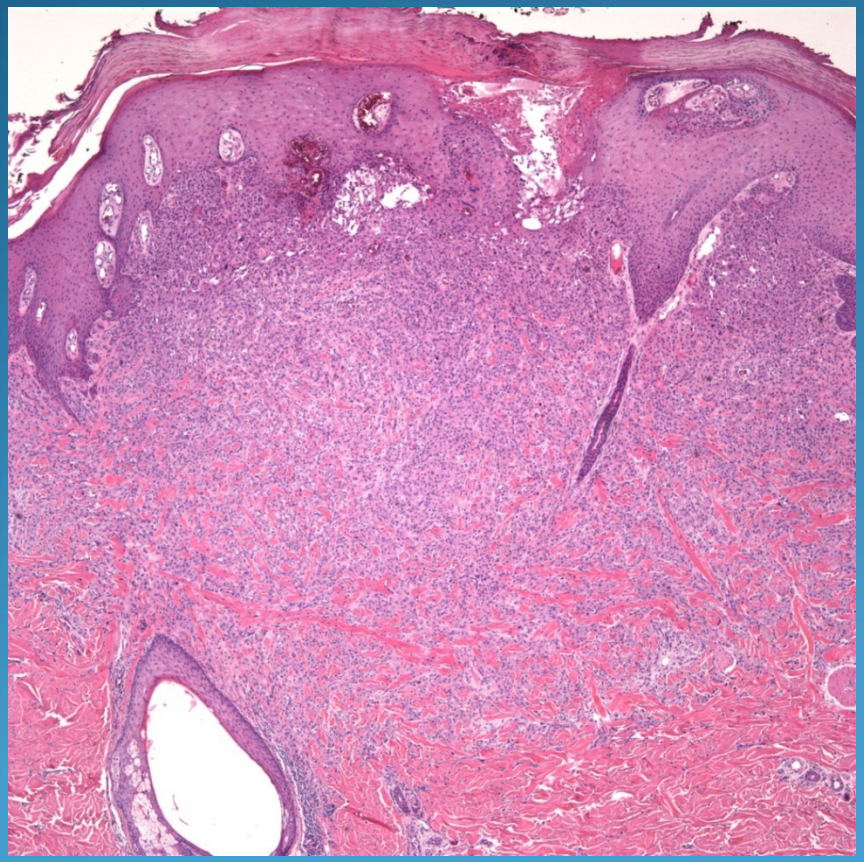

- Diffuse sheets of pleomorphic cells
- Look for epidermal attachment
- May show focal keratinization and intercellular bridges
- May need IHC for CK to confirm

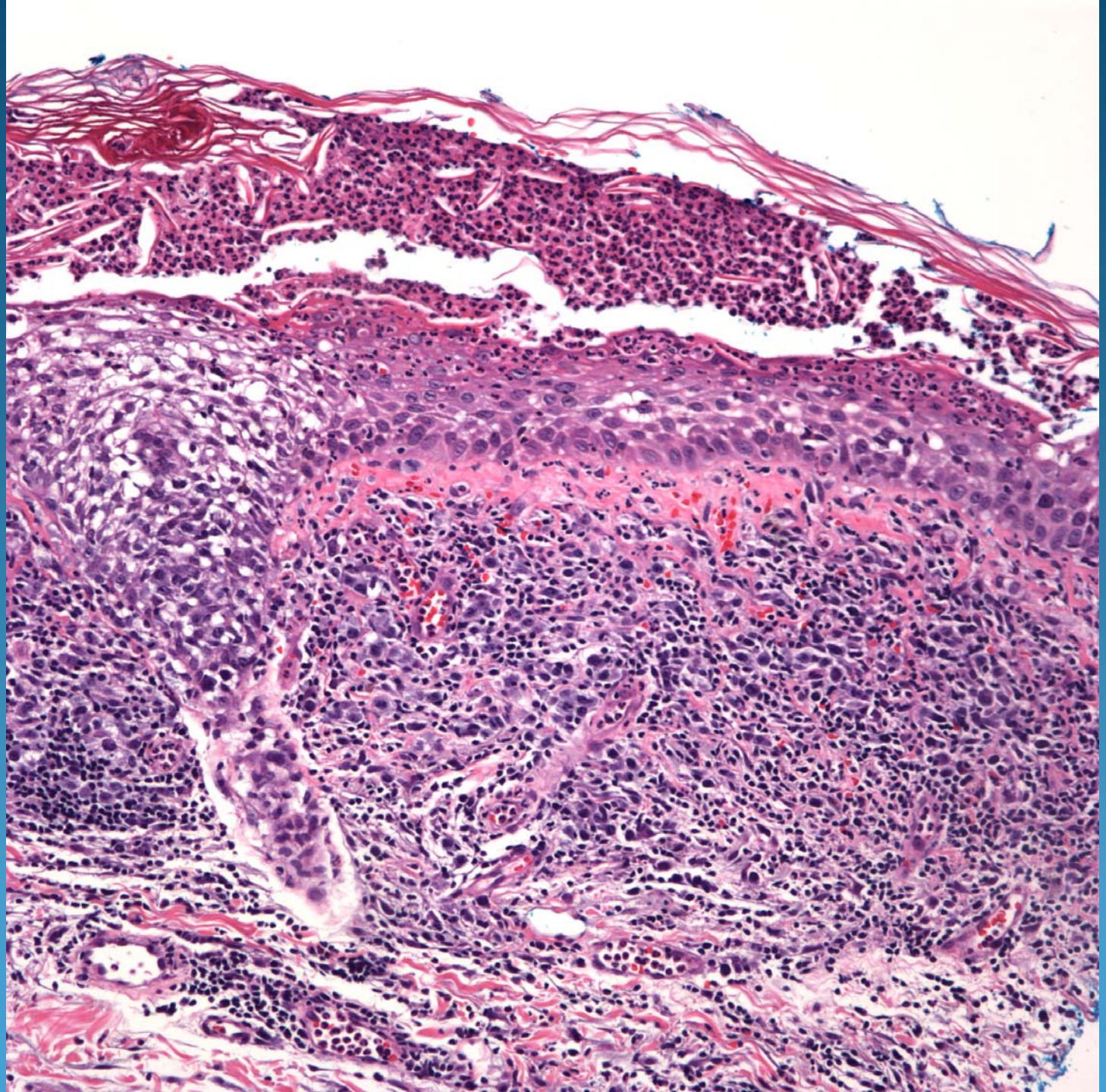

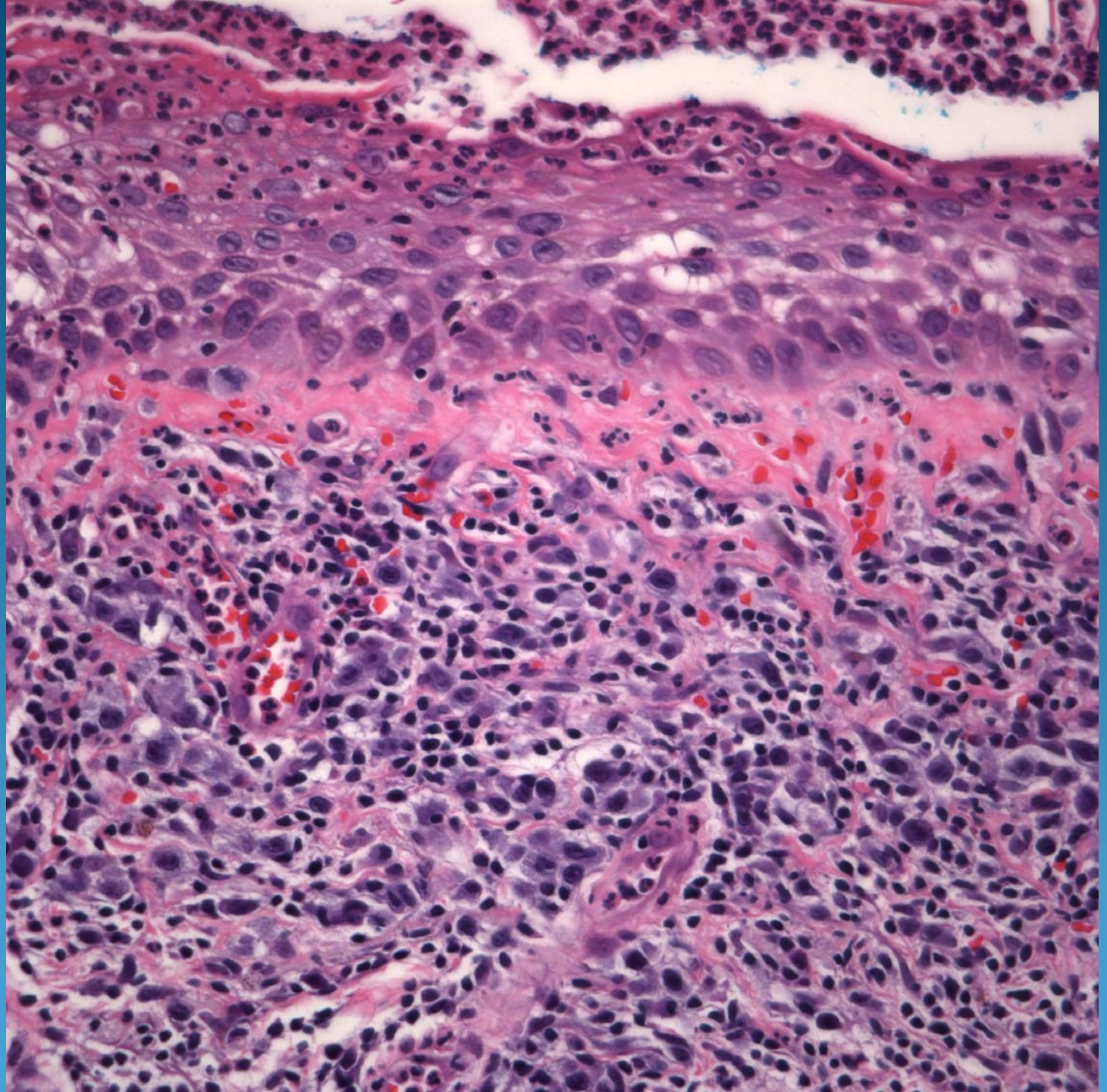

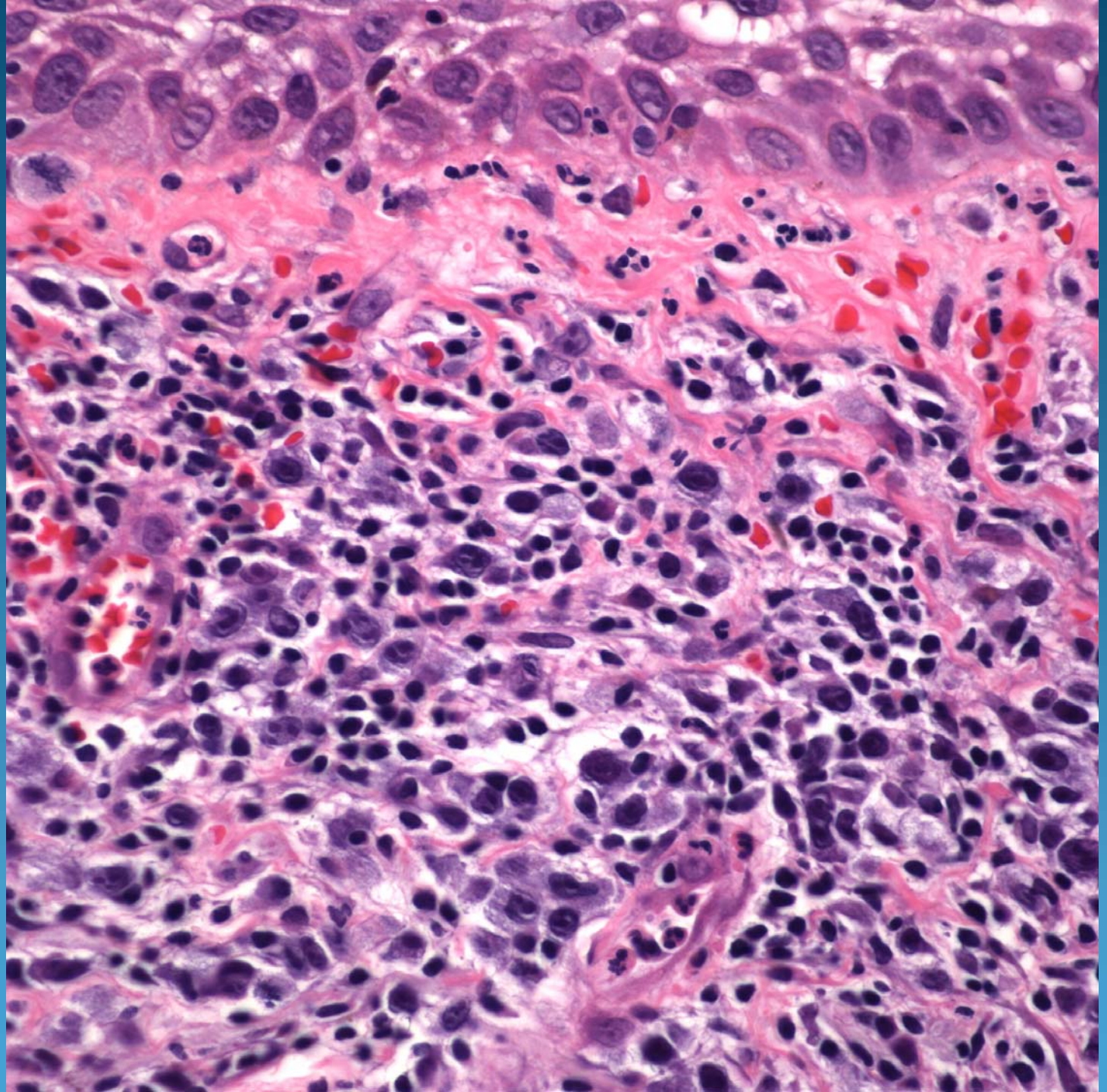

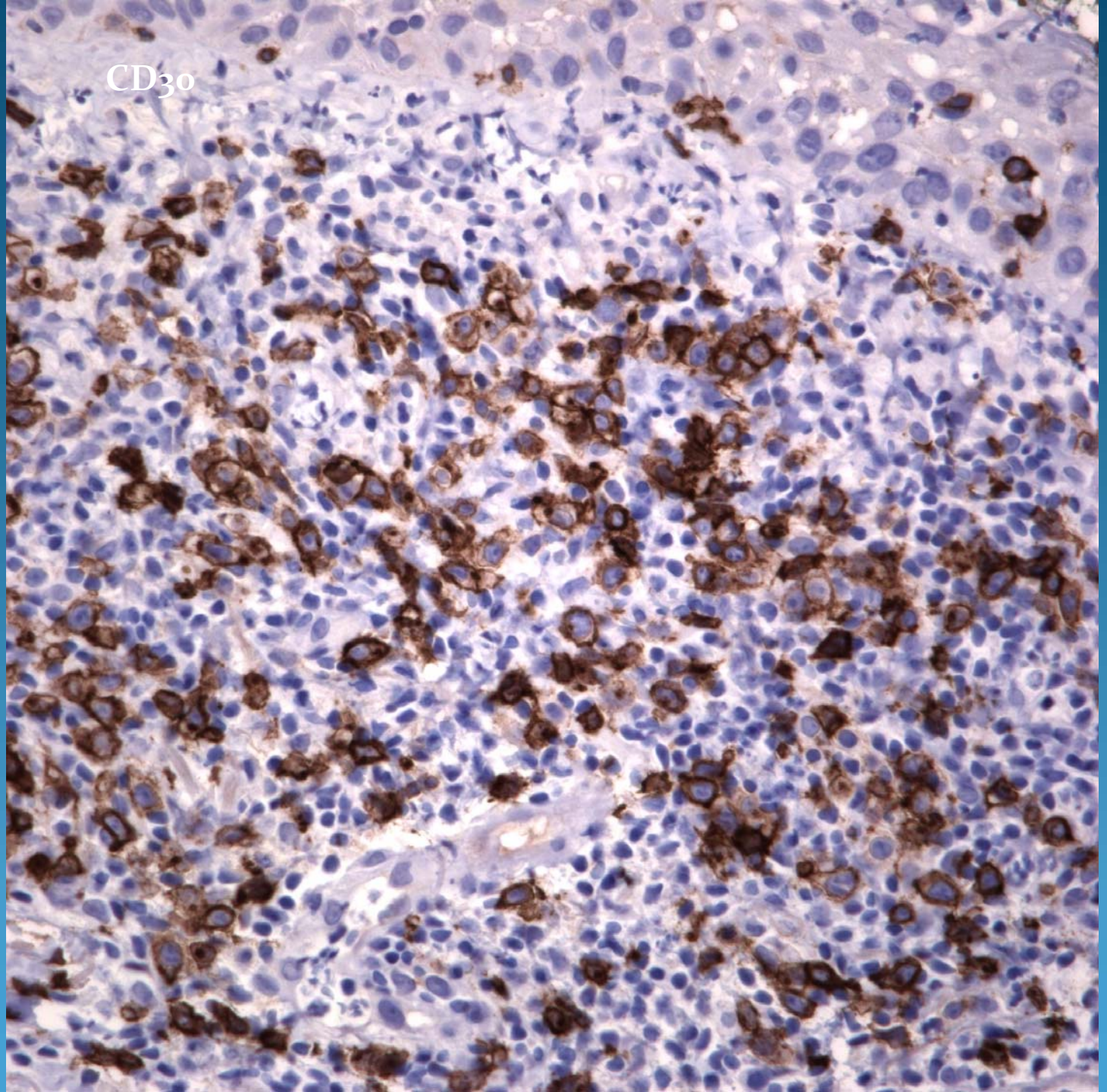
CD30

Lymphomatoid Papulosis

Pearls

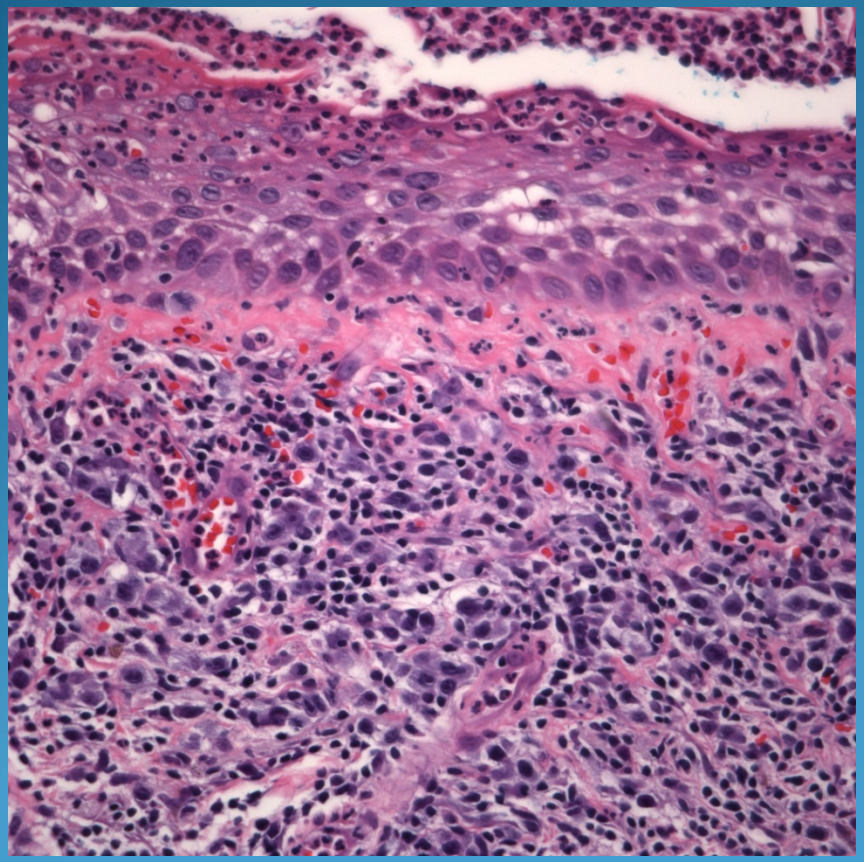

- Mixed inflammatory cell infiltrate interspersed with cytologically atypical cells
- Use IHC (CD30) to confirm
- If diffusely filled with CD30 positive cells, consider Primary Anaplastic Large Cell Lymphoma
- Correlate with clinical history and appearance

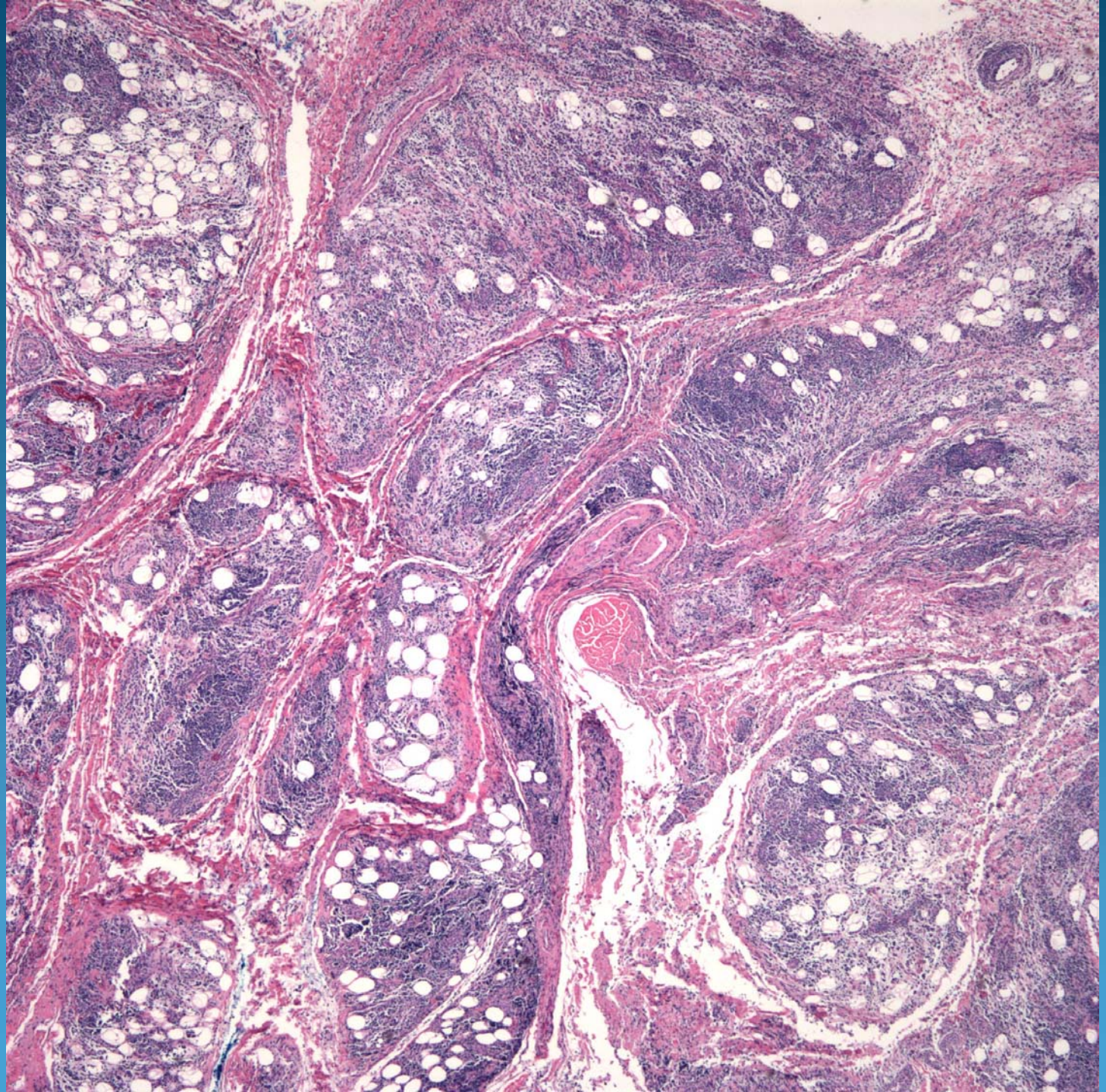

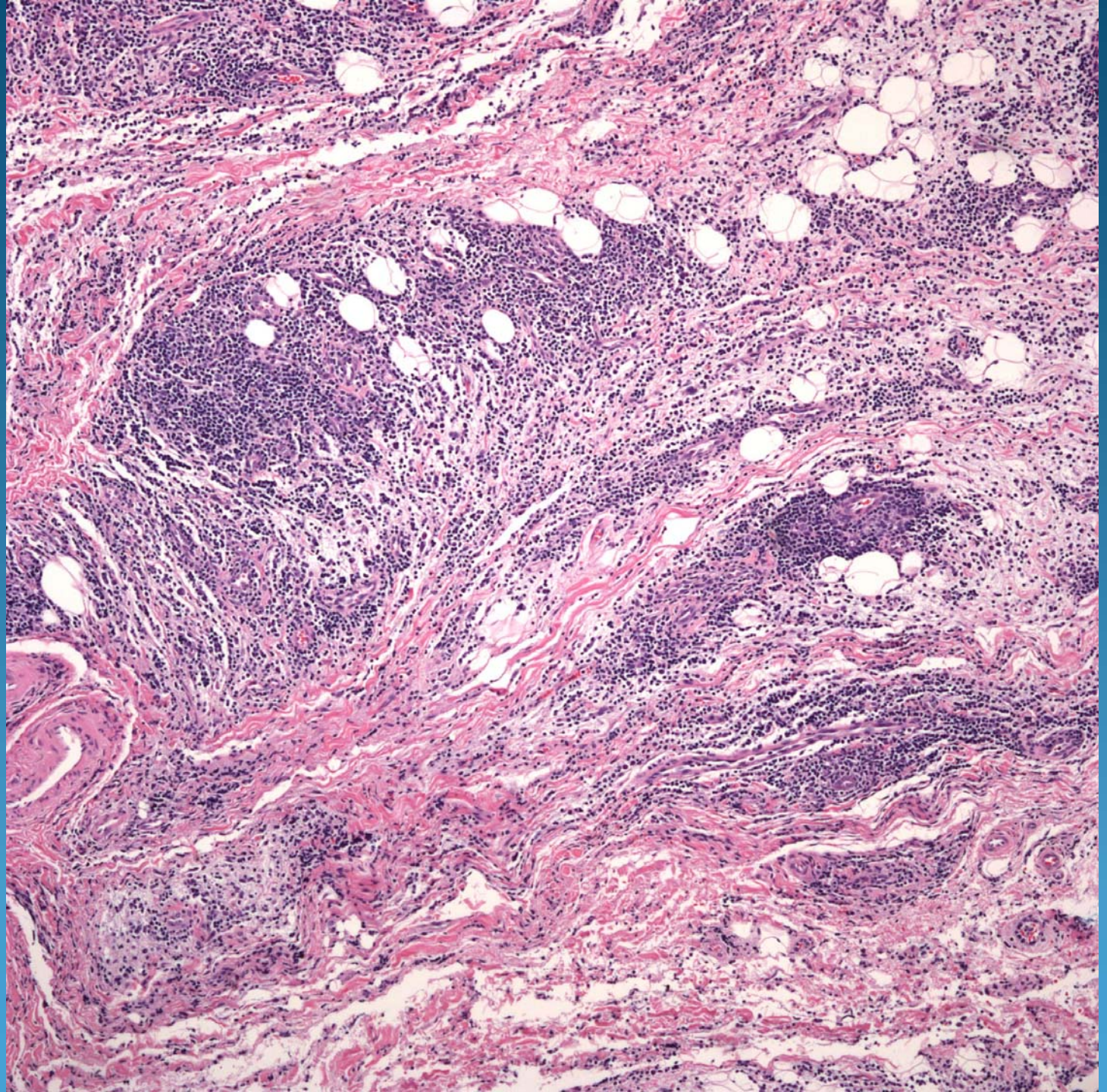

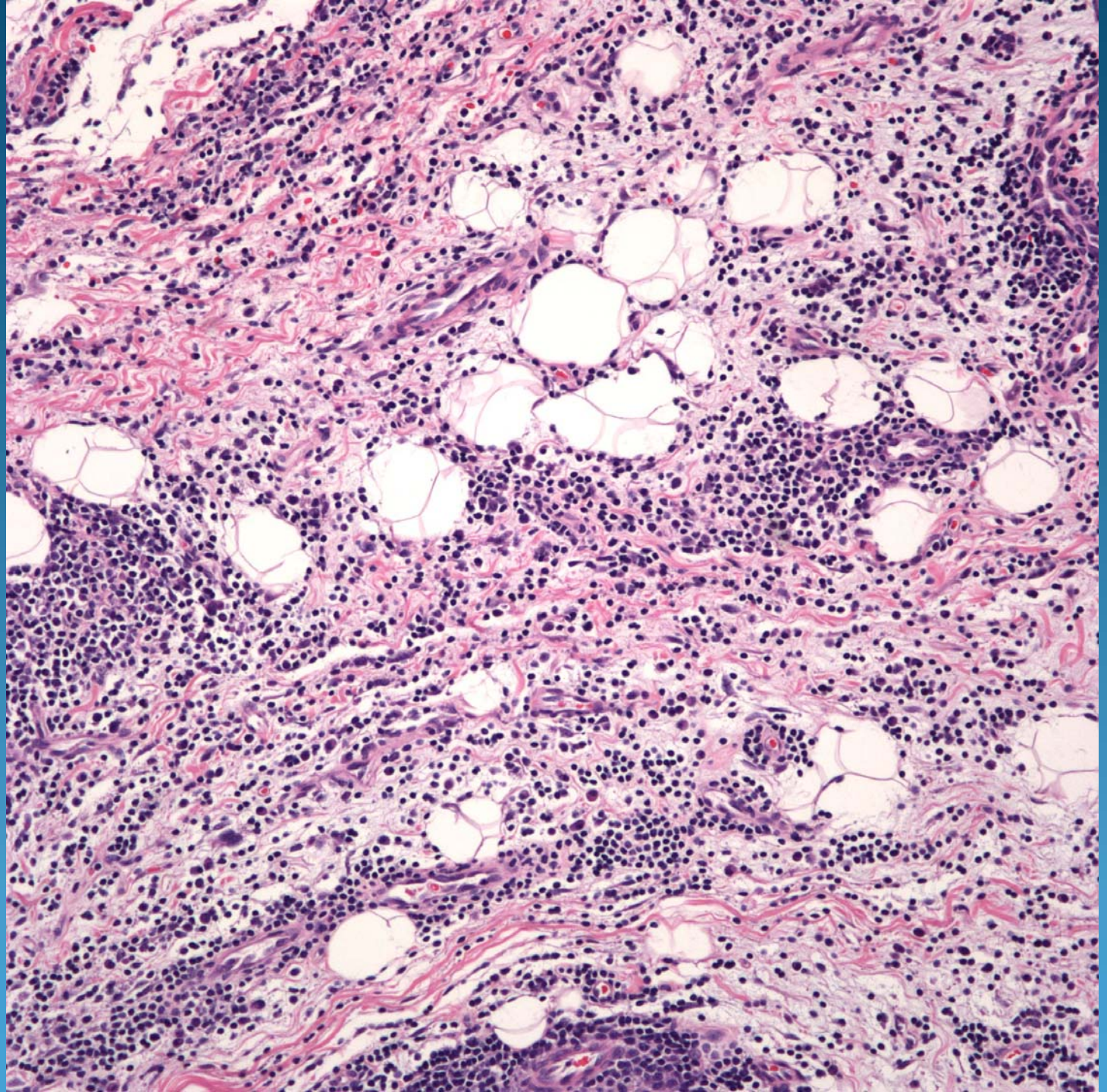

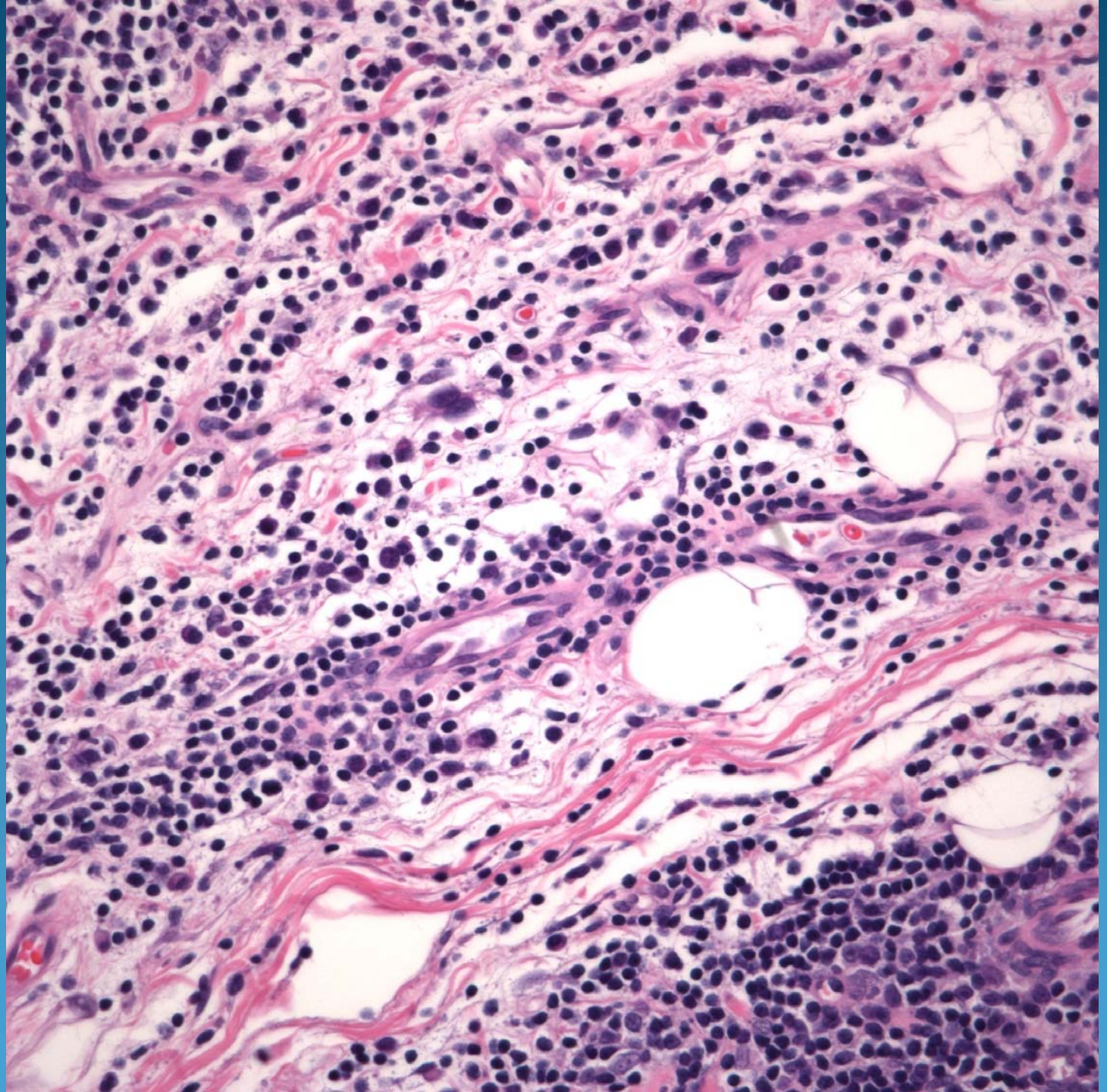

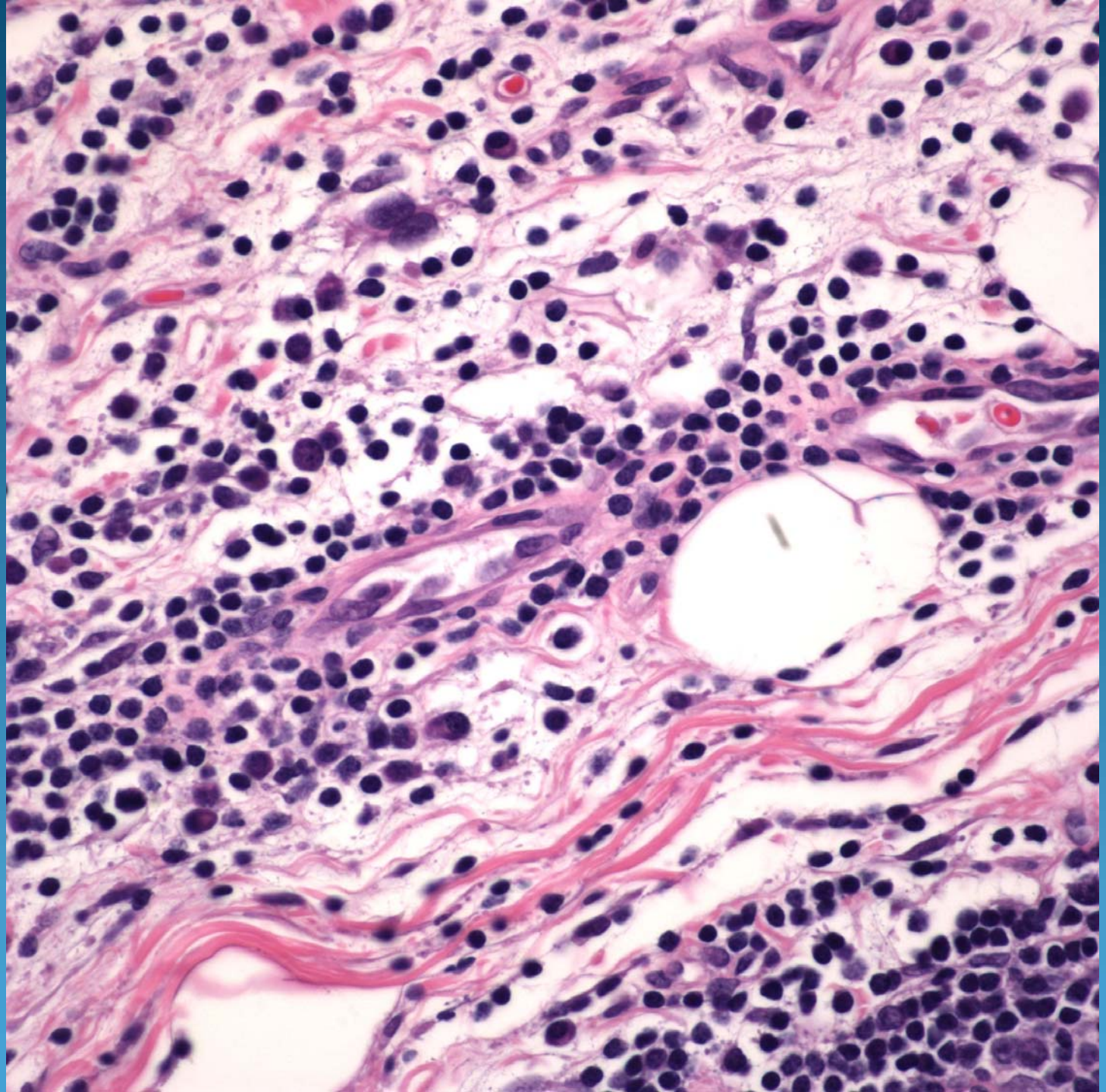

Lupus Profundus

Pearls

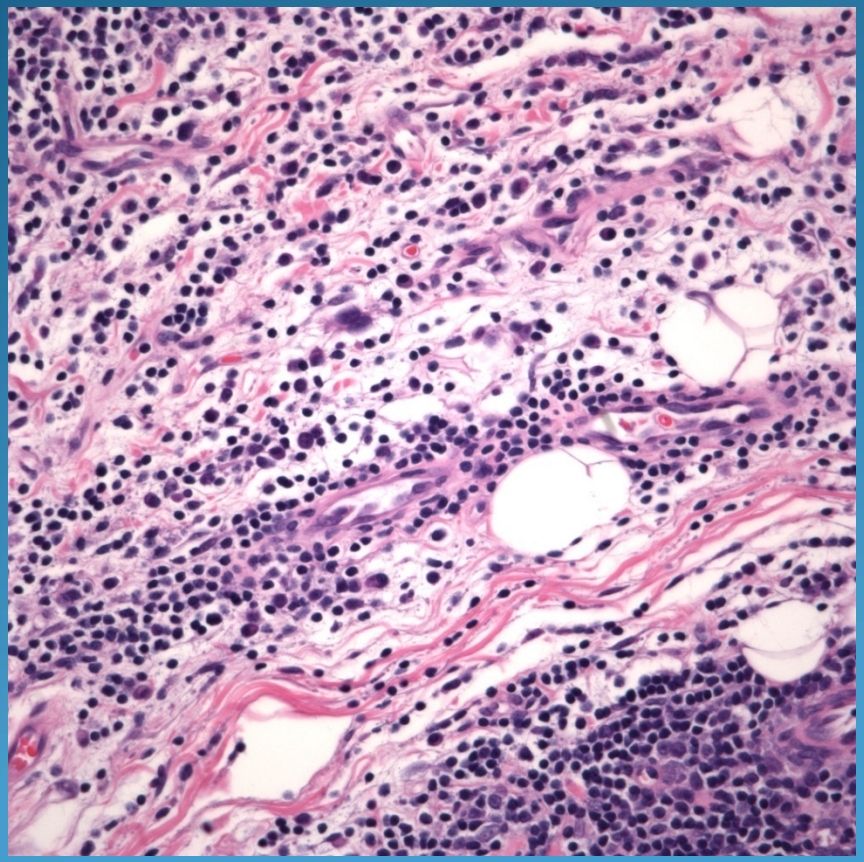

- Diffuse lobulocentric proliferation of mature lymphocytes and plasma cells
- Mucinous degeneration of fat
- No cytologic atypia of inflammatory cells
- May have overlying dermal changes of lupus
- Rule out T-cell dyscrasia/subcutaneous T-cell lymphoma