Dermatopathology Slide Review Part 39

Paul K. Shitabata, M.D.
Dermatopathology Institute

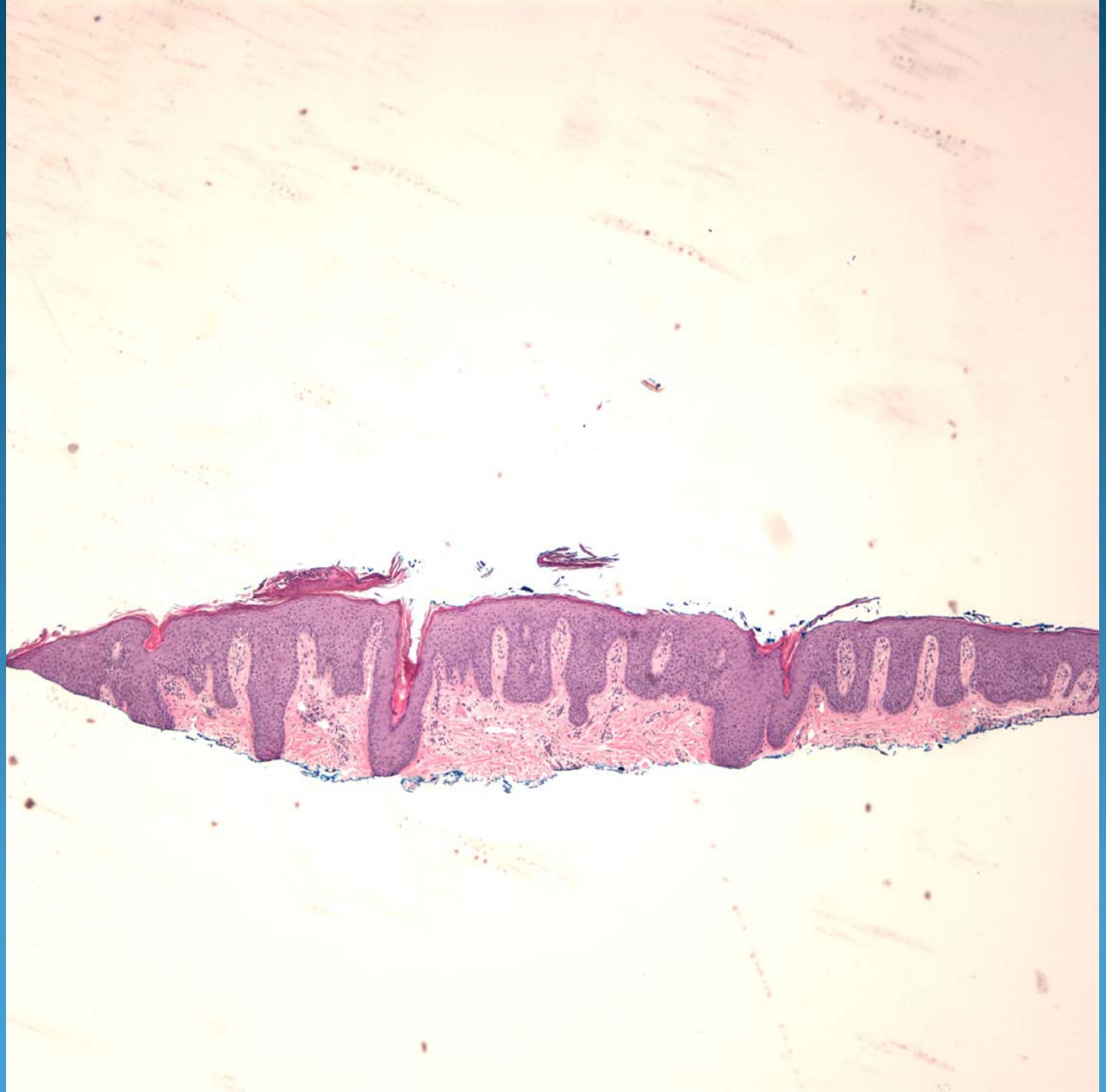

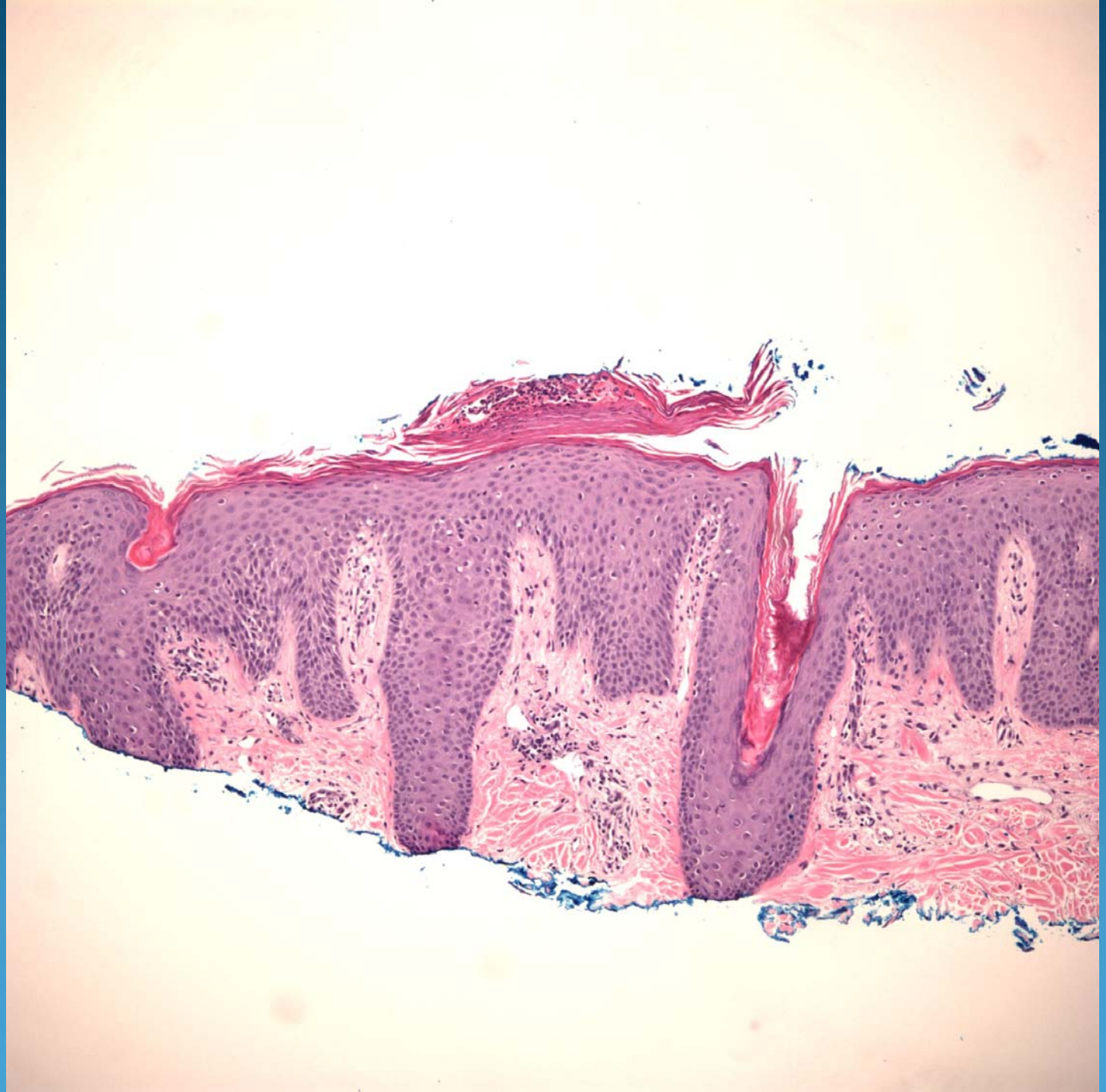

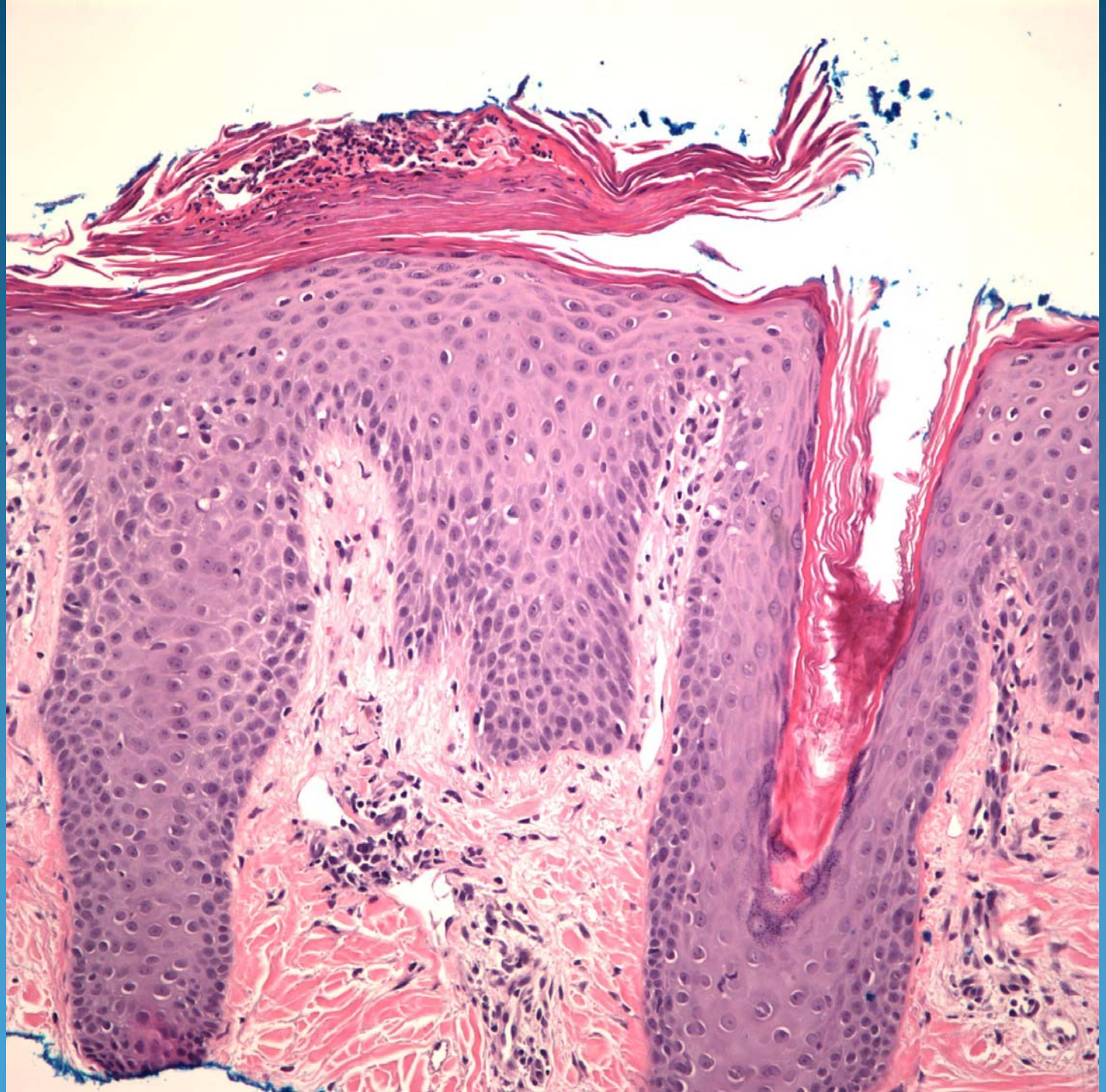

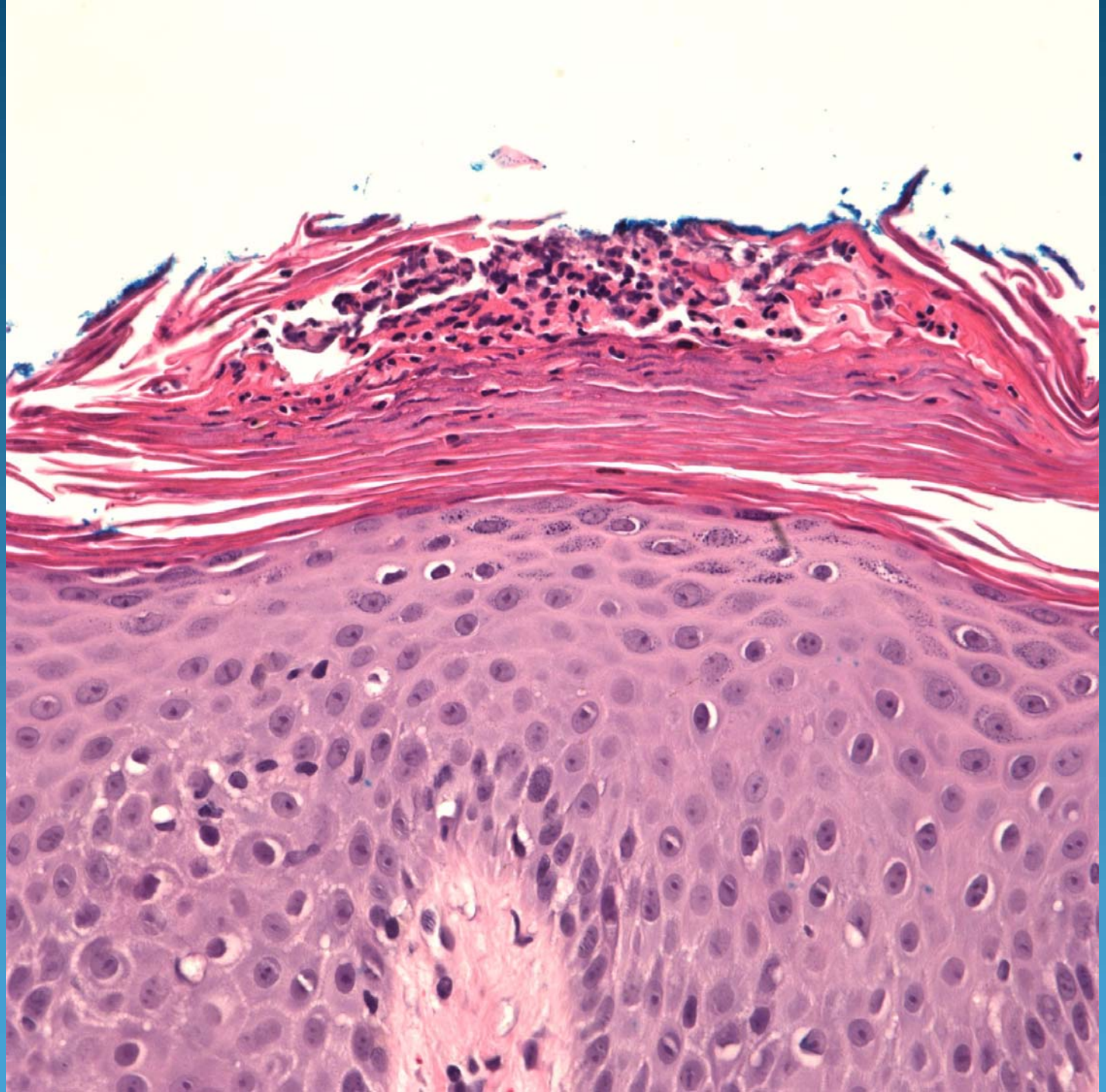

Seborrheic Dermatitis

Pearls

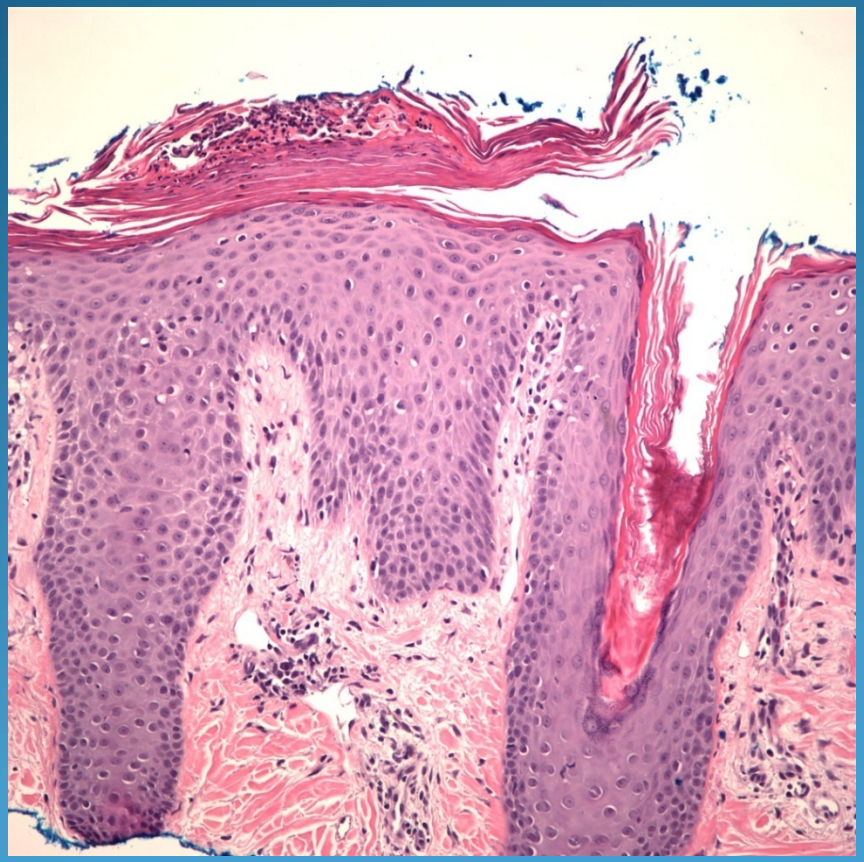

- Intracorneal collection of neutrophils at infundibular lip
- Rule out Psoriasis
- Rule out Dermatophyte

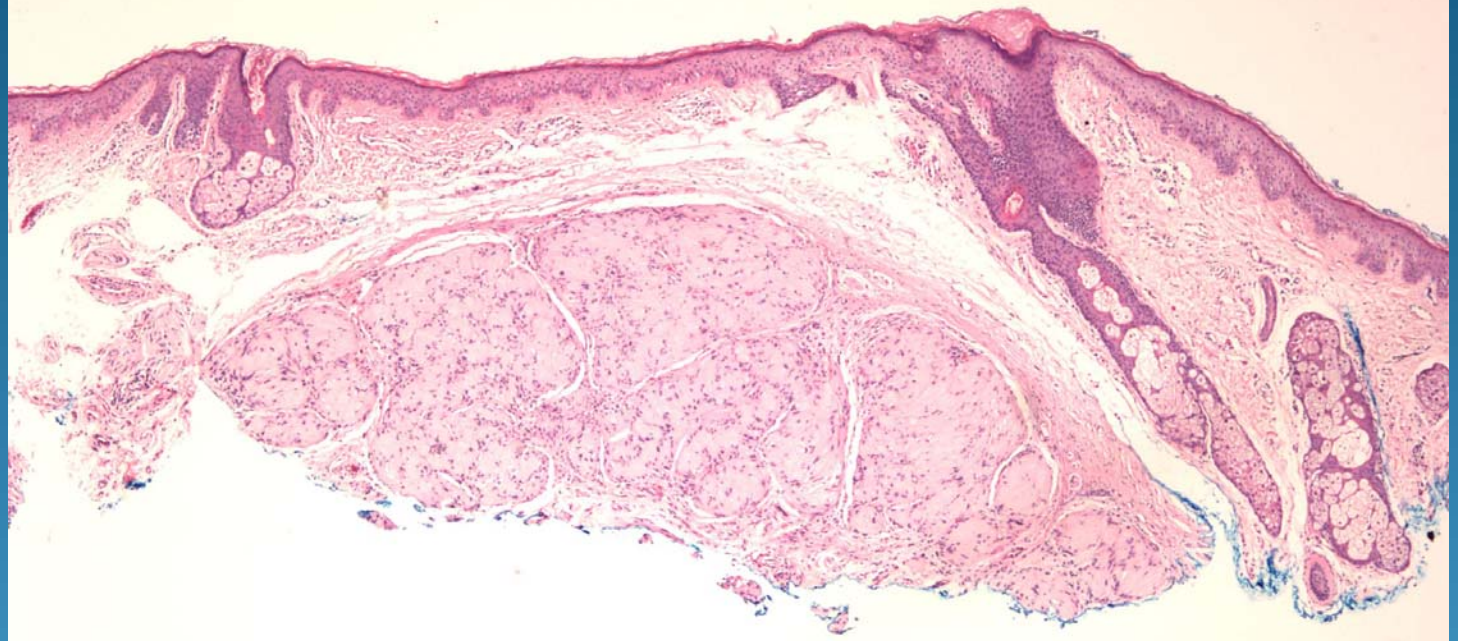

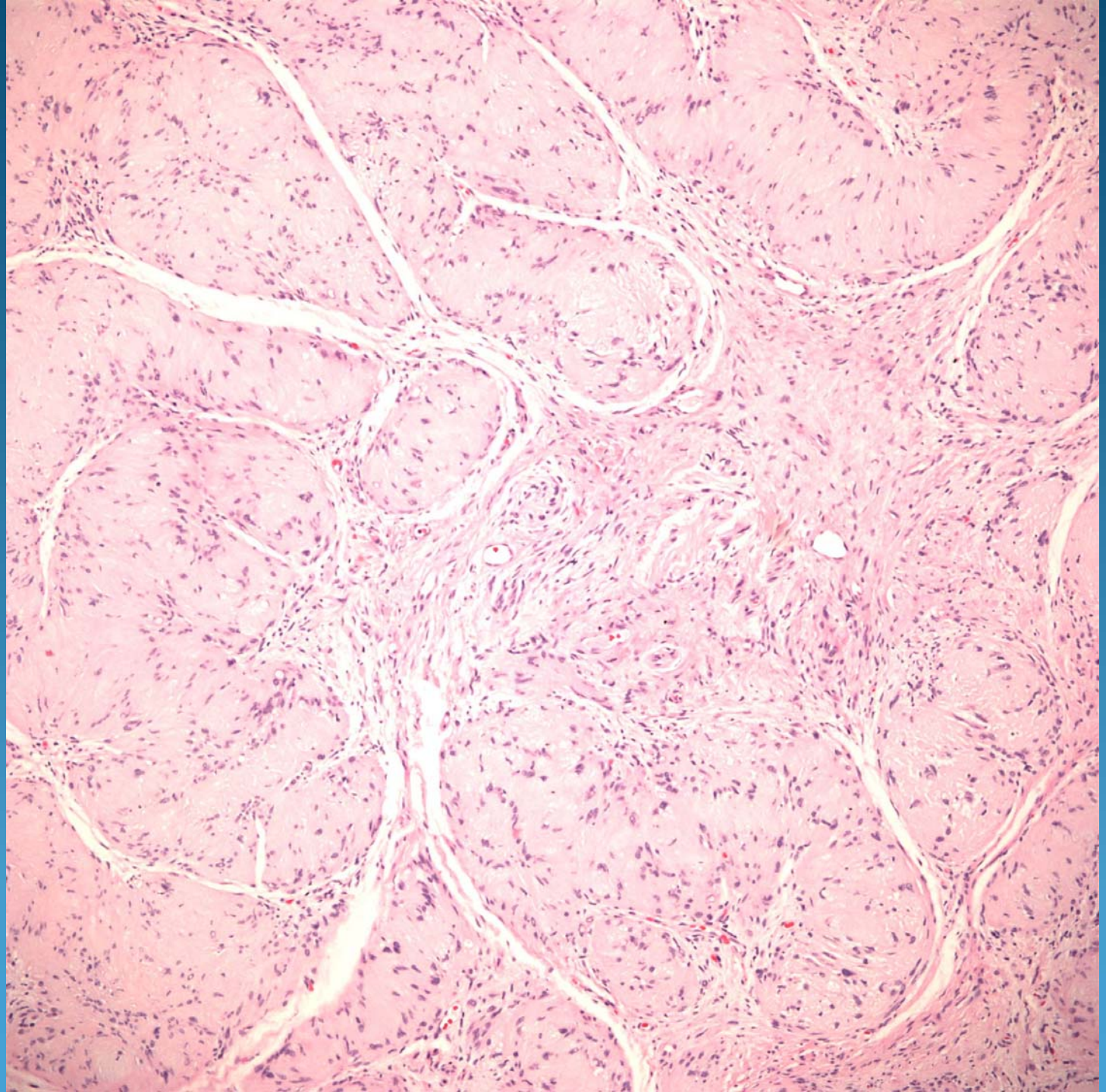

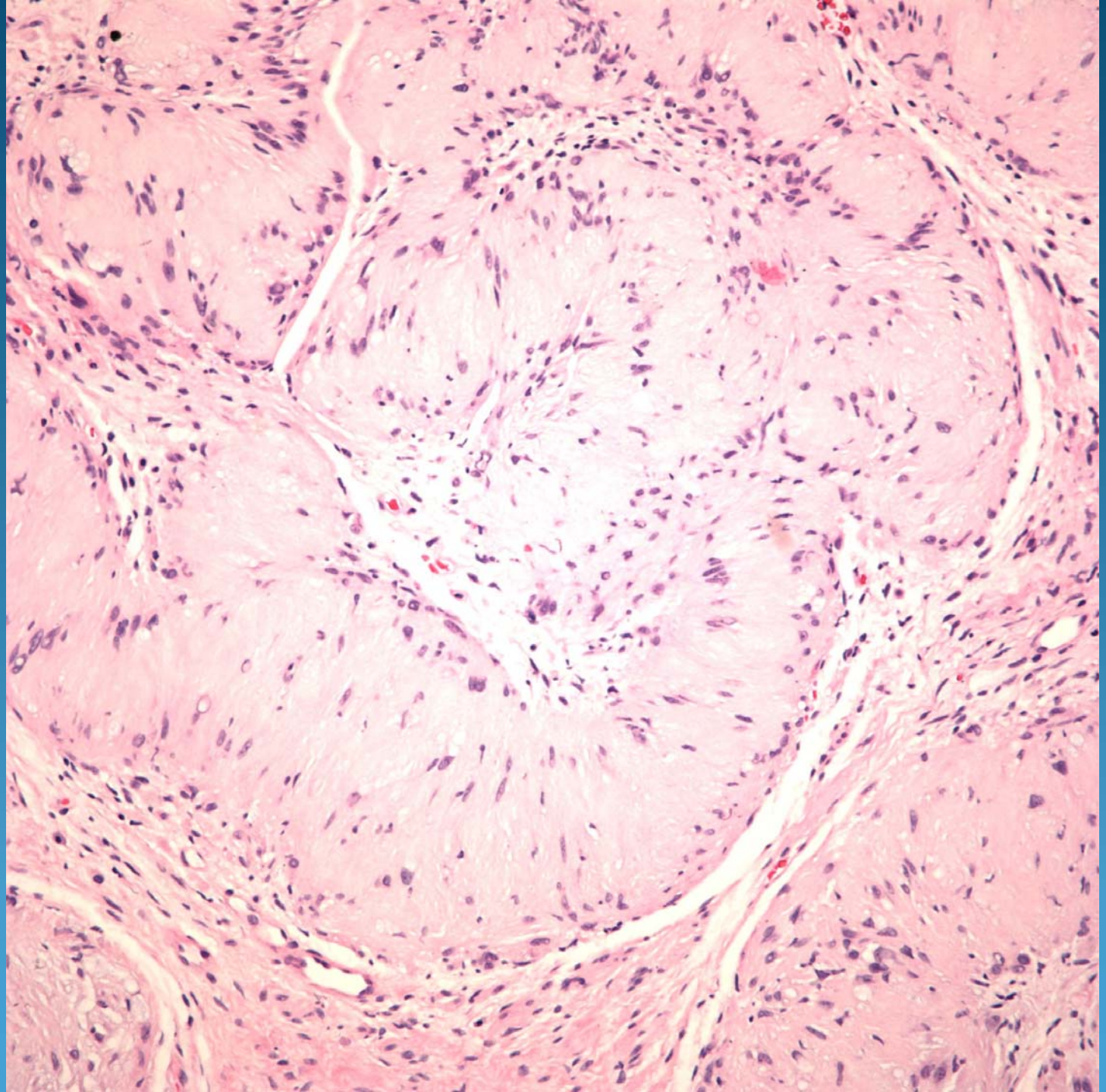

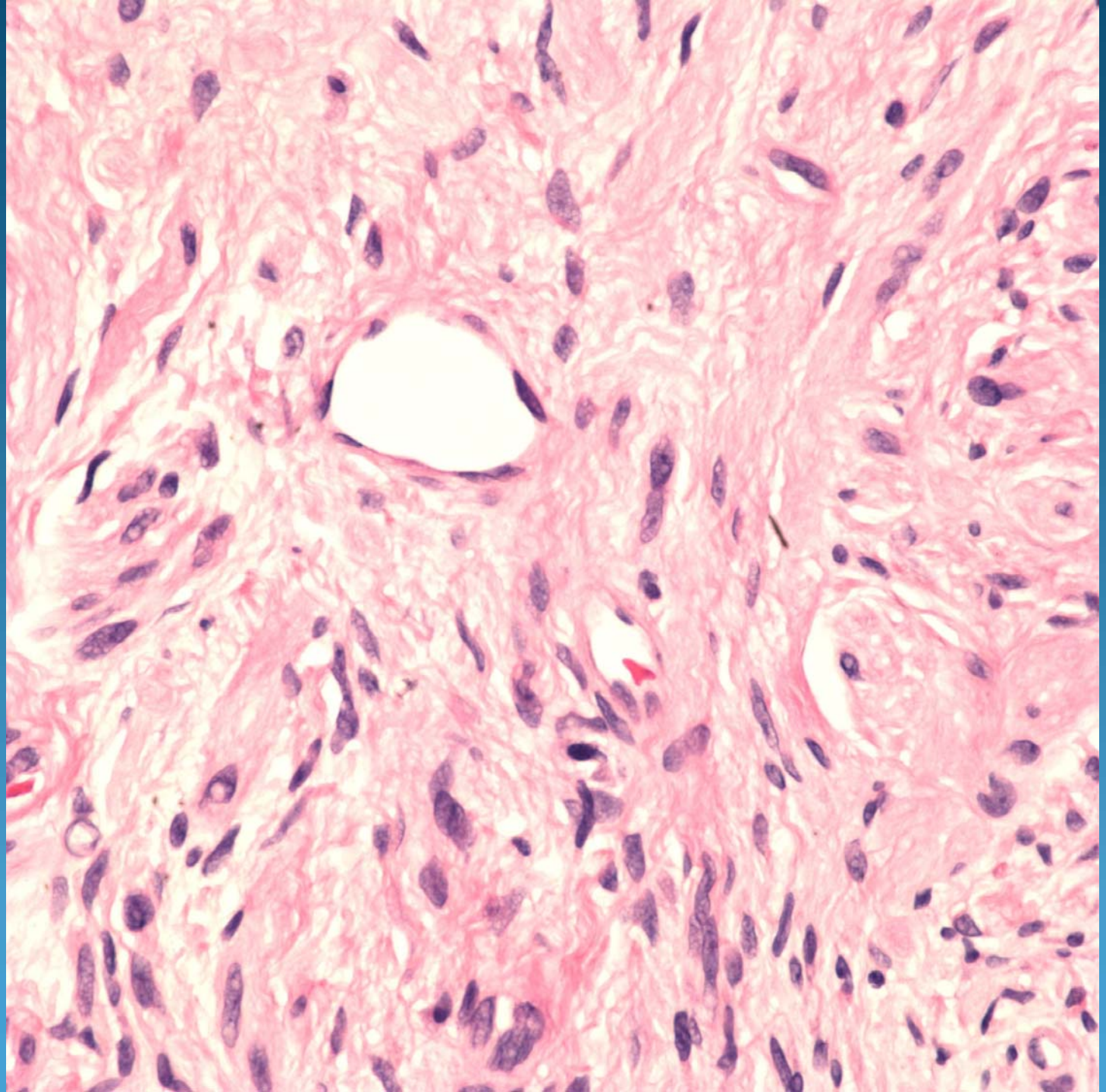

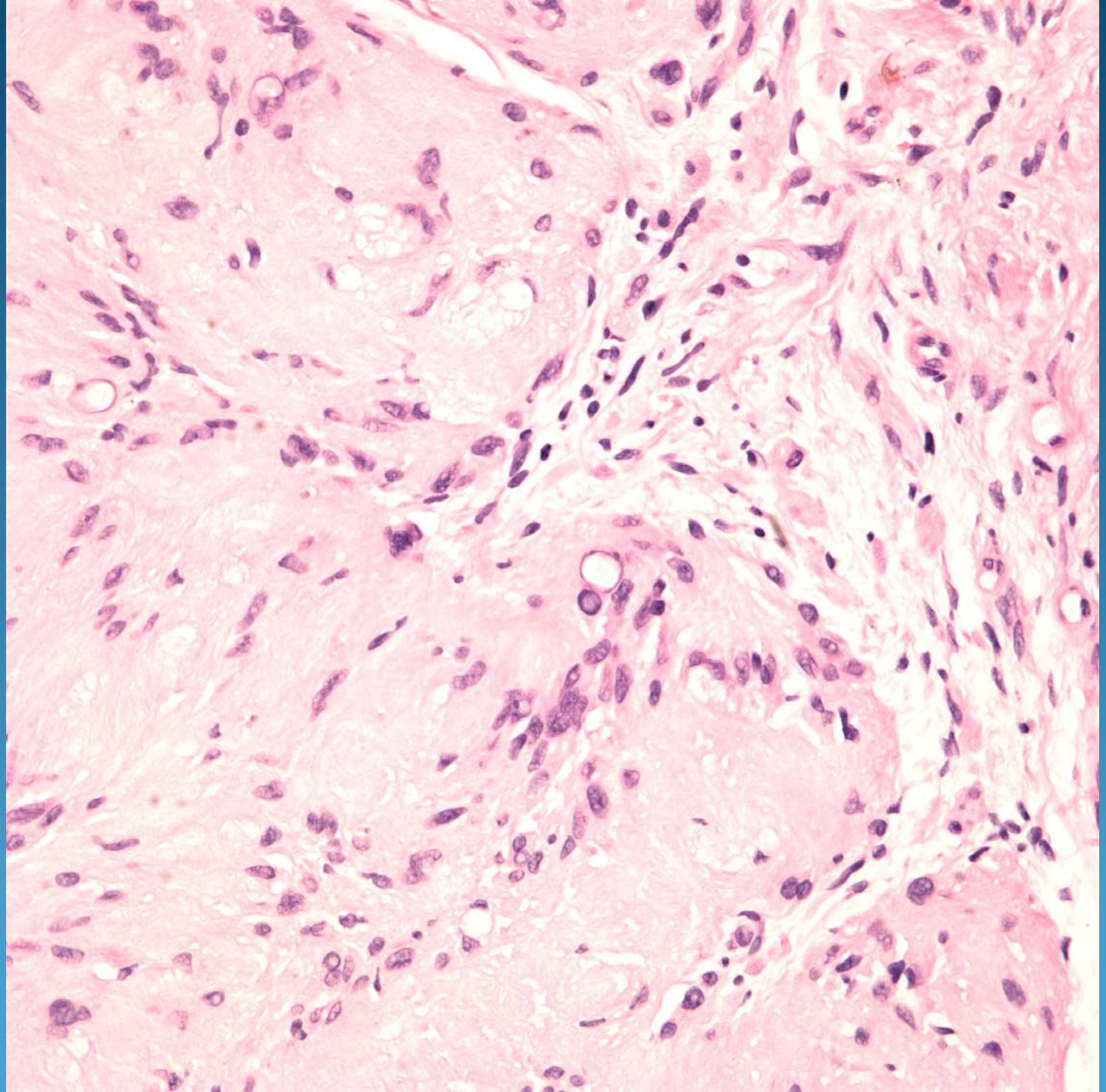

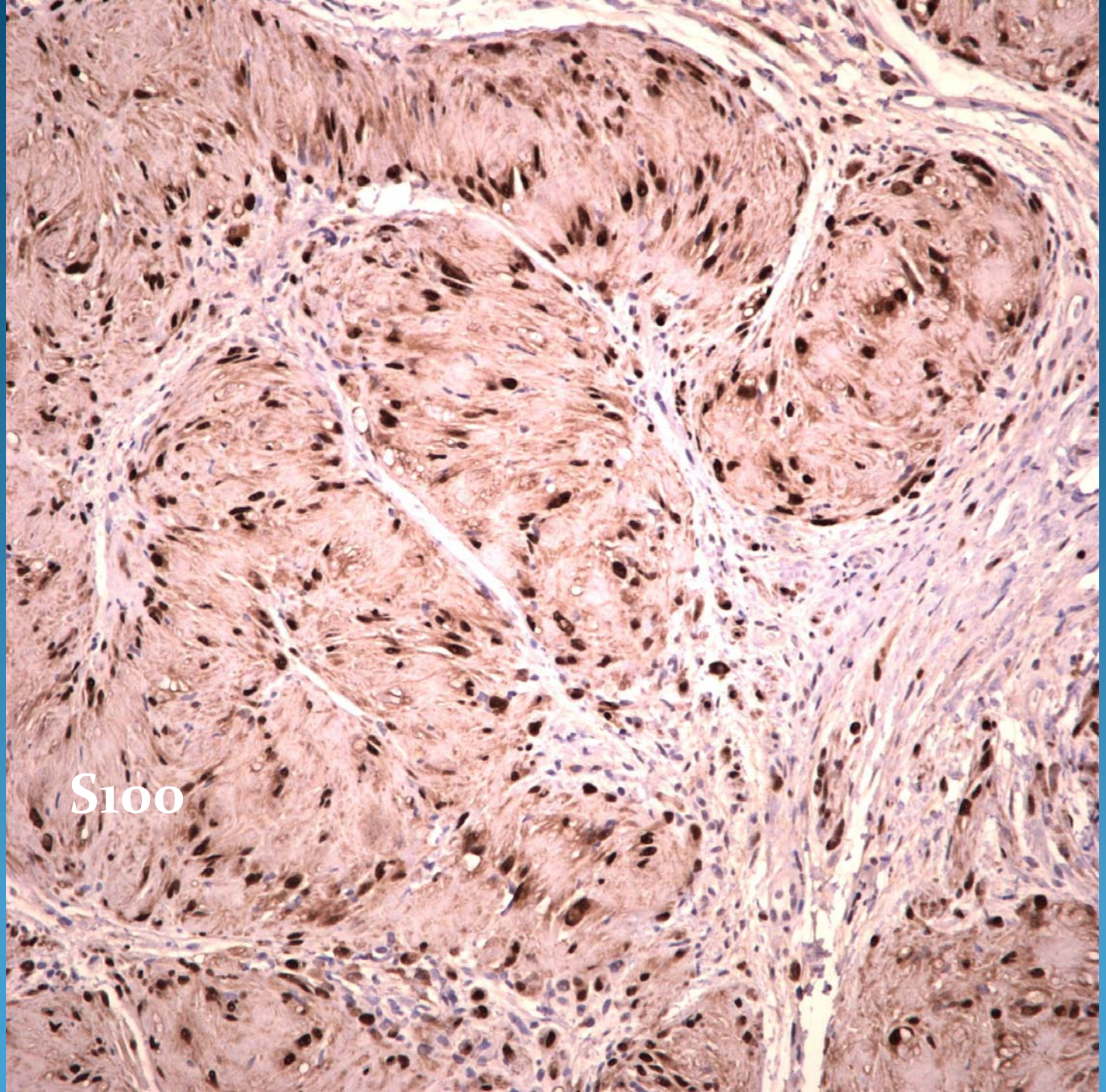
S100

Cutaneous Schwannoma

Pearls

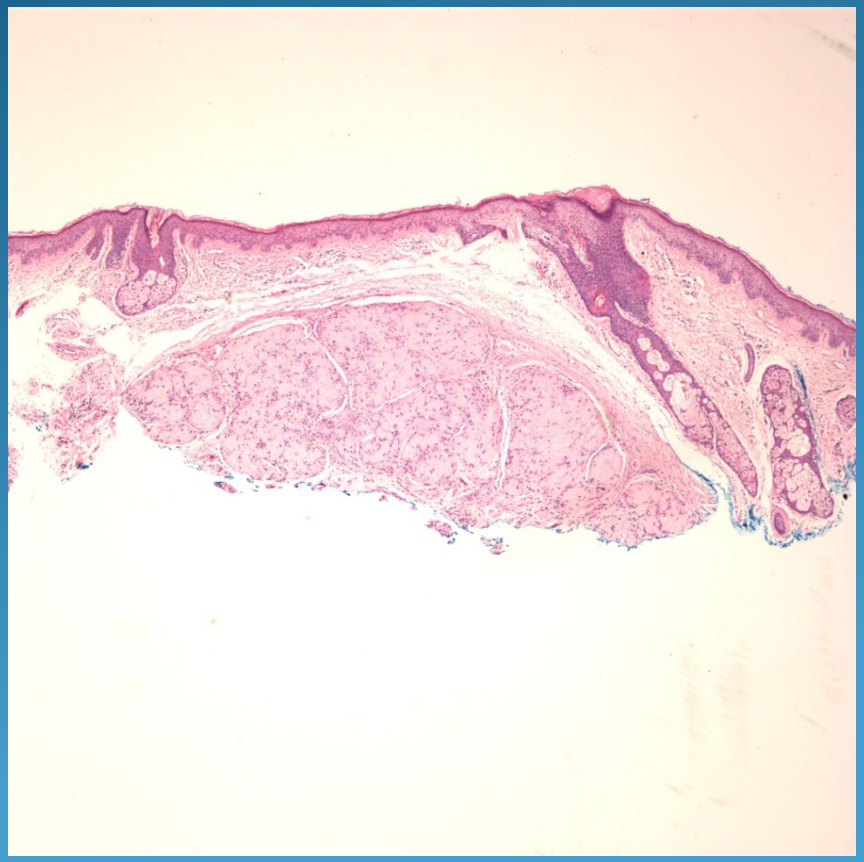

- Circumscribed dermal tumor
- Spindle cells with wavy nuclei
- May have Antoni A and B fibers
- Verrocay bodies with vascular hyalinization
- Unusual variants with predominately Antoni A and Verrocay bodies

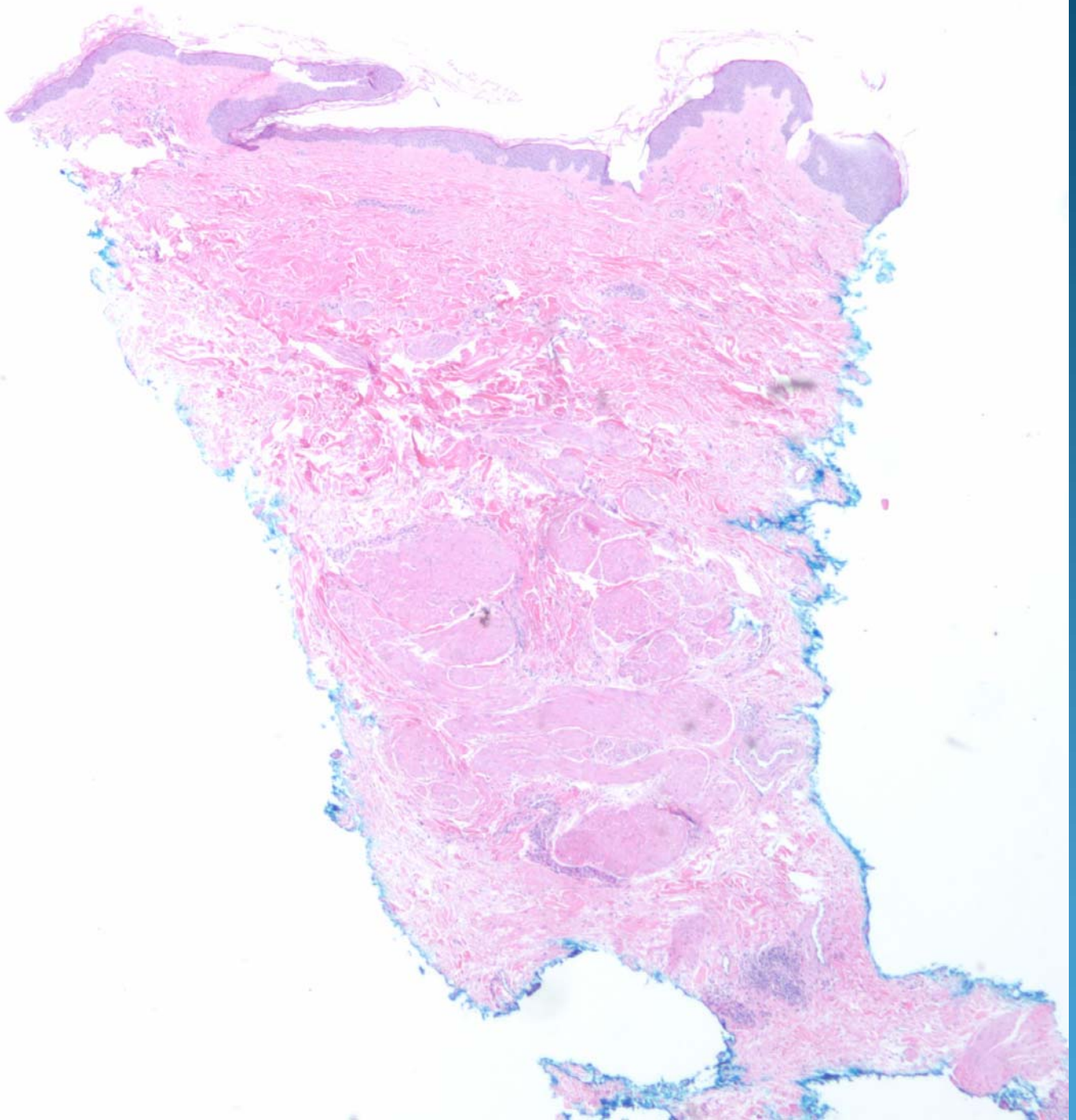

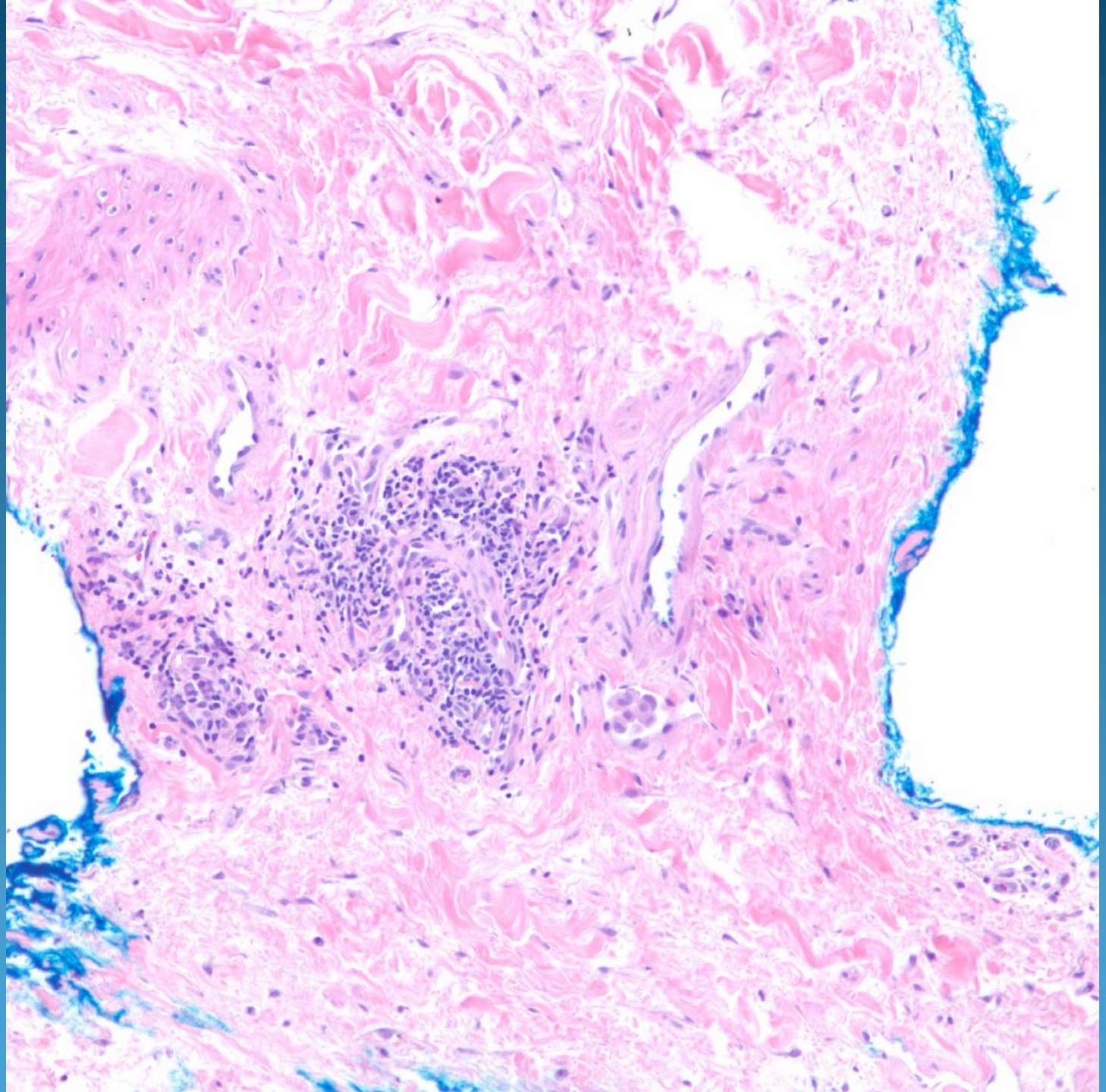

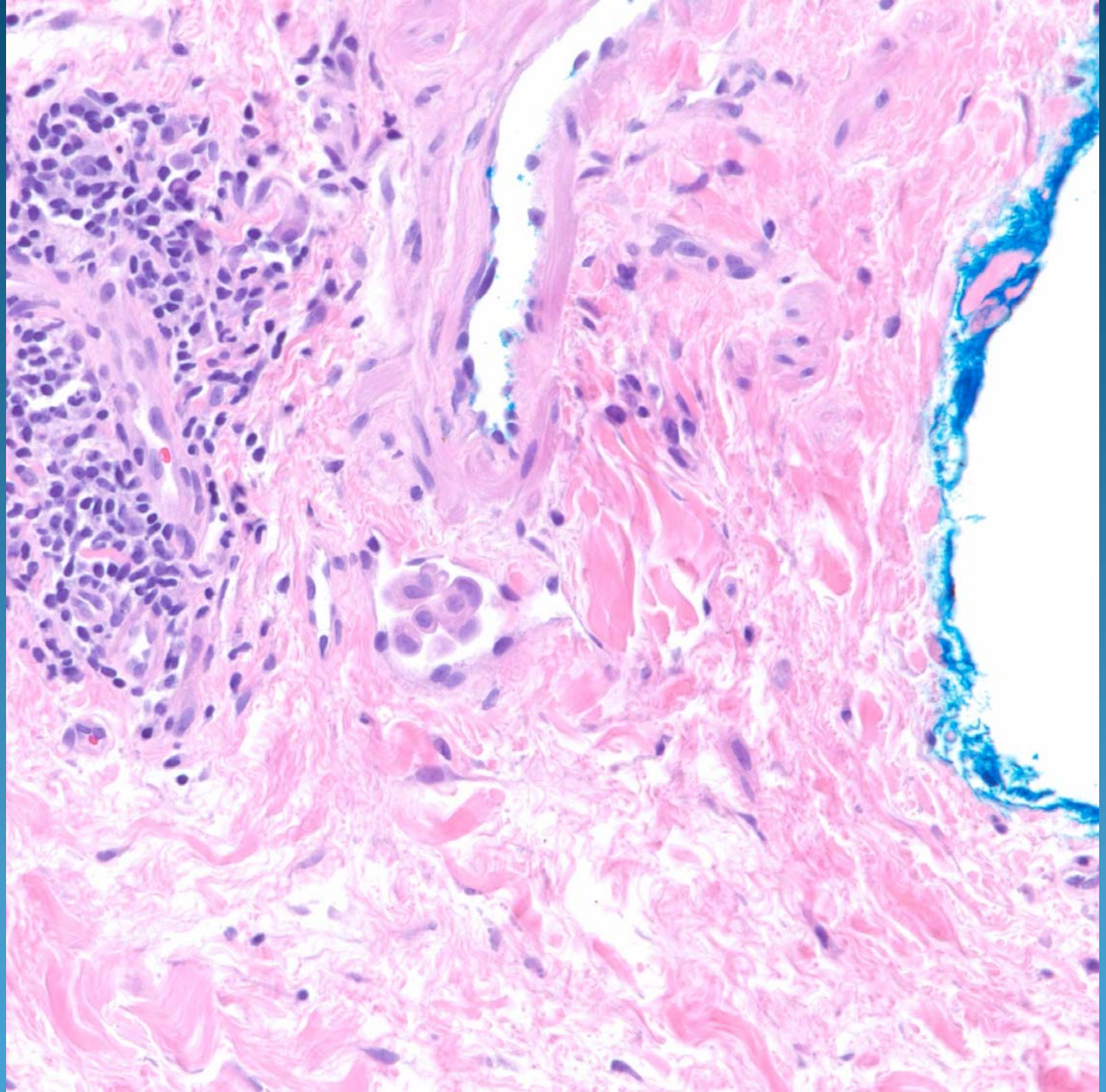

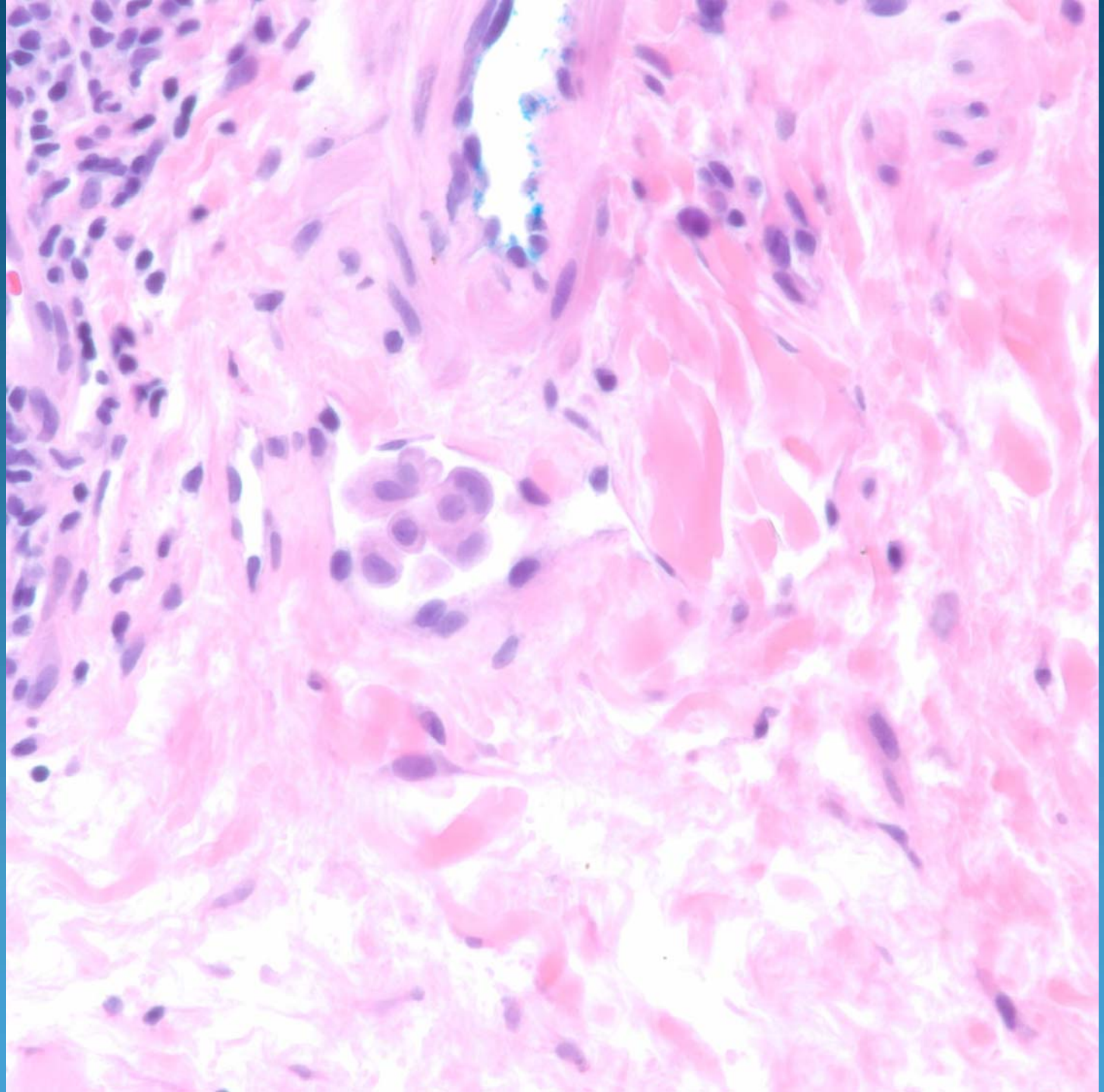

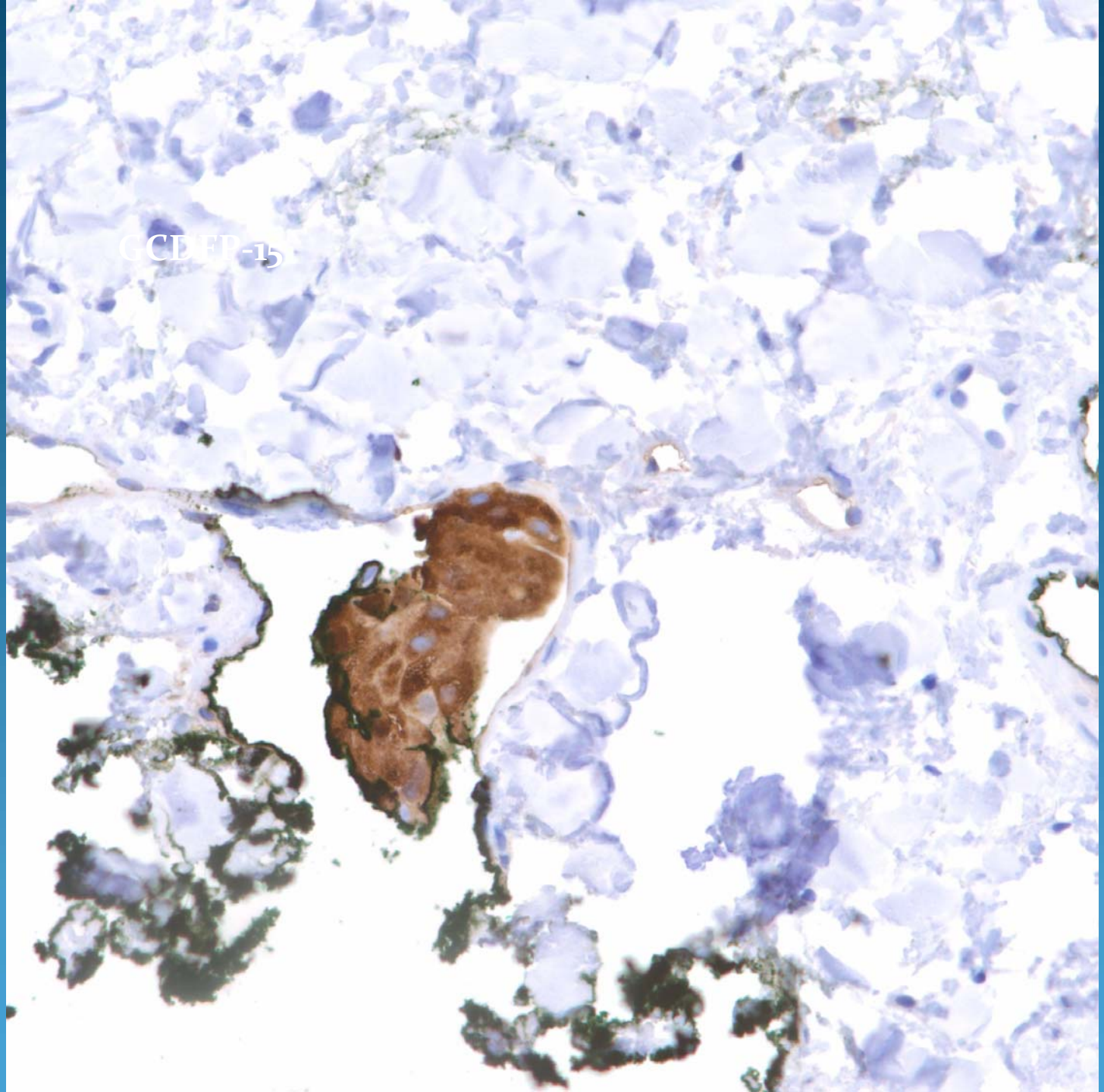
GDF-15

Metastatic Adenocarcinoma Consistent with Breast Primary

Pearls

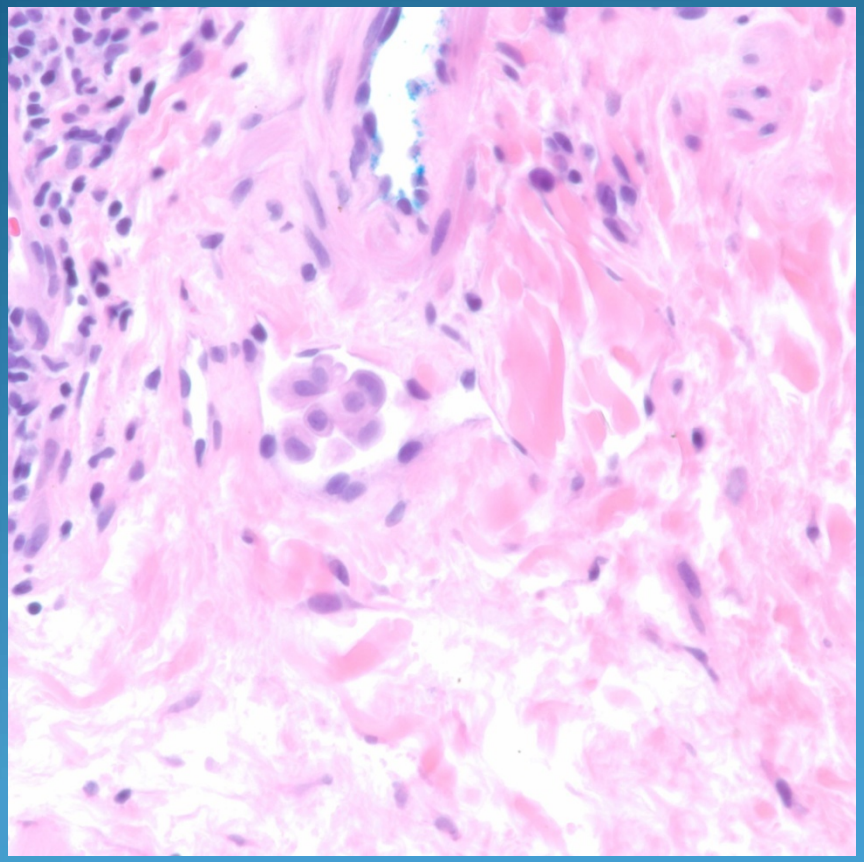

- Metastatic disease may occasionally be intravascular
- May need IHC to confirm

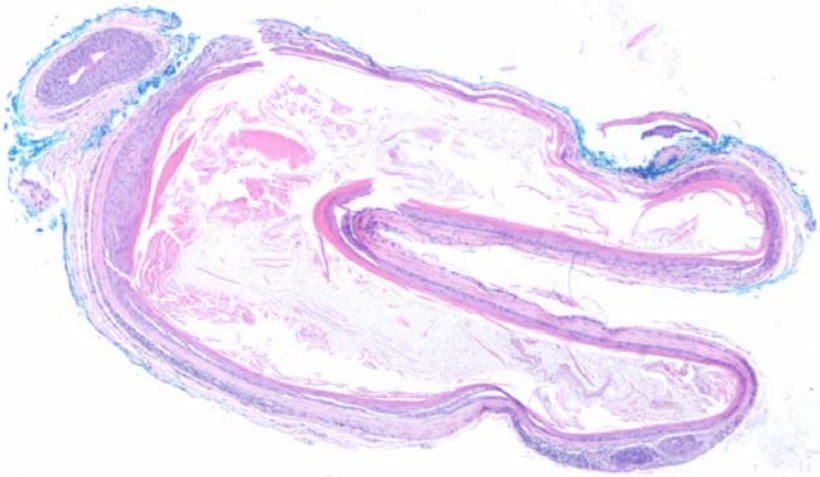

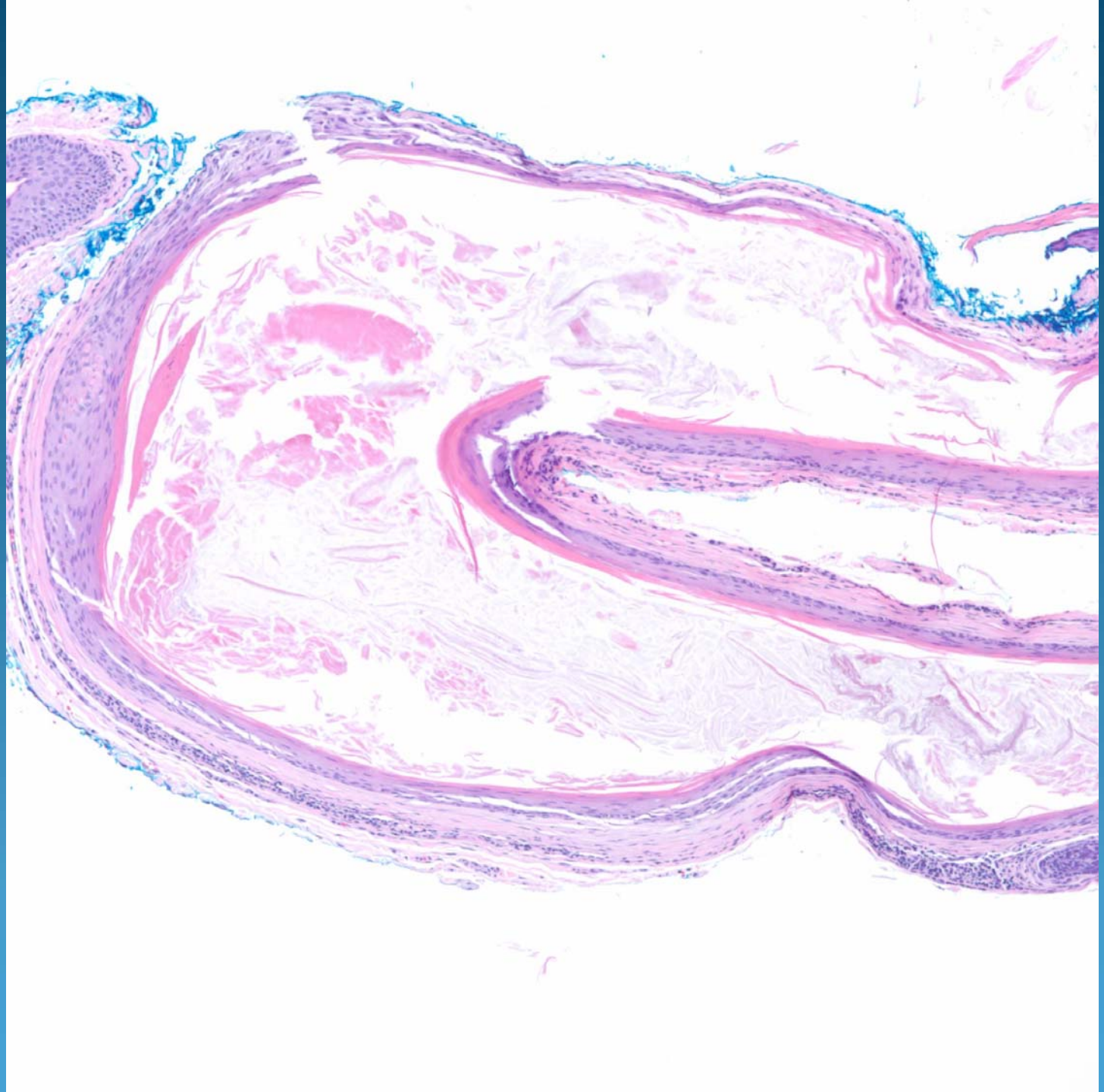

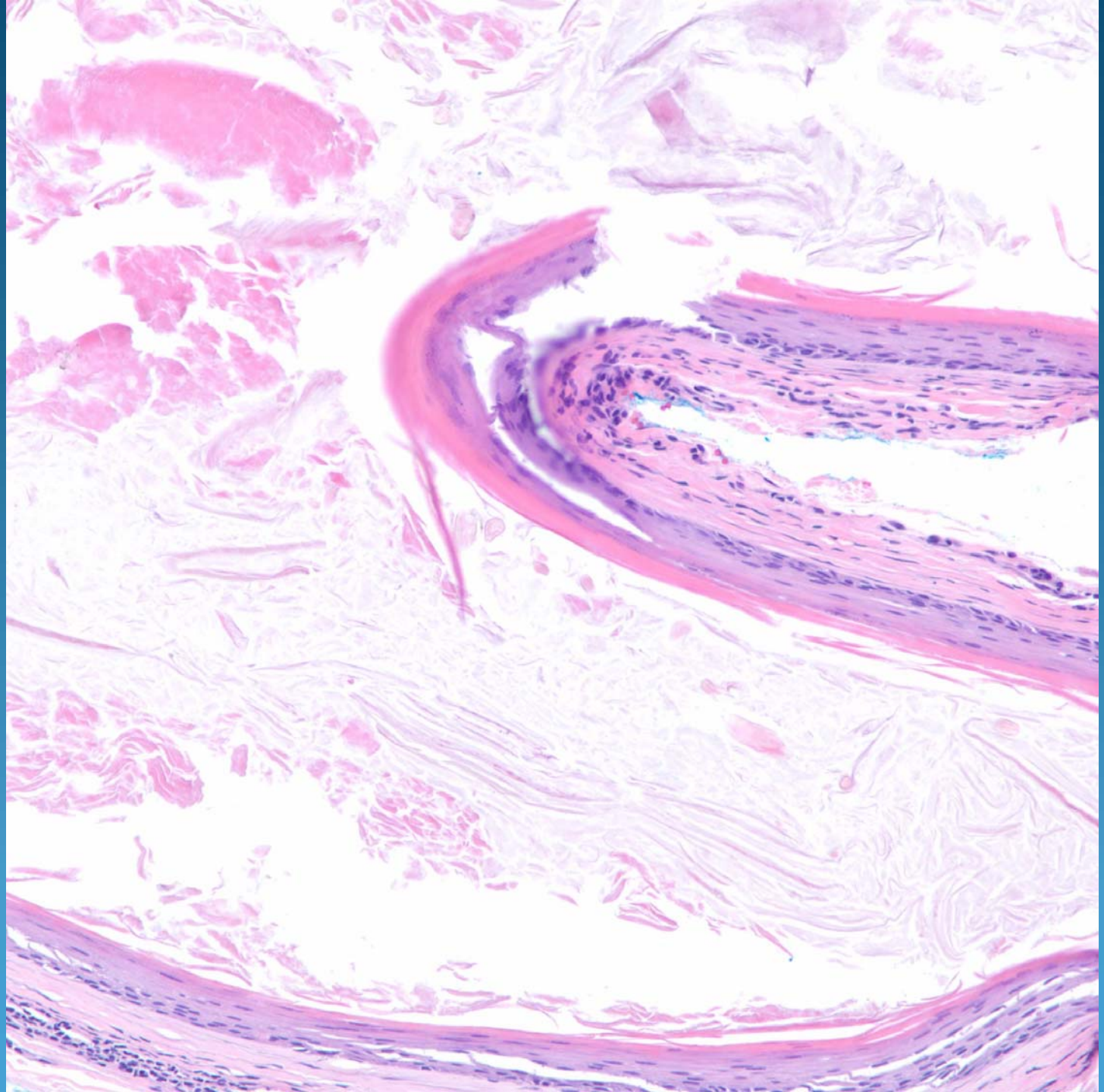

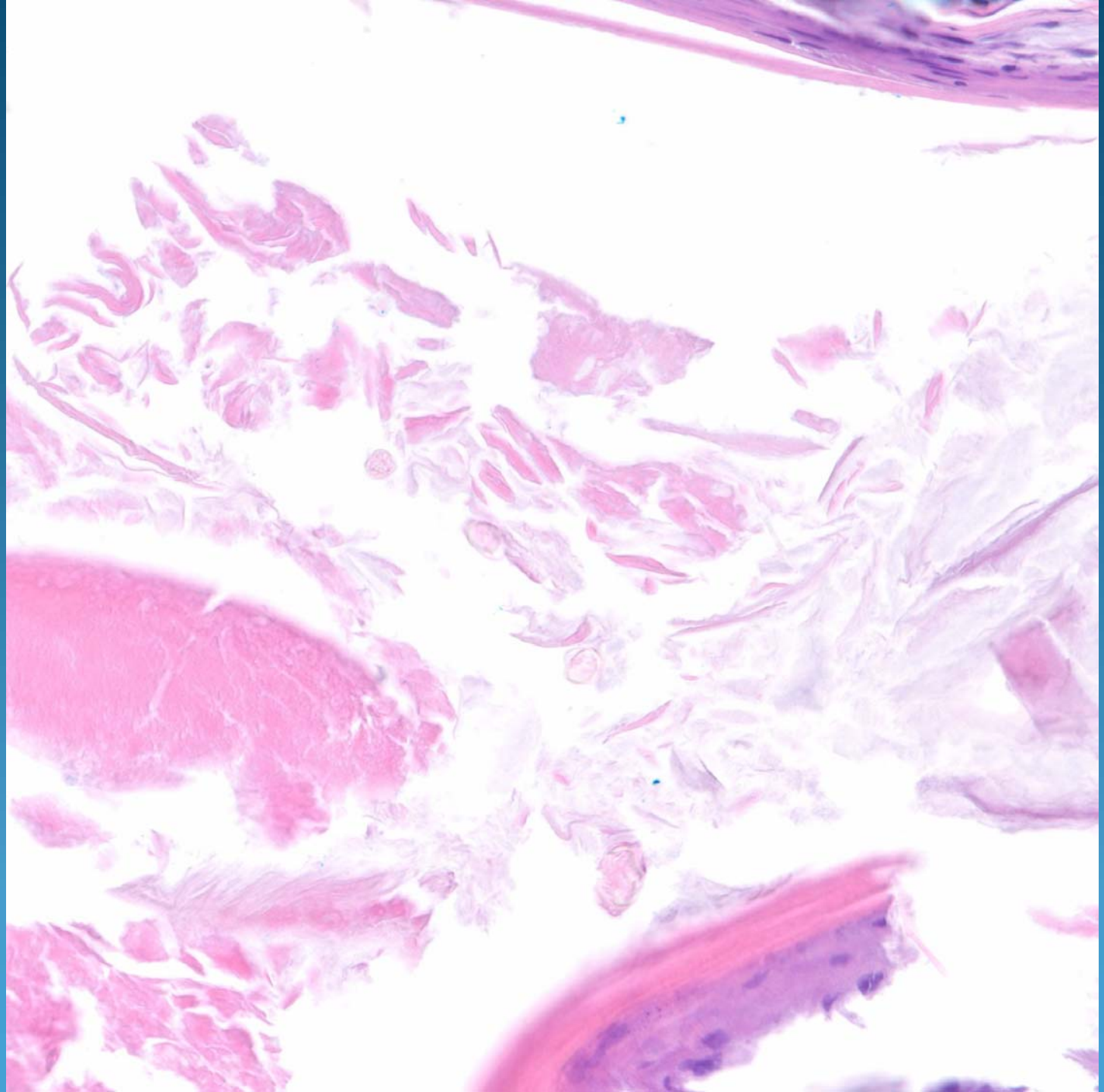

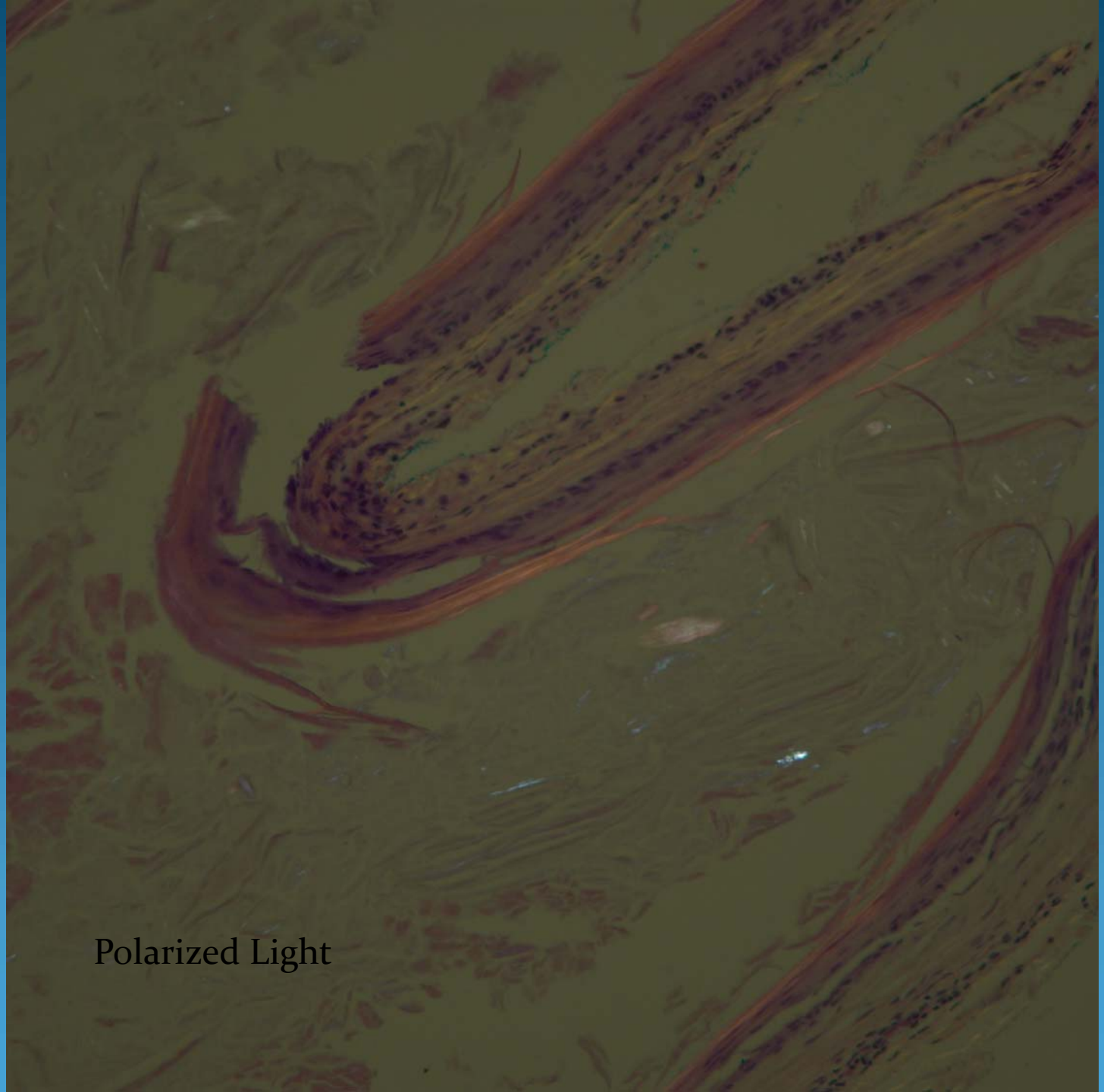

Polarized Light

Vellus Hair Cyst

Pearls

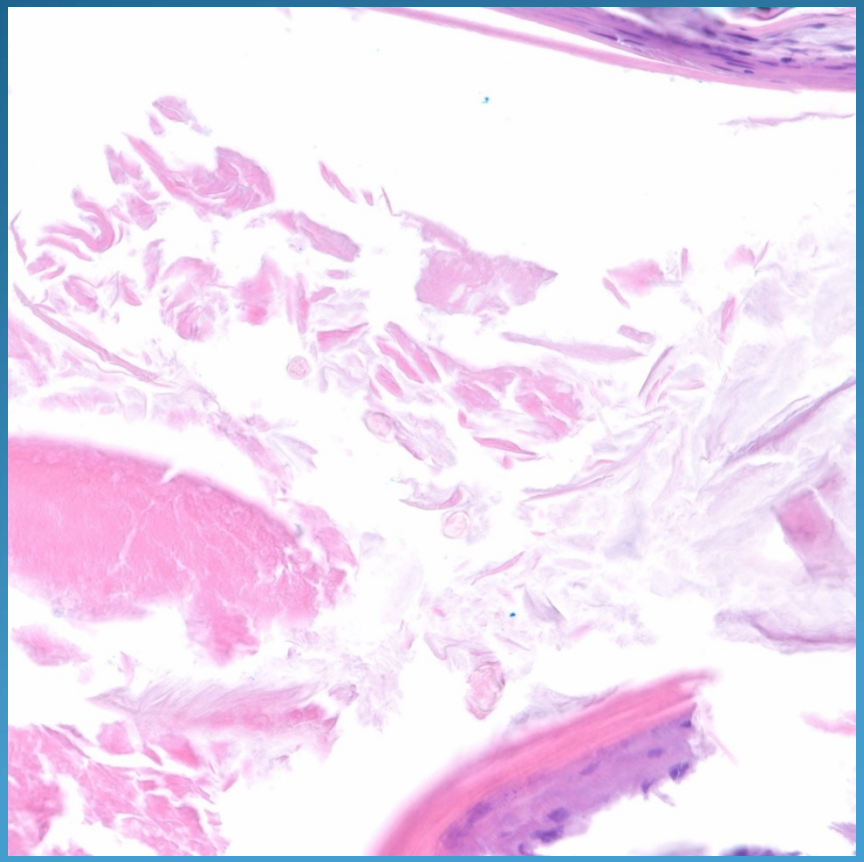

- Epithelial cyst surrounding laminated keratin
- Look for vellus hairs, may need to examine with polarized light
- Lacks sebaceous lobules in the wall, rule out steatocystoma

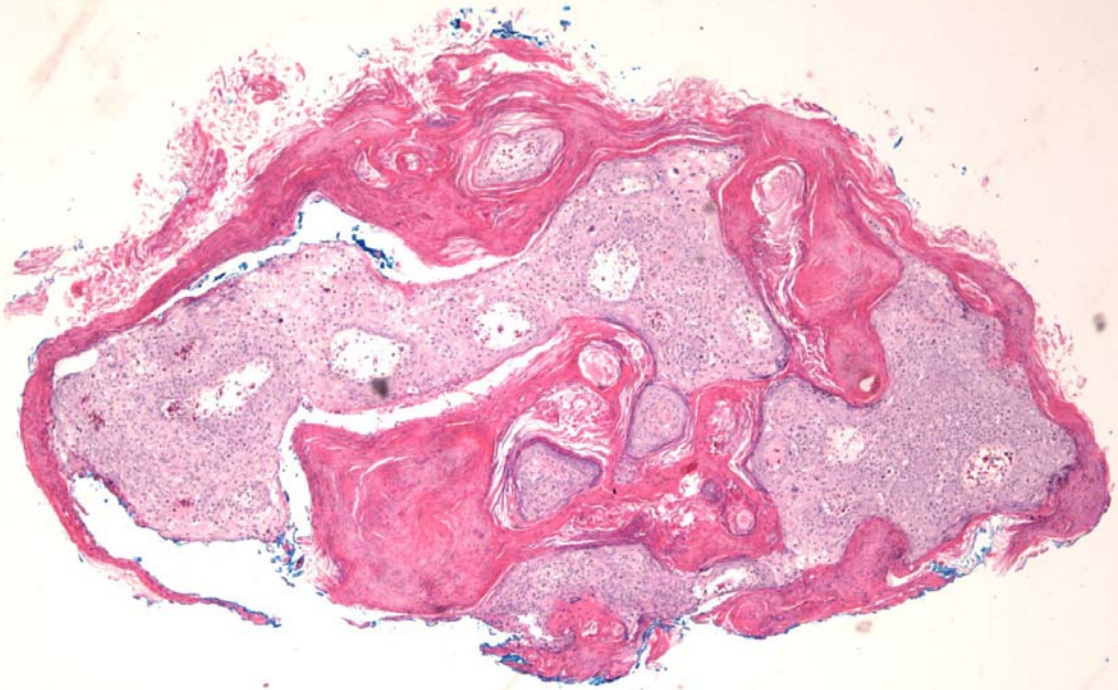

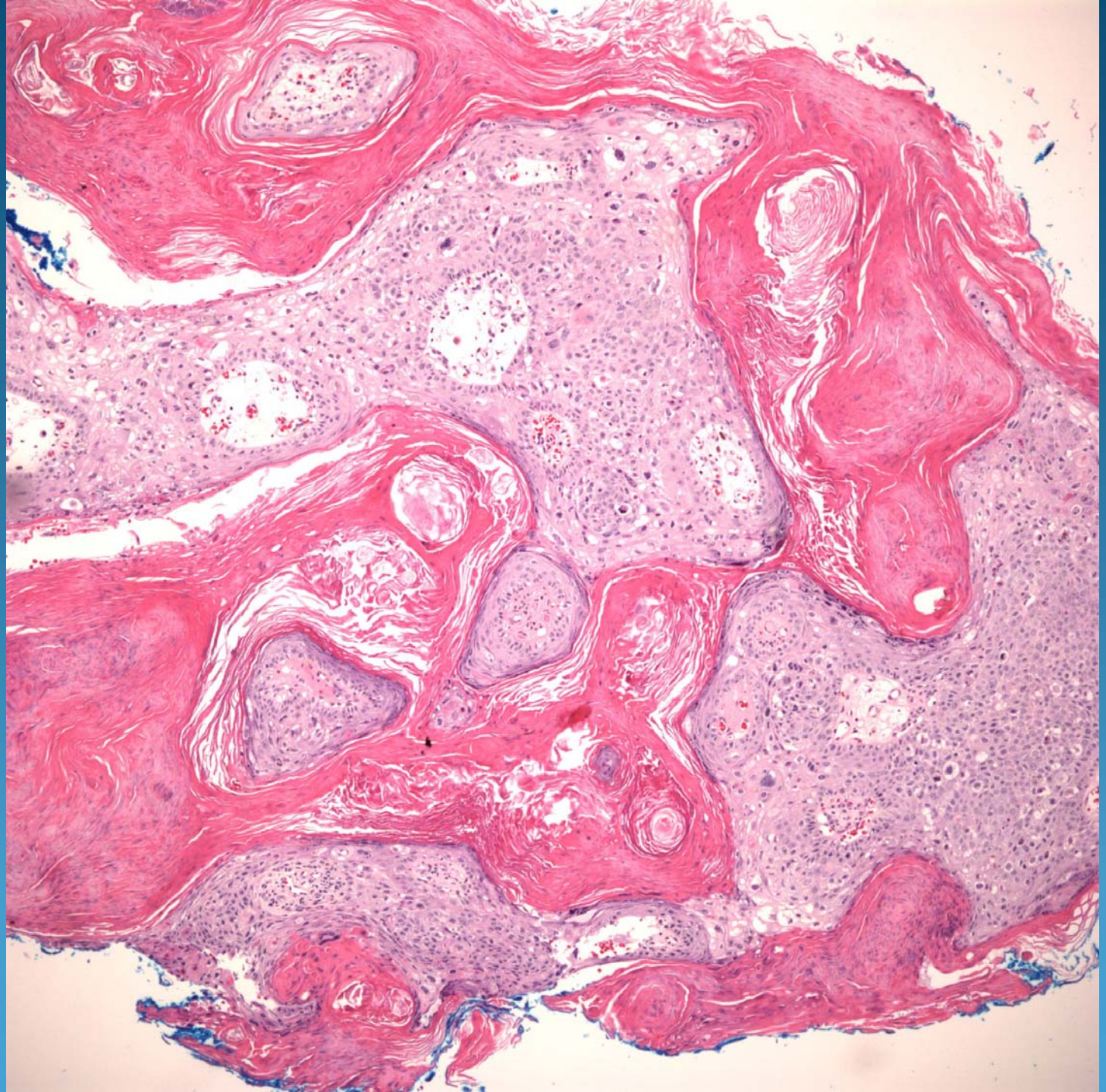

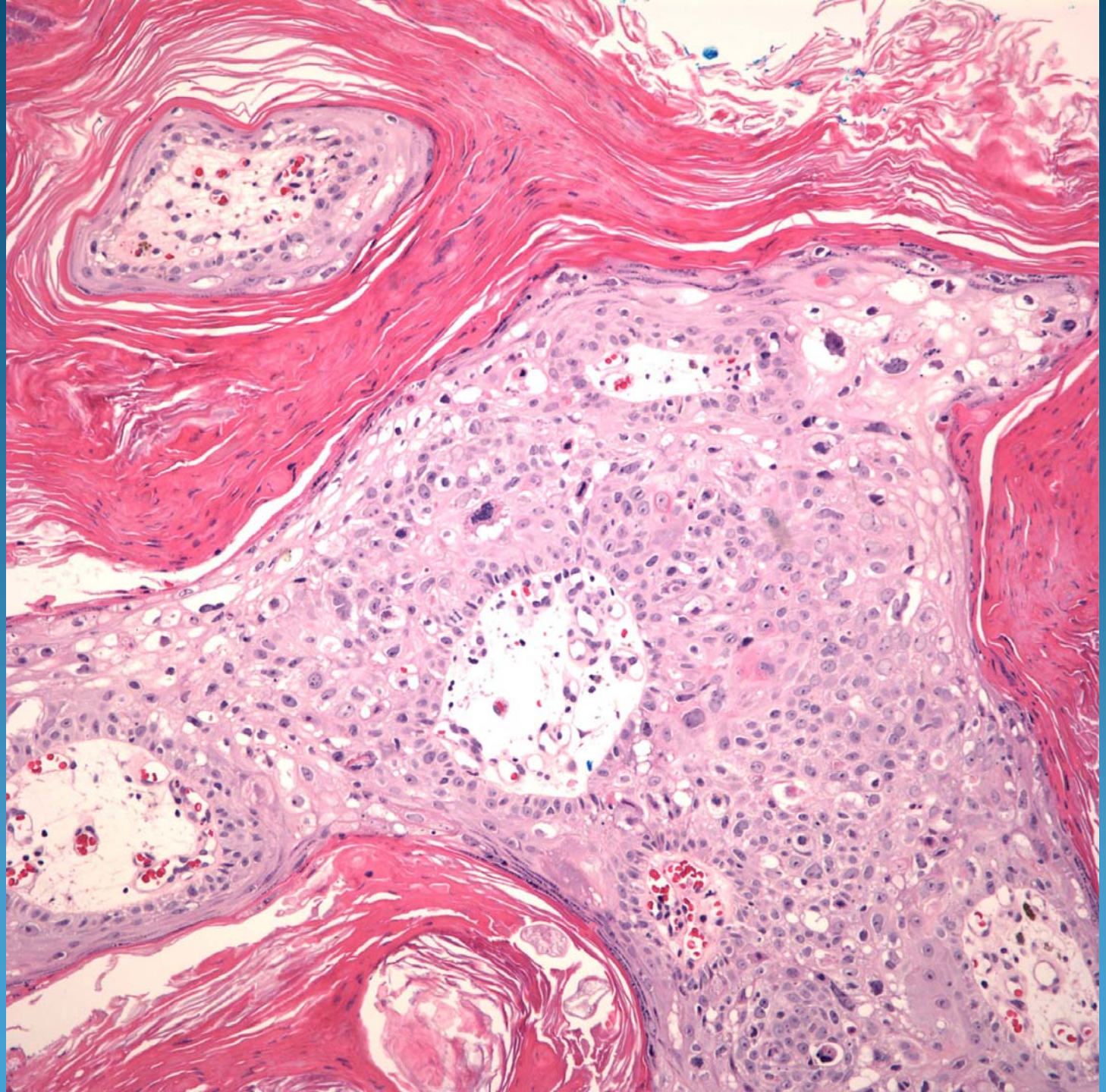

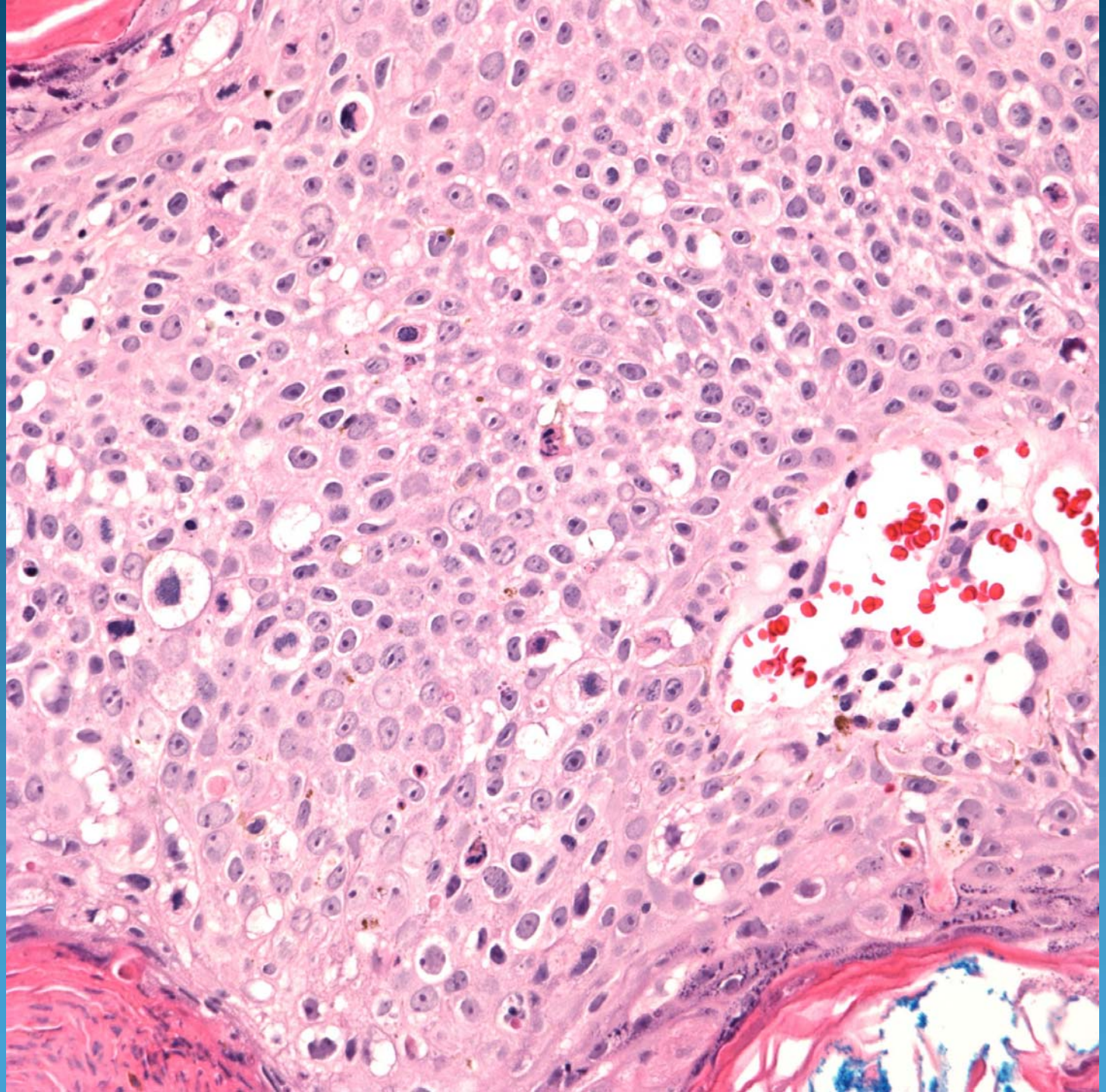

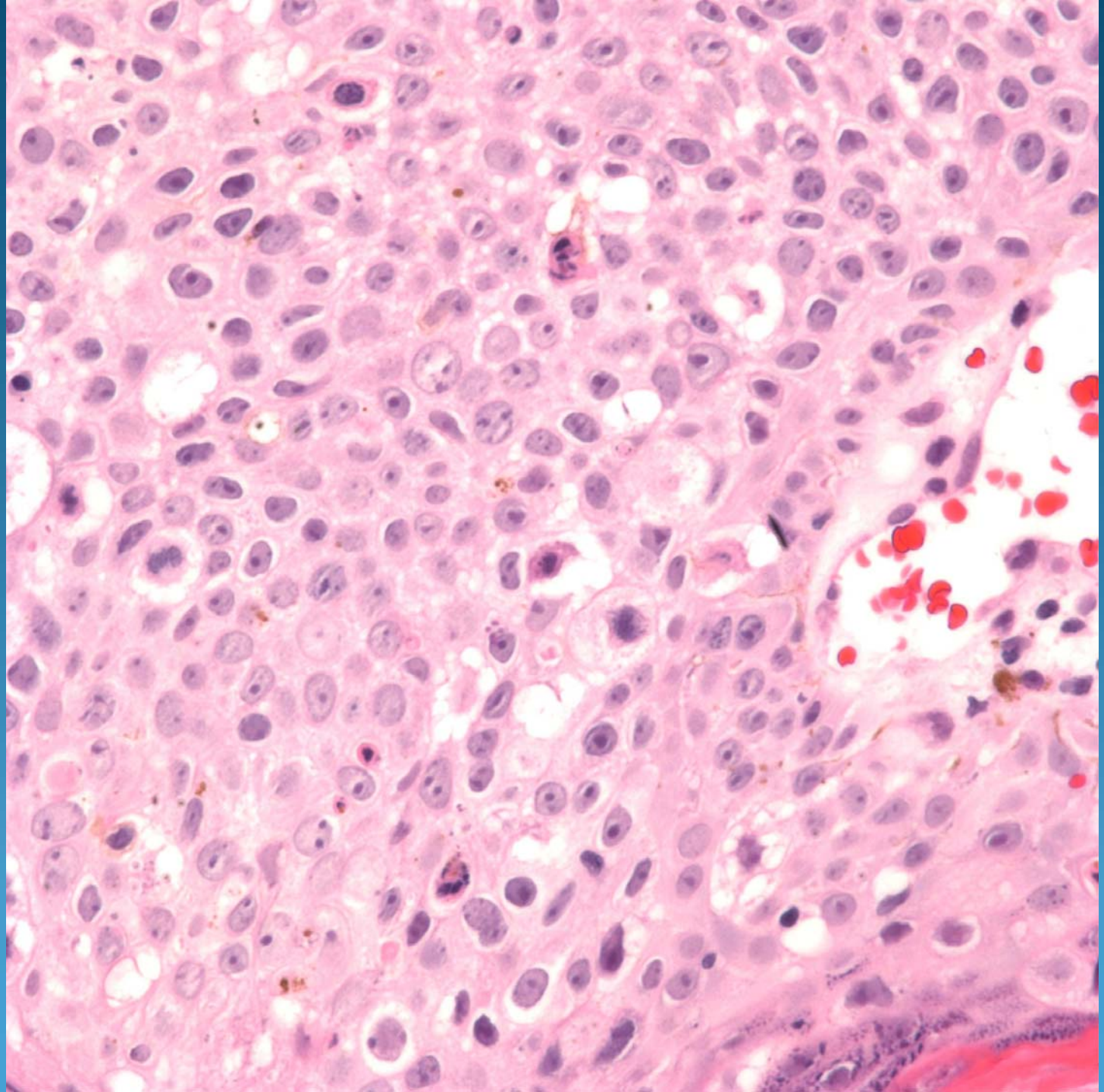

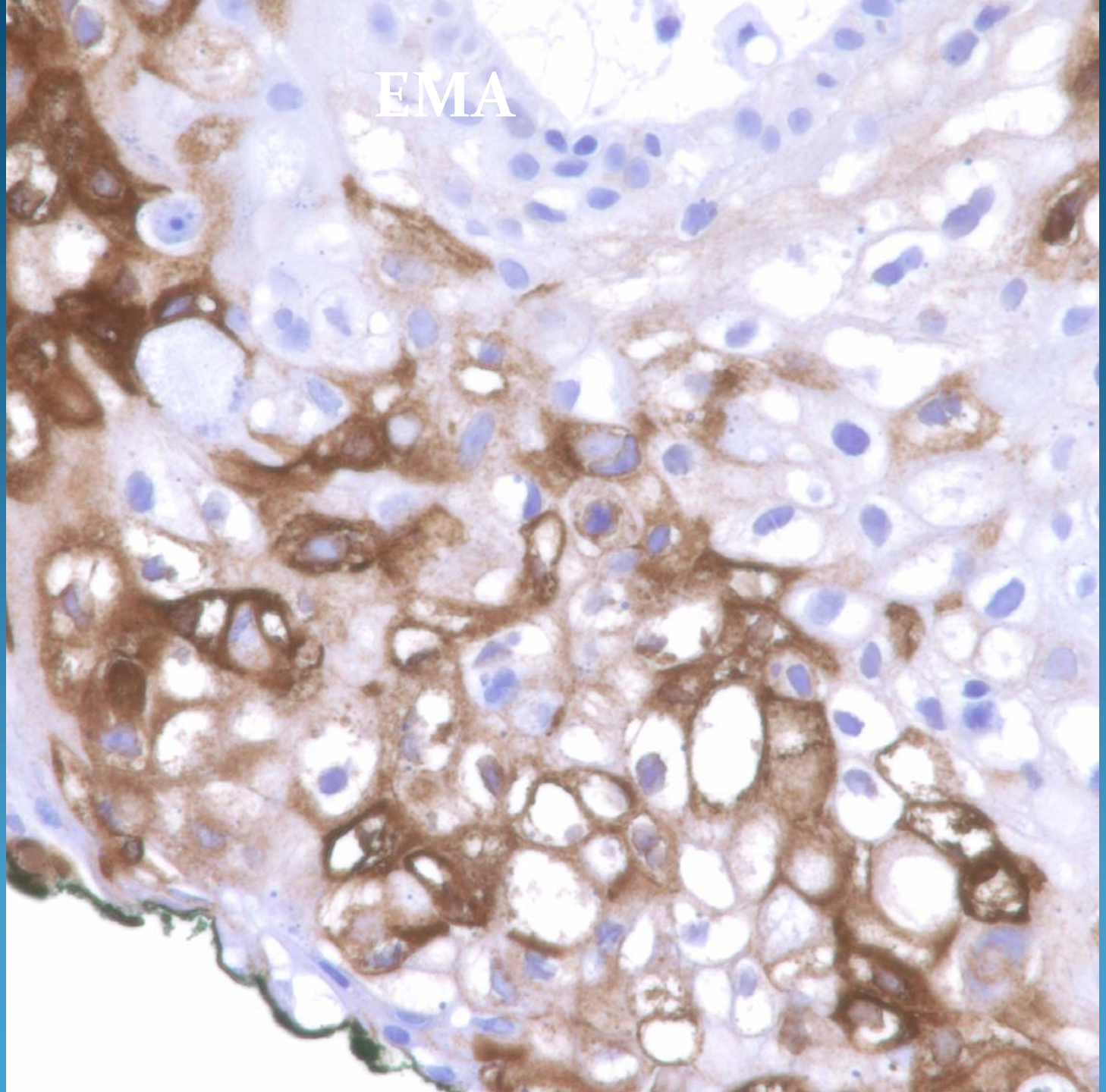
EMA

Sebaceous Carcinoma

Pearls

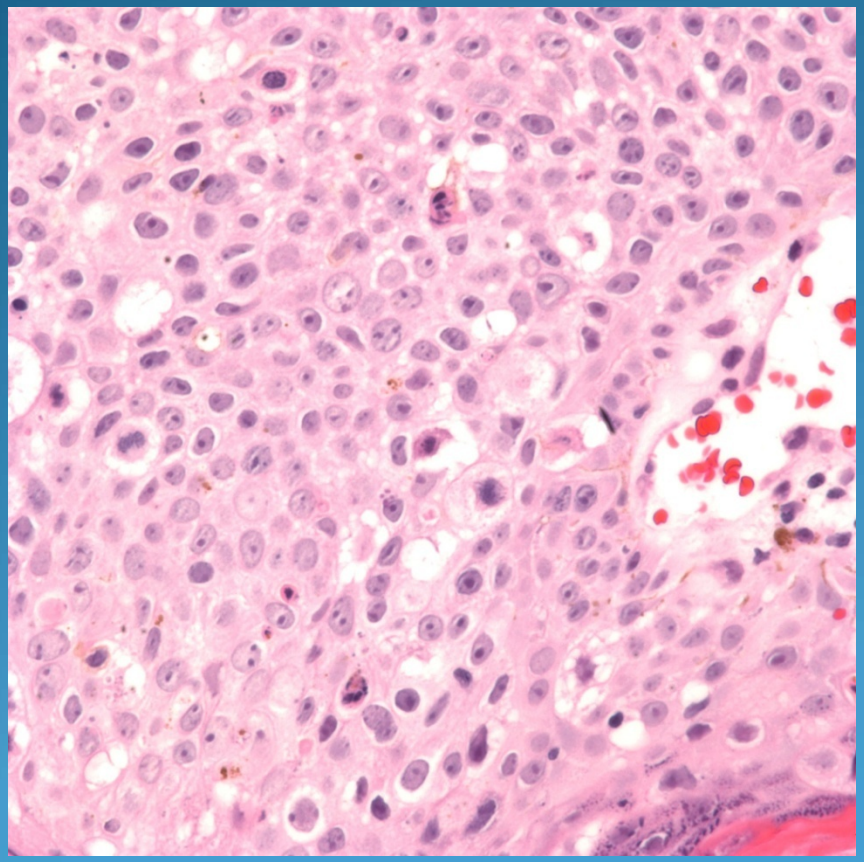

- Cytologically malignant epithelial cells with sebaceous differentiation
- Cytoplasmic vacuoles indenting nuclei
- May confirm with EMA stain
- High clinical suspicion with malignant lesions from the eyelid