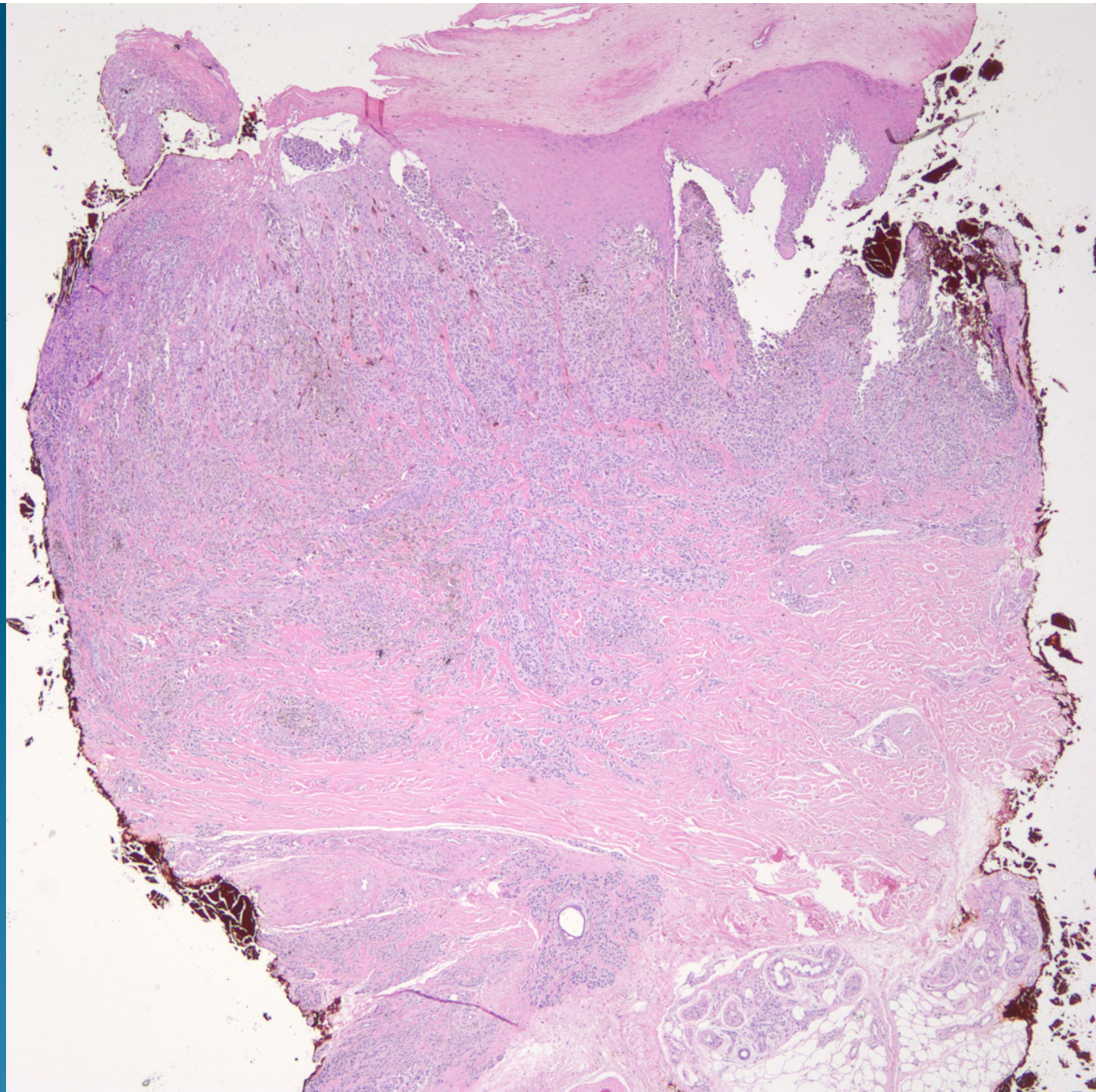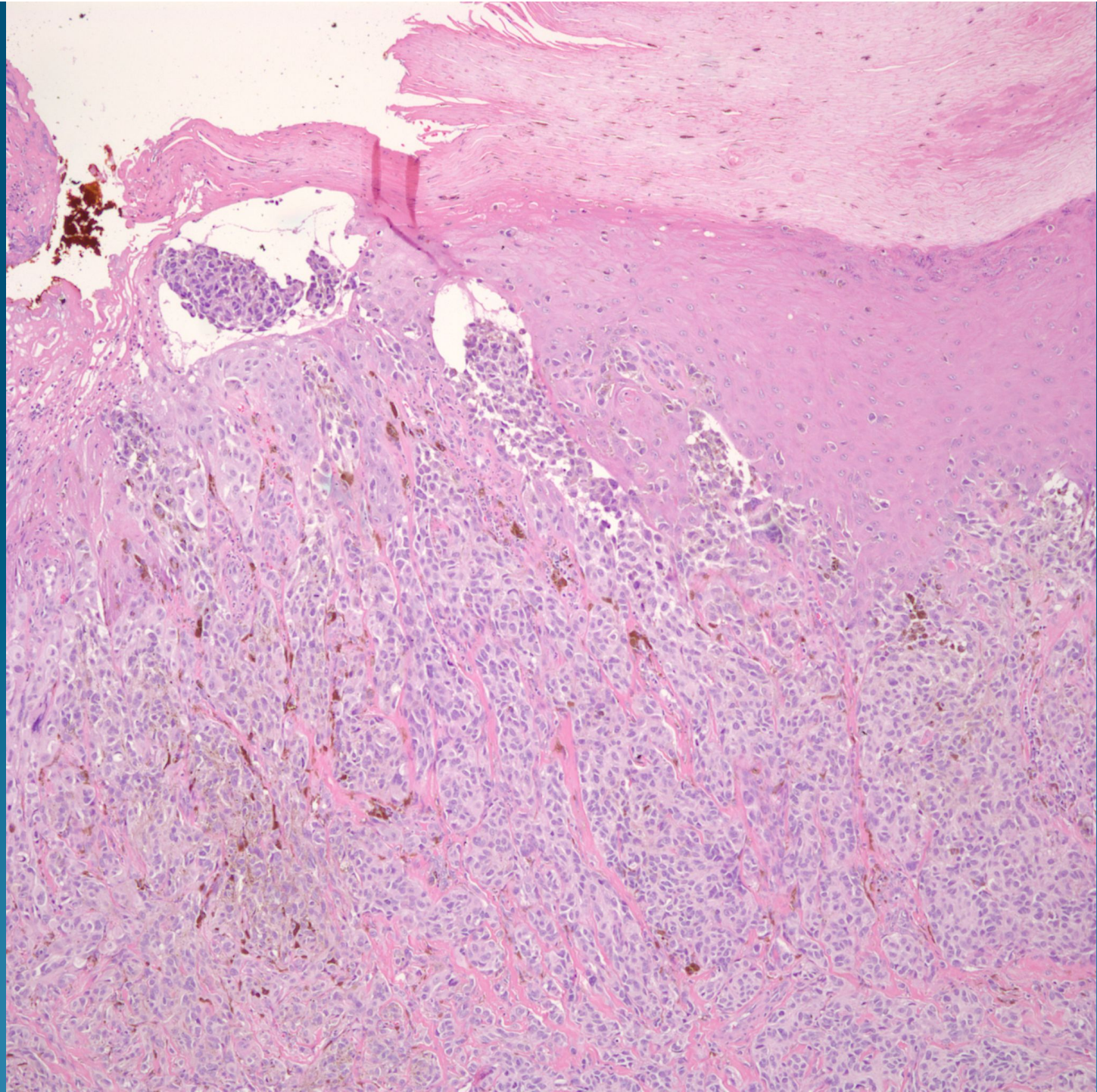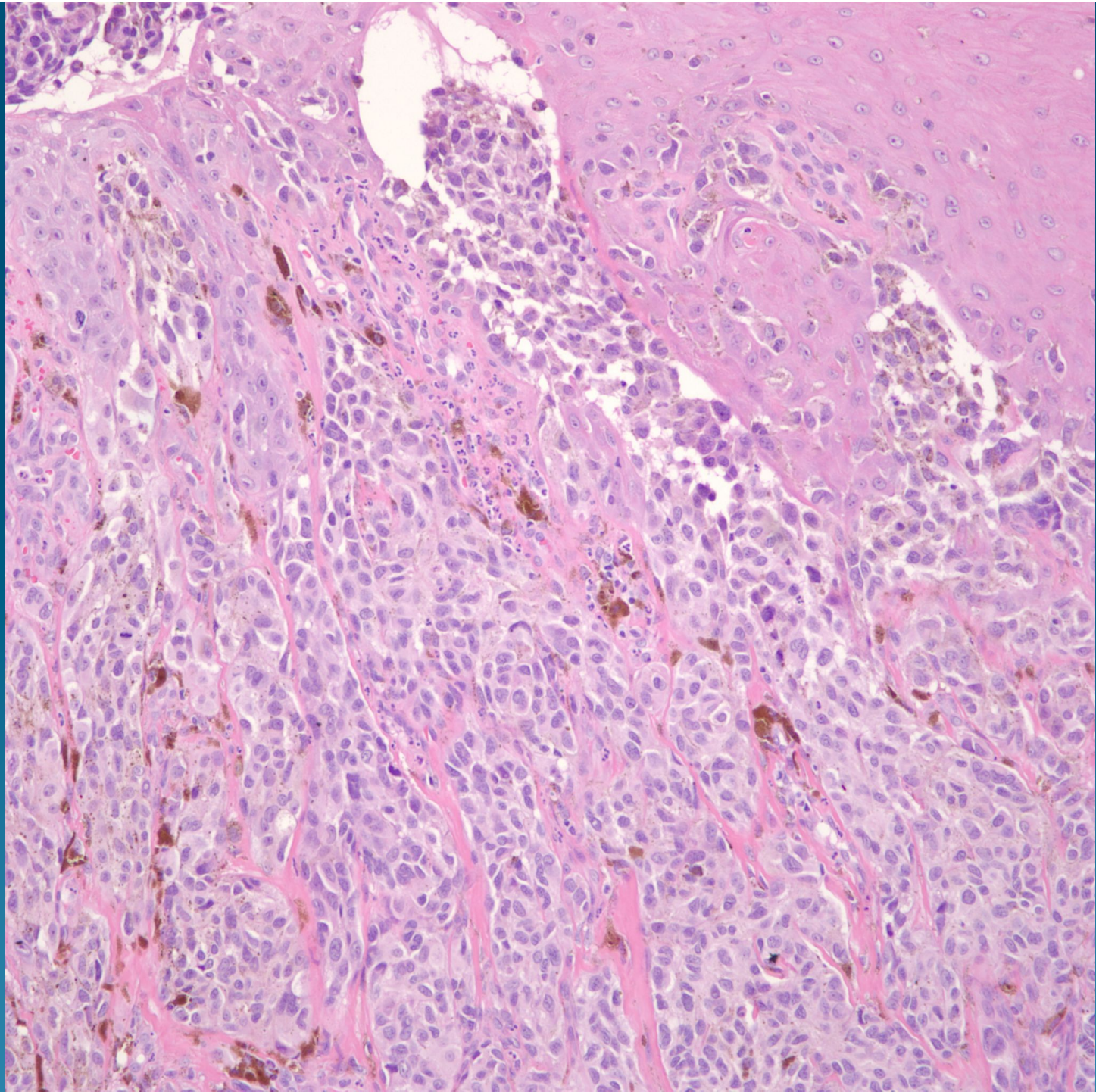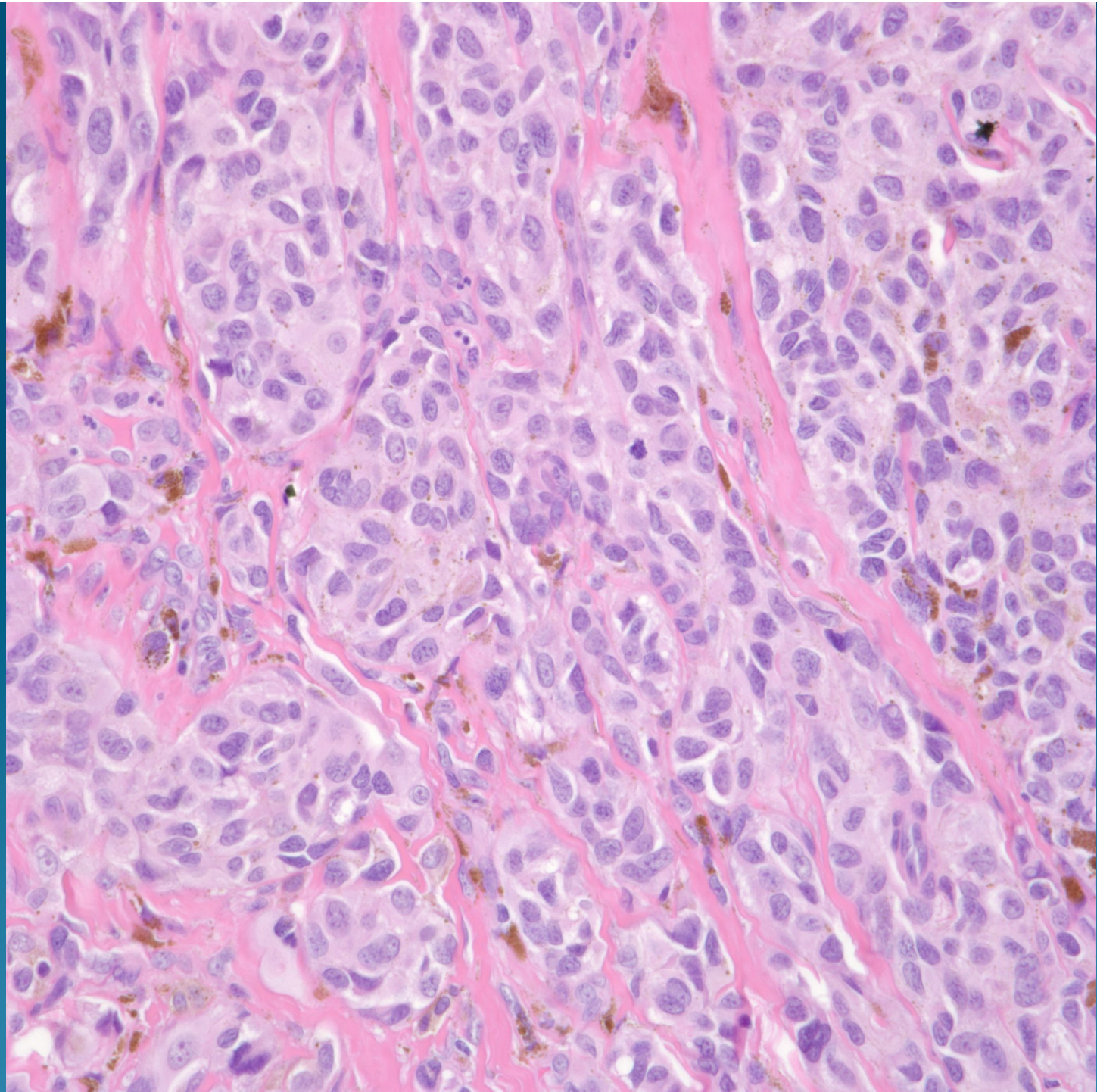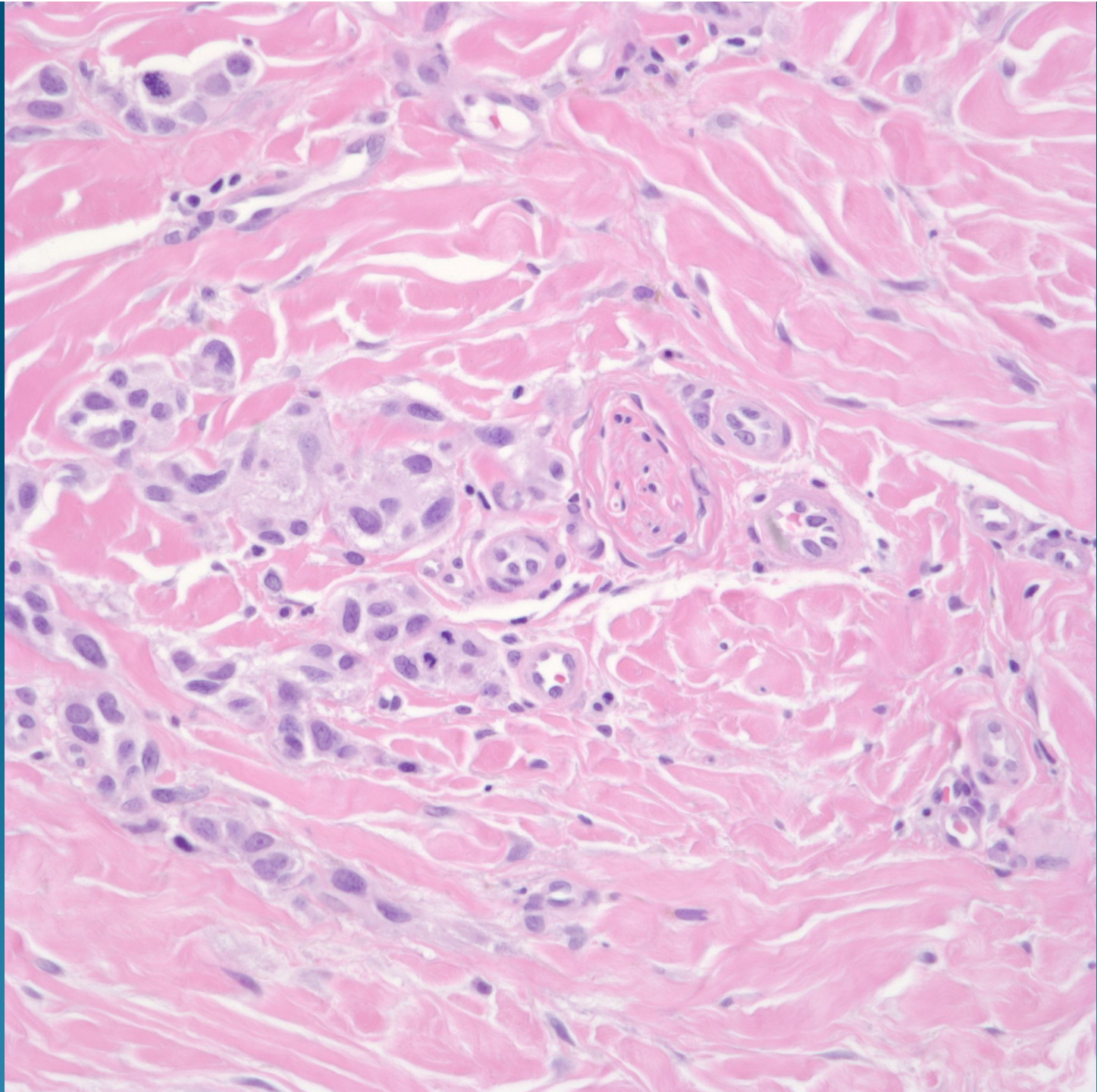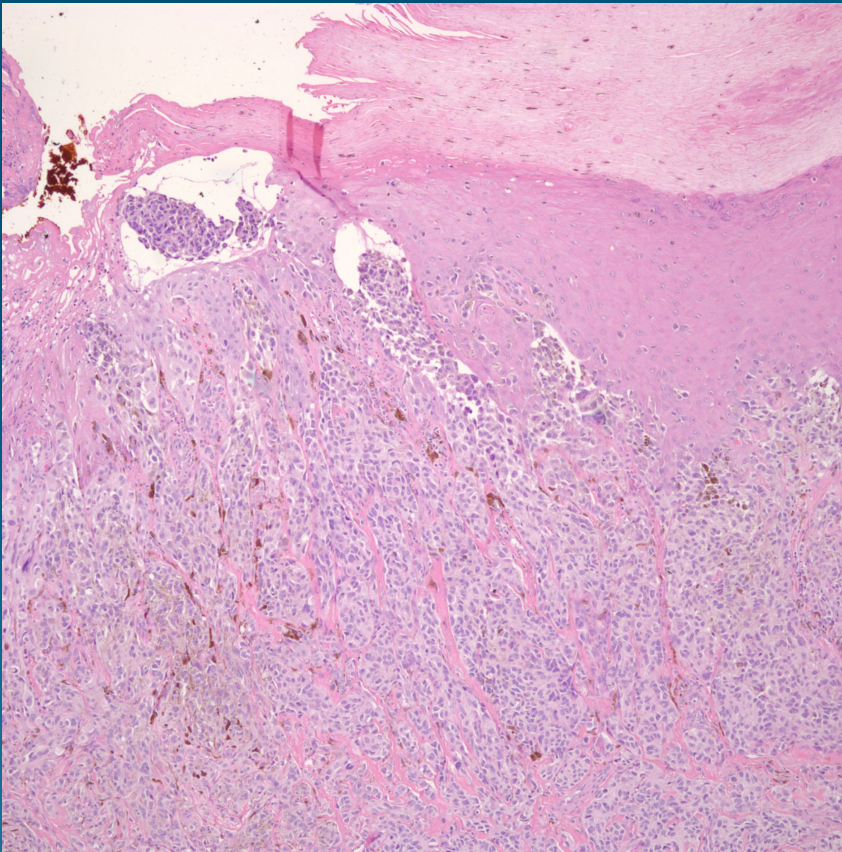


What is the best diagnosis?

- A. Spitz nevus
- B. Blue nevus
- C. Pigmented eccrine poroma
- D. Bednar tumor
- E. Malignant melanoma

Acral Malignant Melanoma

Pearls



- Look for acral location
- Spindled desmoplastic changes common
- Perineural invasion common
- Mitotic figures easily identified