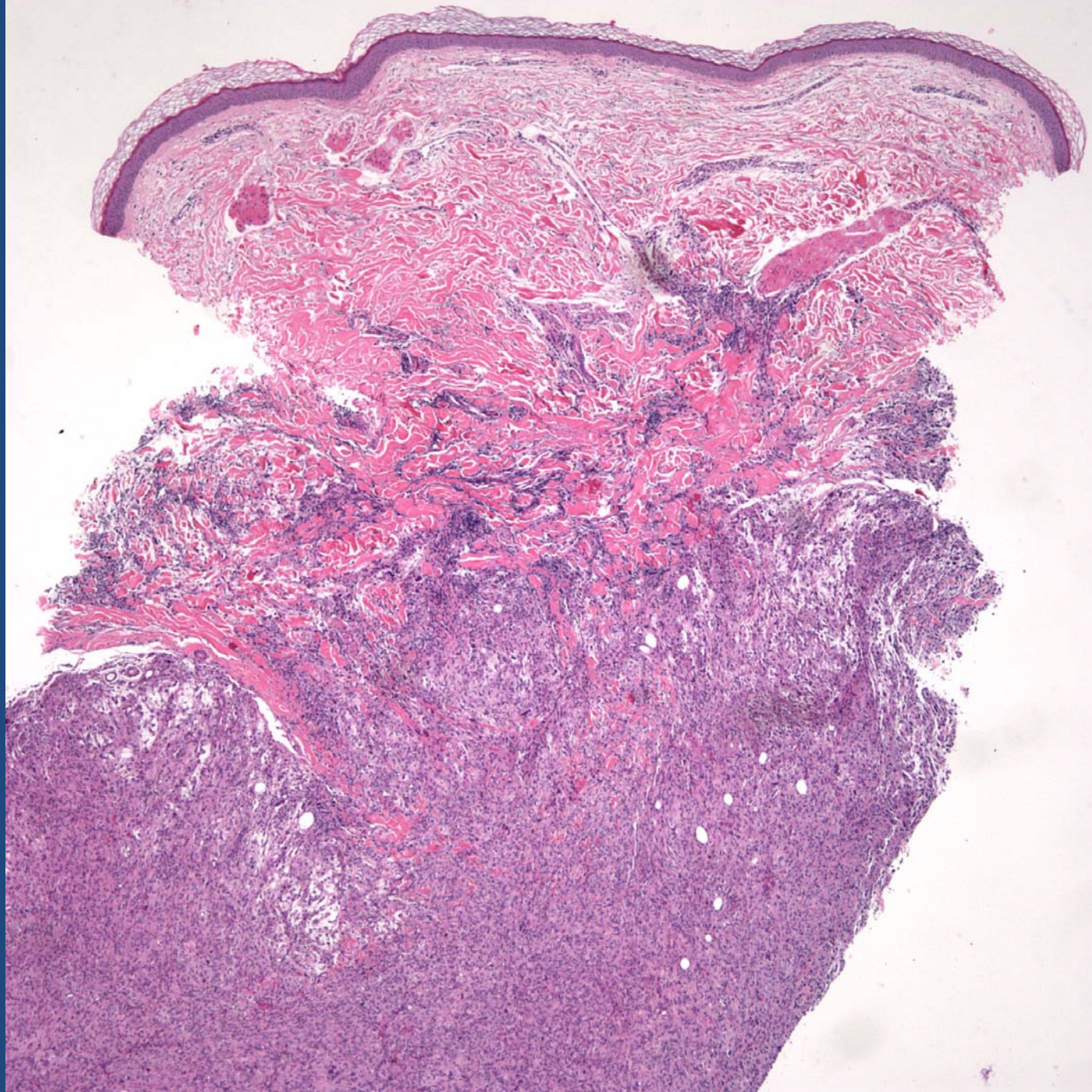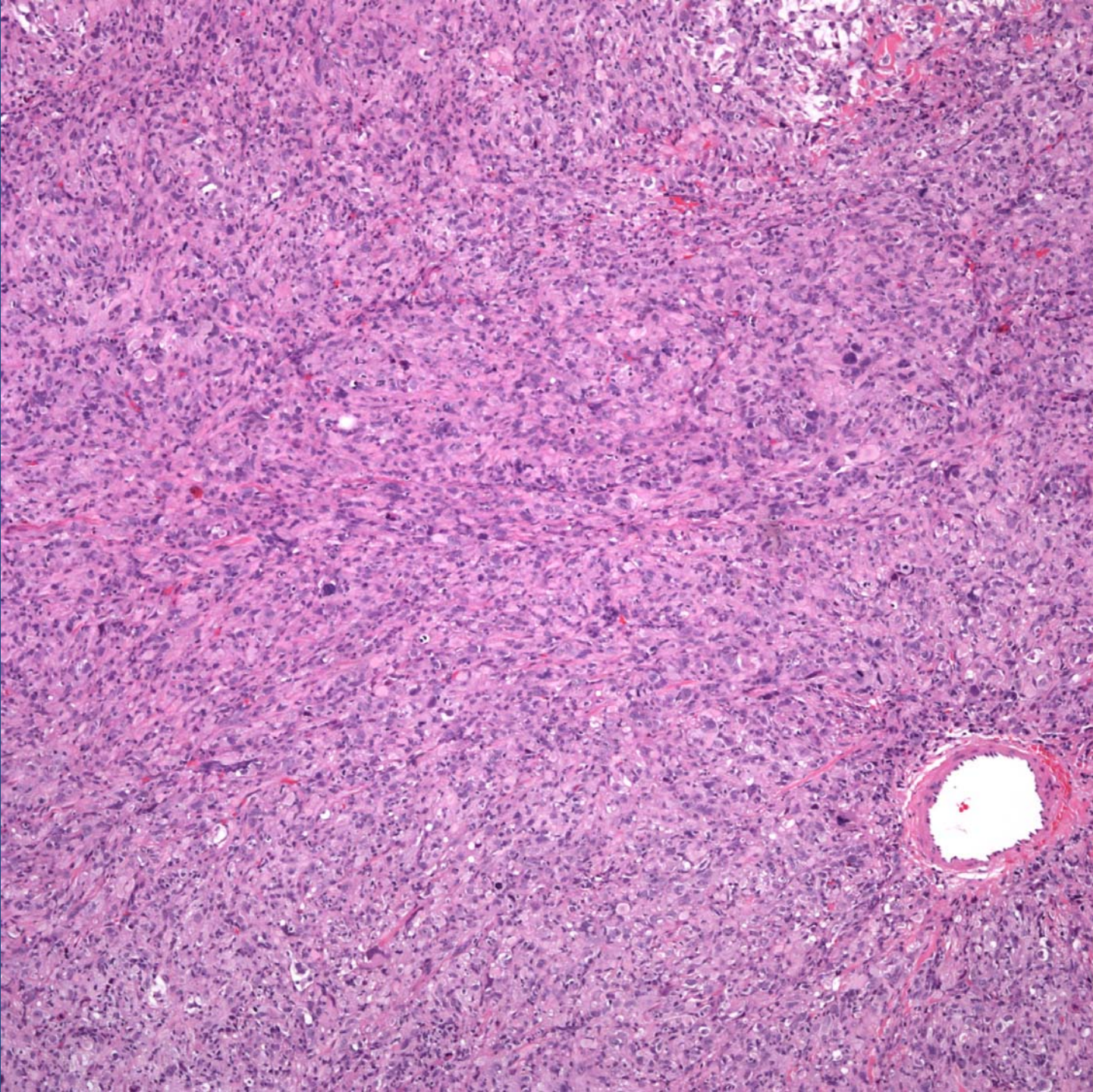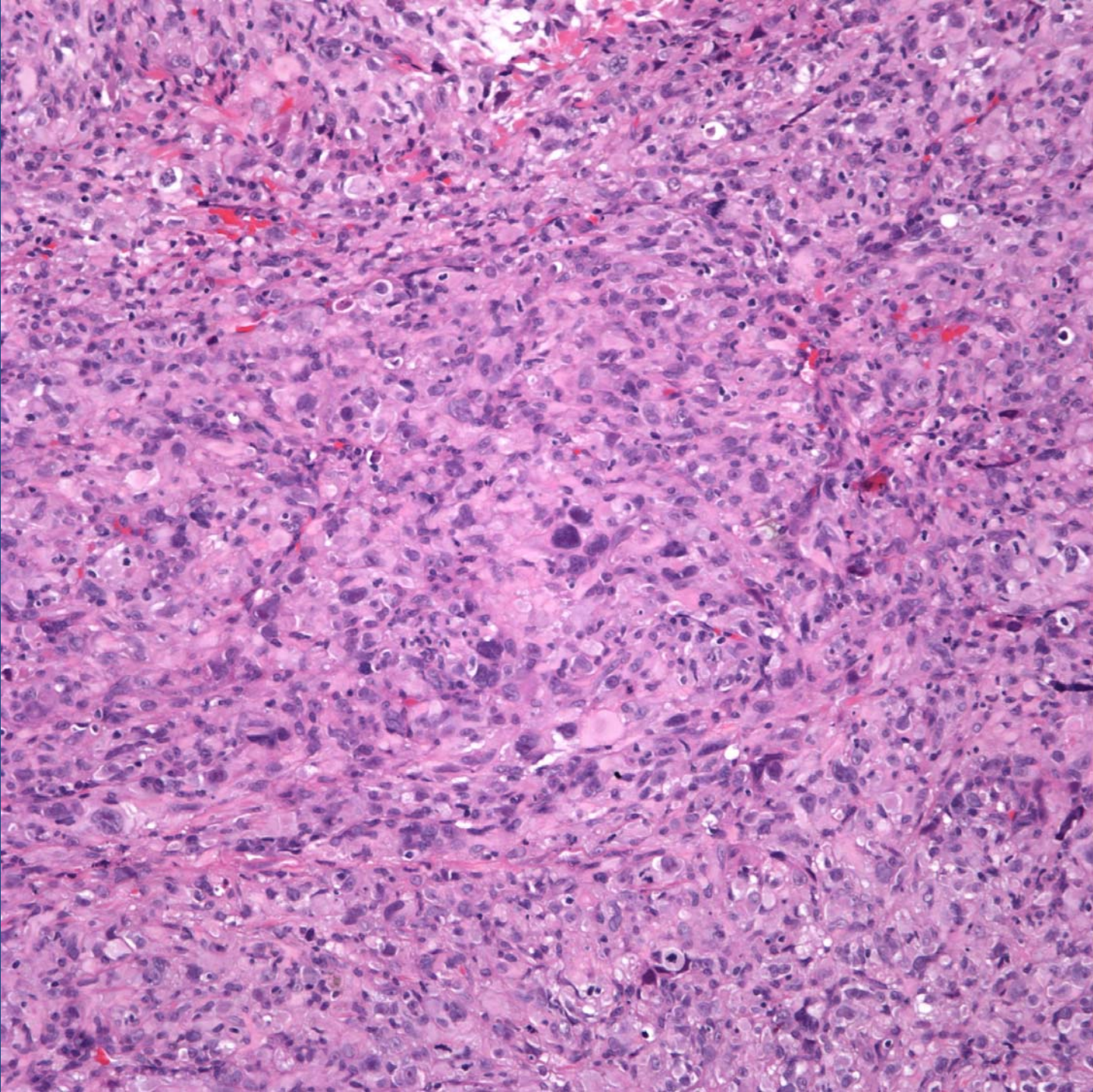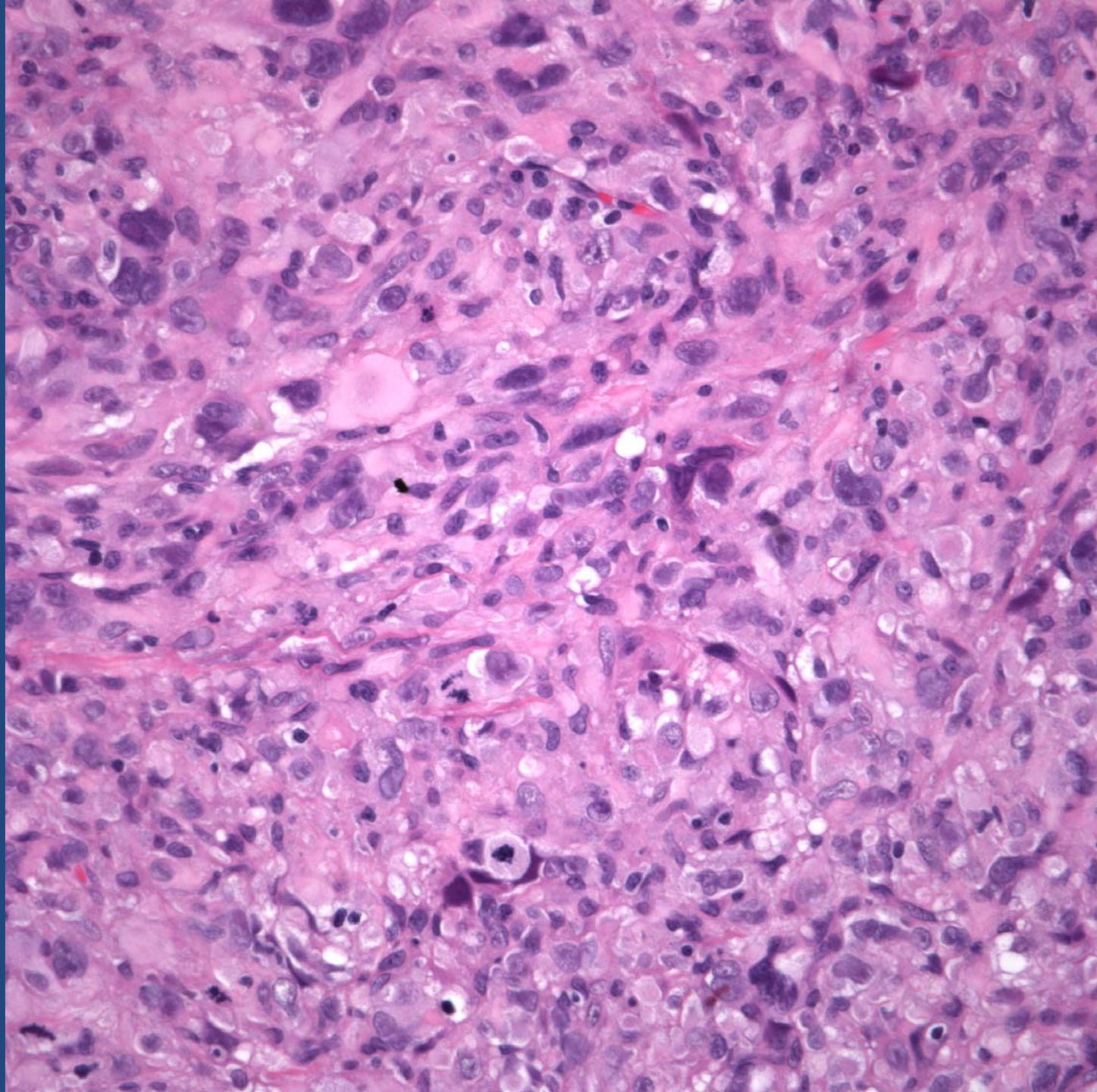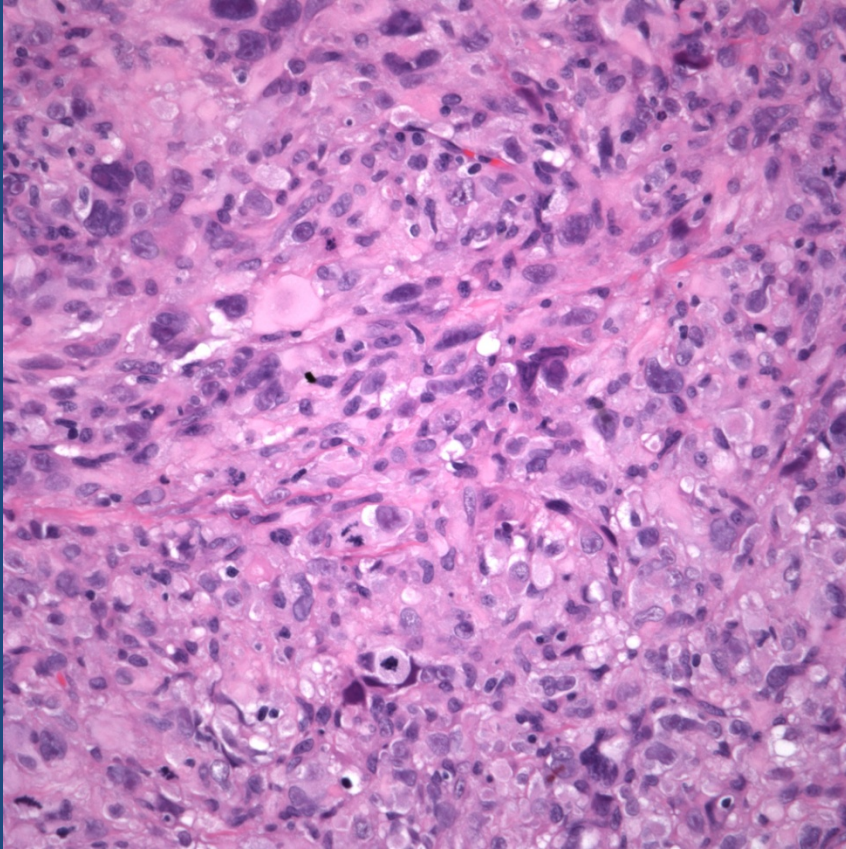


Atypical Fibroxanthoma
Rule out Malignant Fibrous
Histiocytoma invading the dermis

Pearls



- Cytologically malignant spindle cell neoplasm
- May have prominent storiform configuration
- IHC workup to rule out histologic mimics (carcinoma, melanoma, sarcoma, etc)
- Deep seated tumors, rule out soft tissue MFH extending into dermis