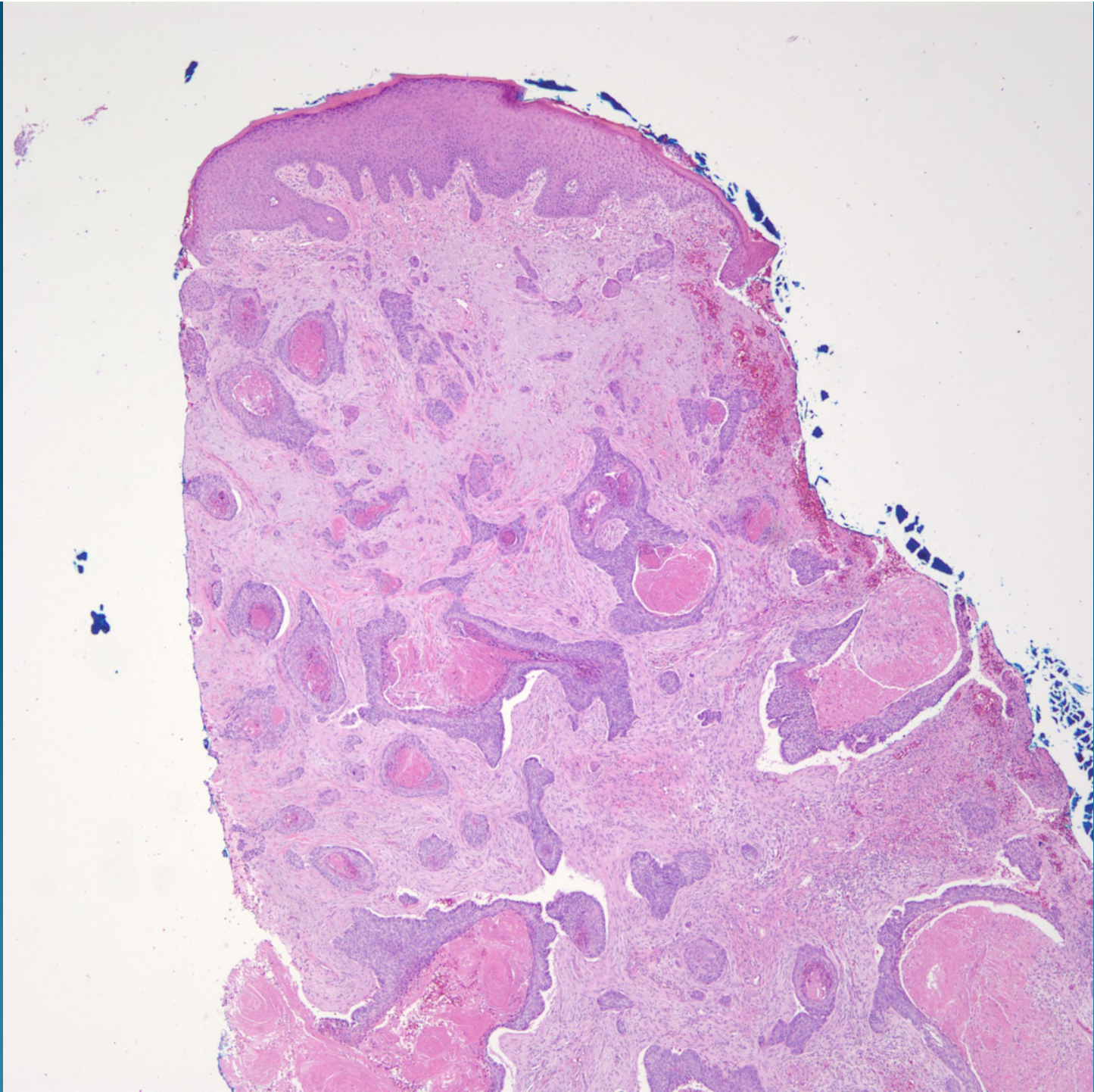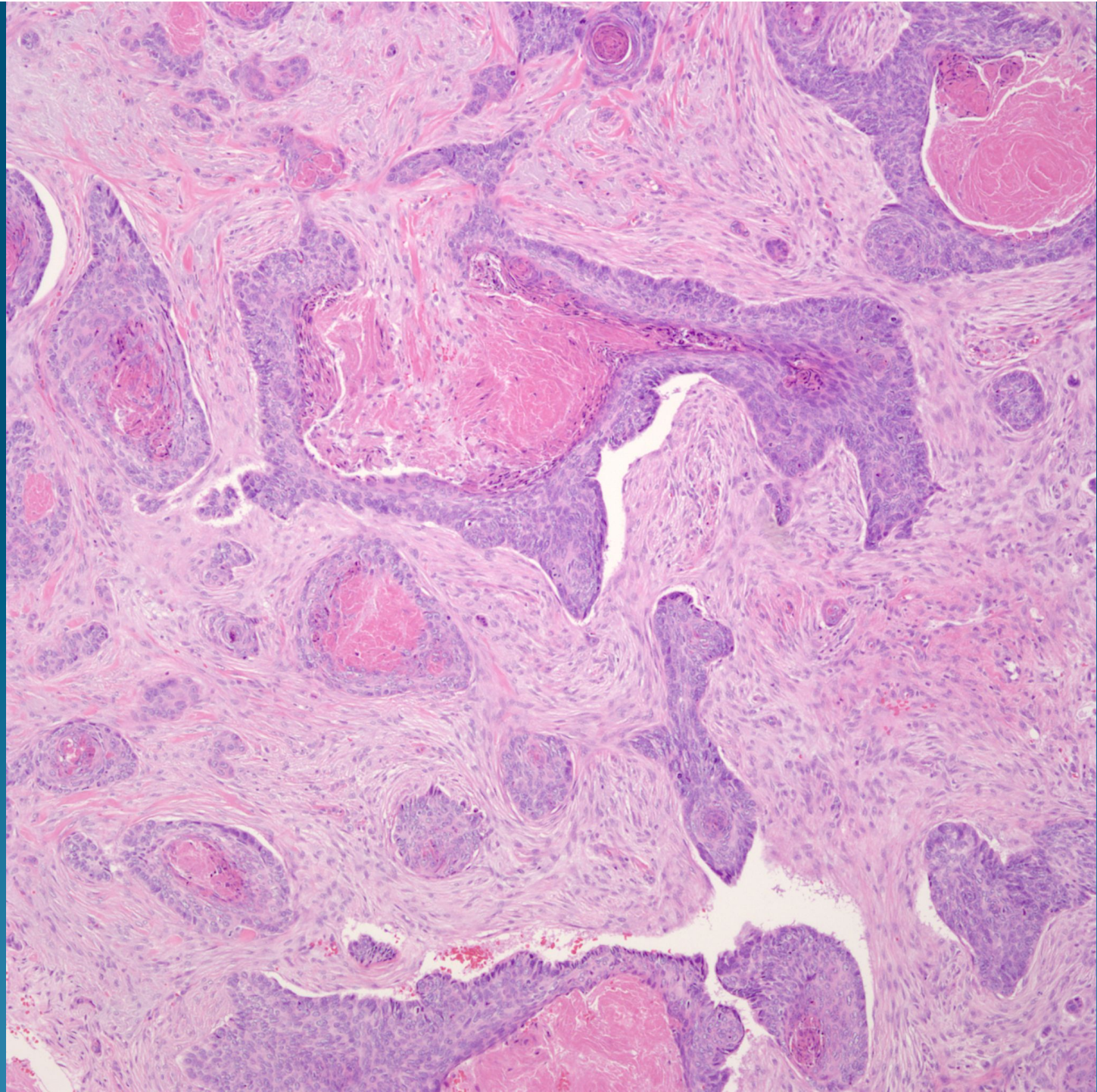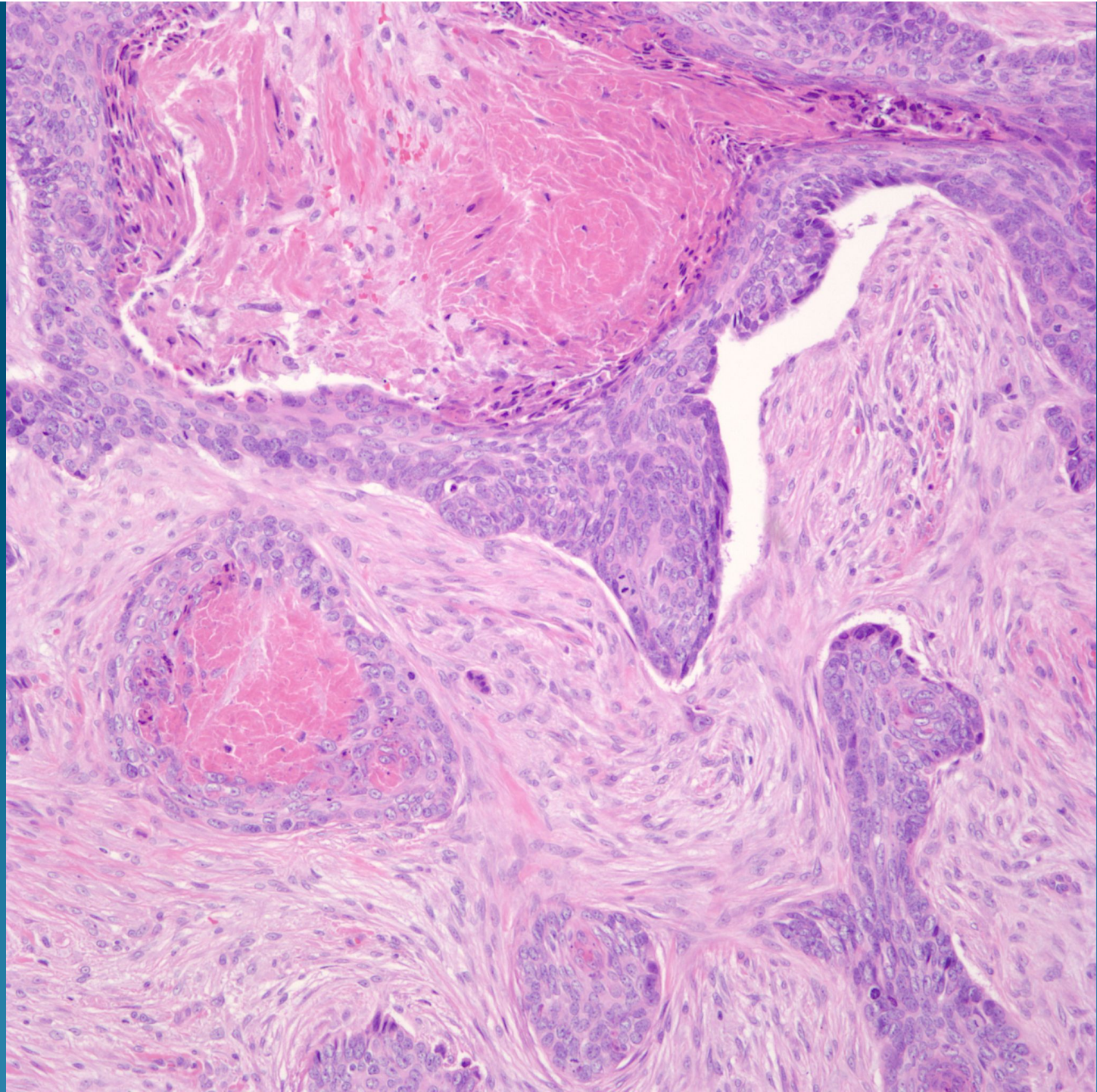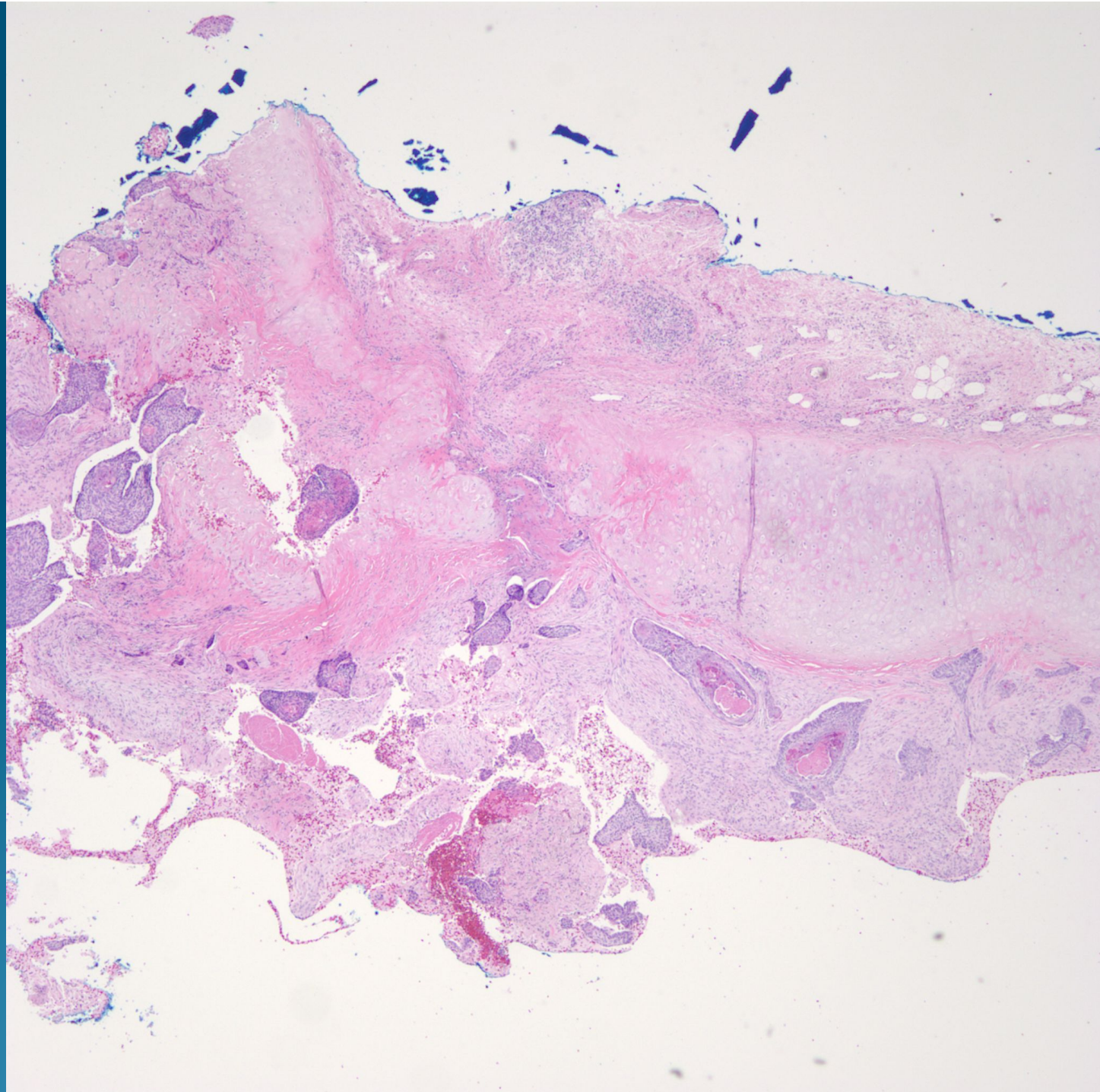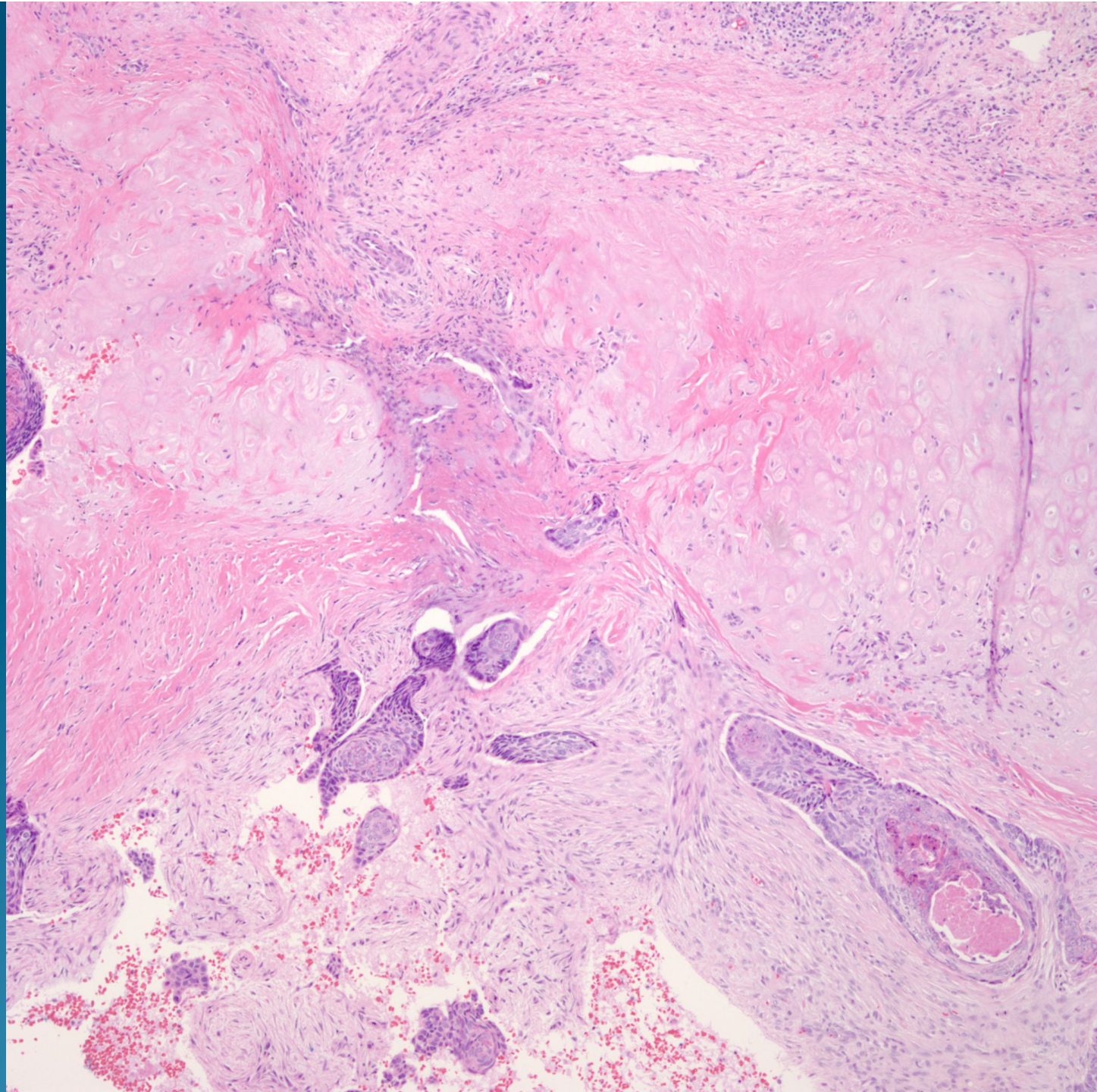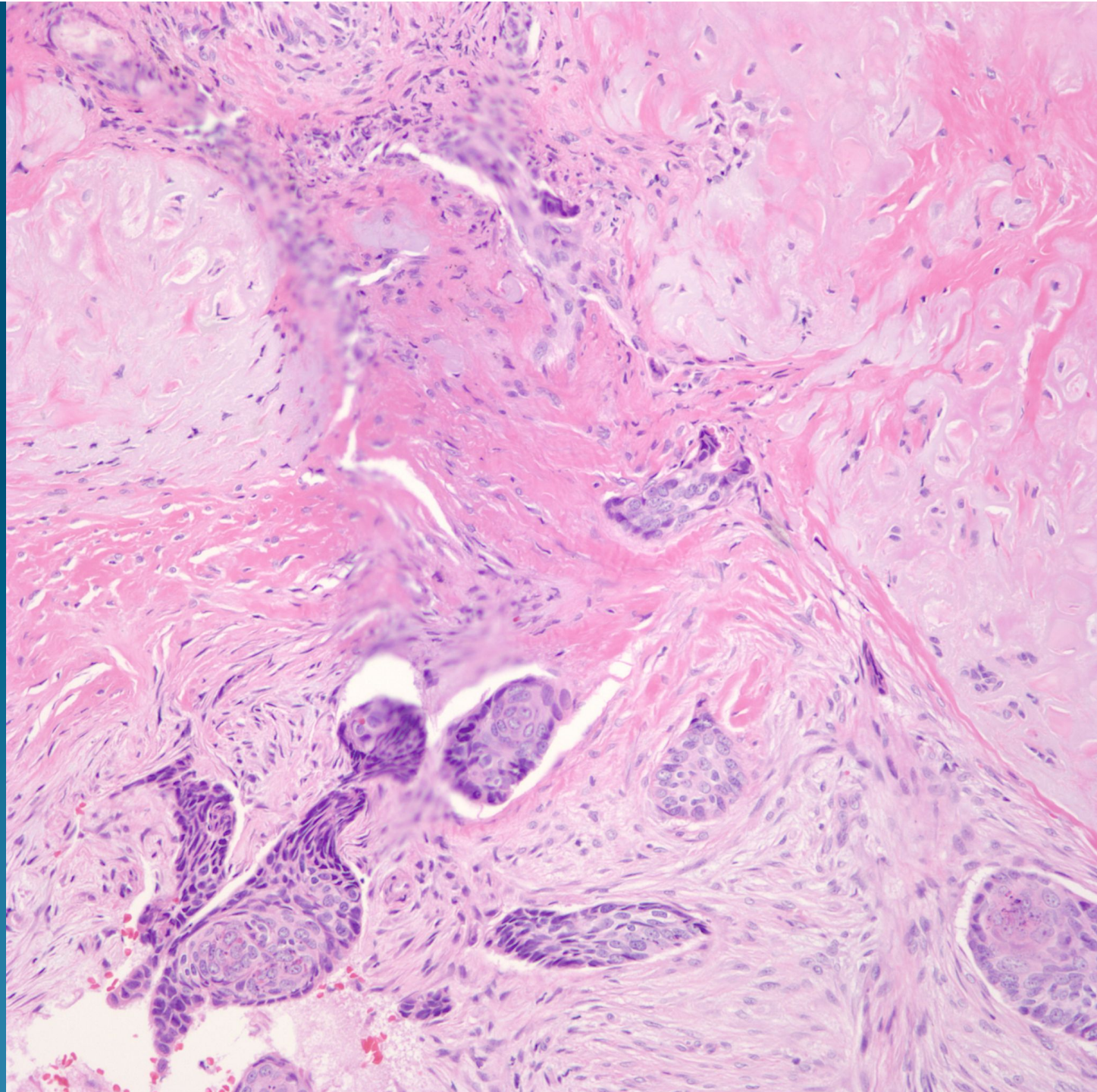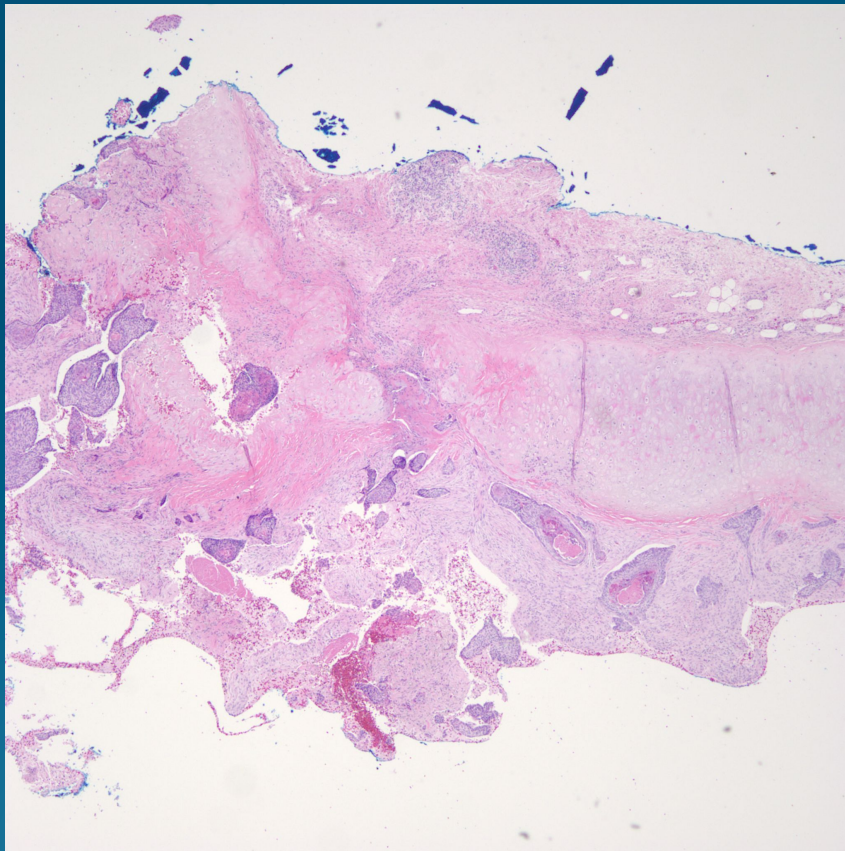


What is the best diagnosis?

- A. Collision tumor between basal cell carcinoma and chondrosarcoma
- B. Metatypical Basal cell carcinoma with cartilaginous differentiation
- C. Malignant cutaneous mixed tumor
- D. Metatypical basal cell carcinoma with invasion into cartilage
- E. Basaloid carcinoma arising from salivary gland

Metatypical basal cell carcinoma
with invasion into cartilage

Pearls



- Basal cell carcinoma with squamous differentiation
- Usually aggressive or infiltrative basal cell carcinoma pattern
- Depending upon location, may see cartilage in the margin