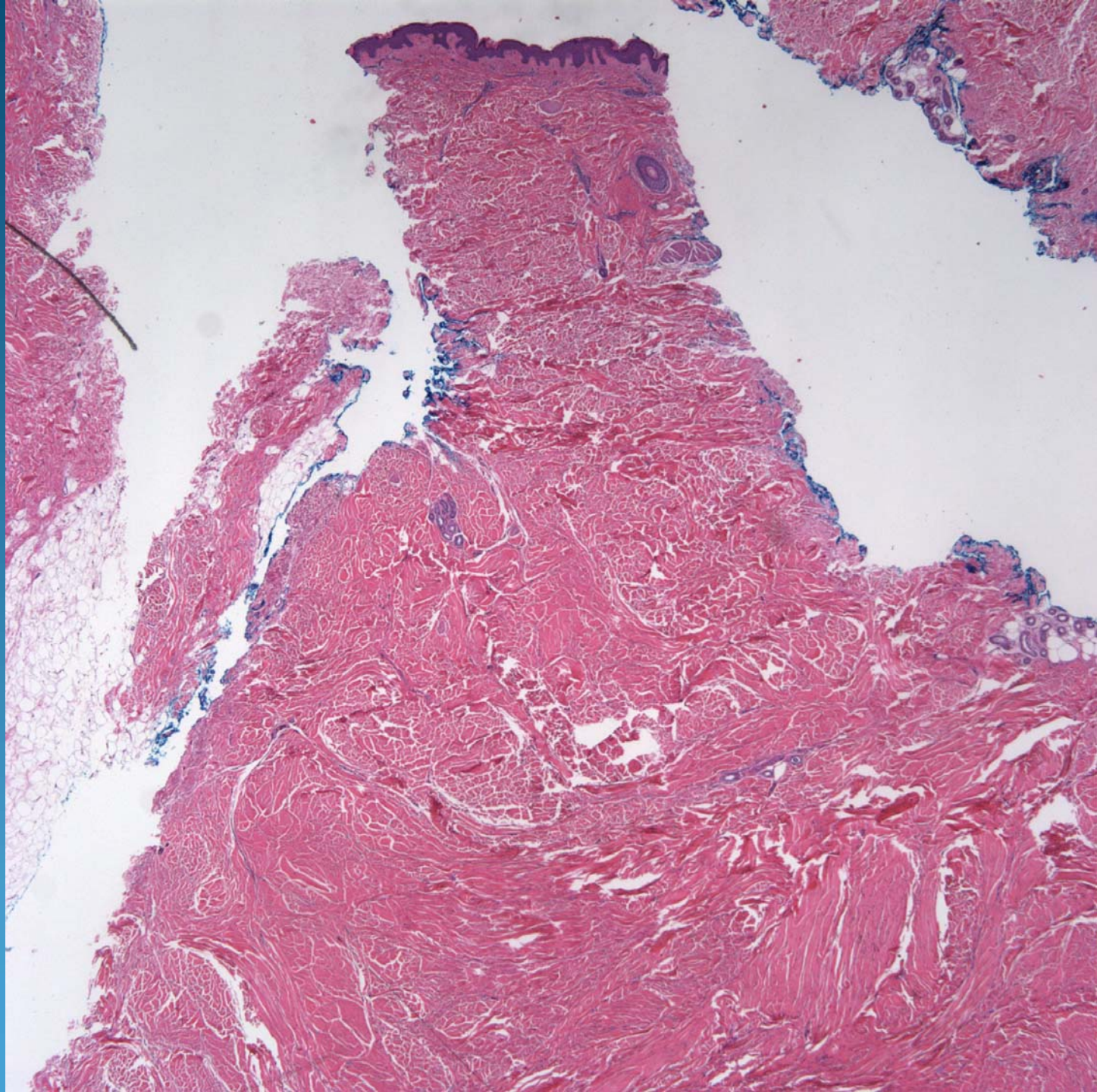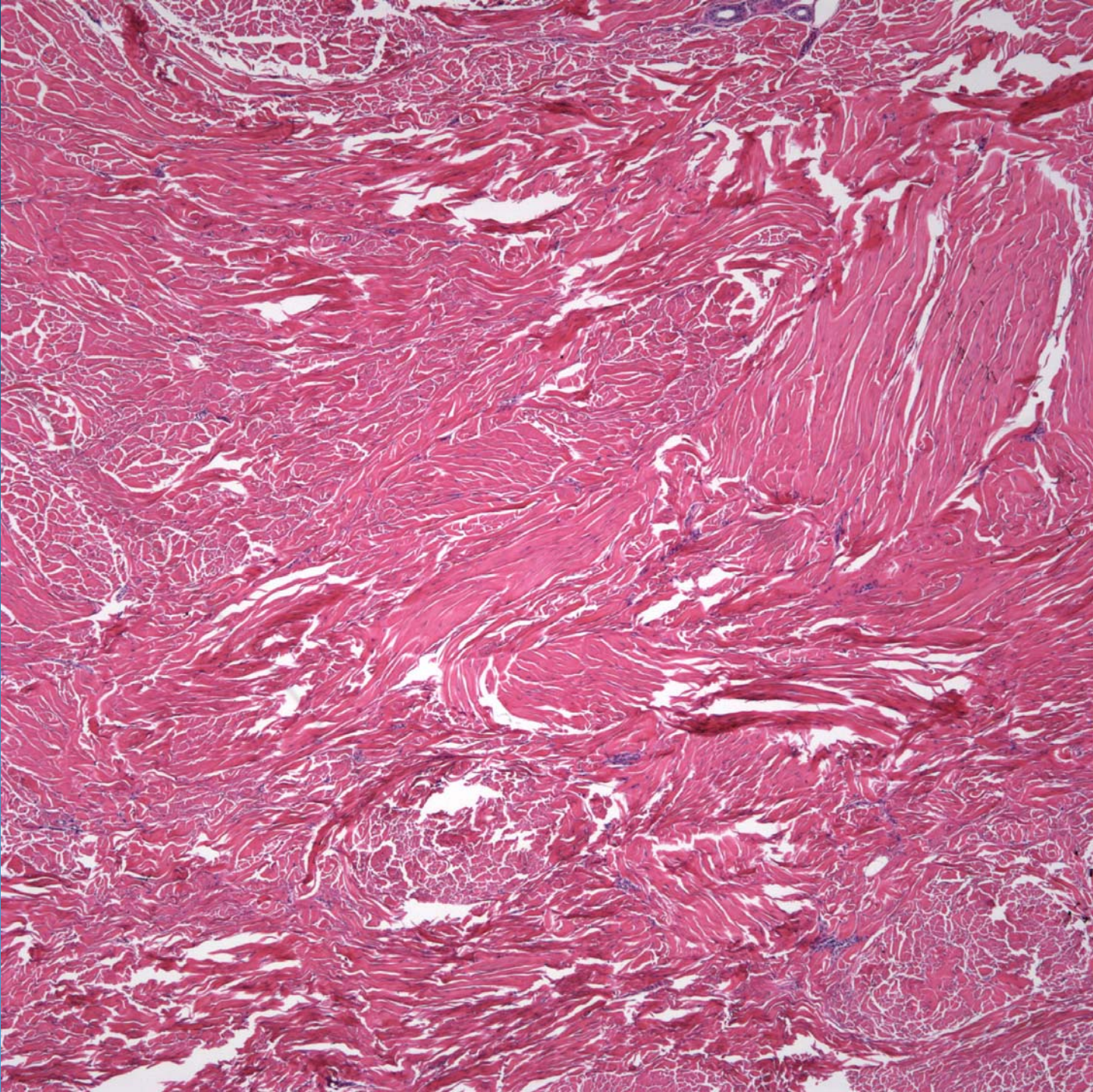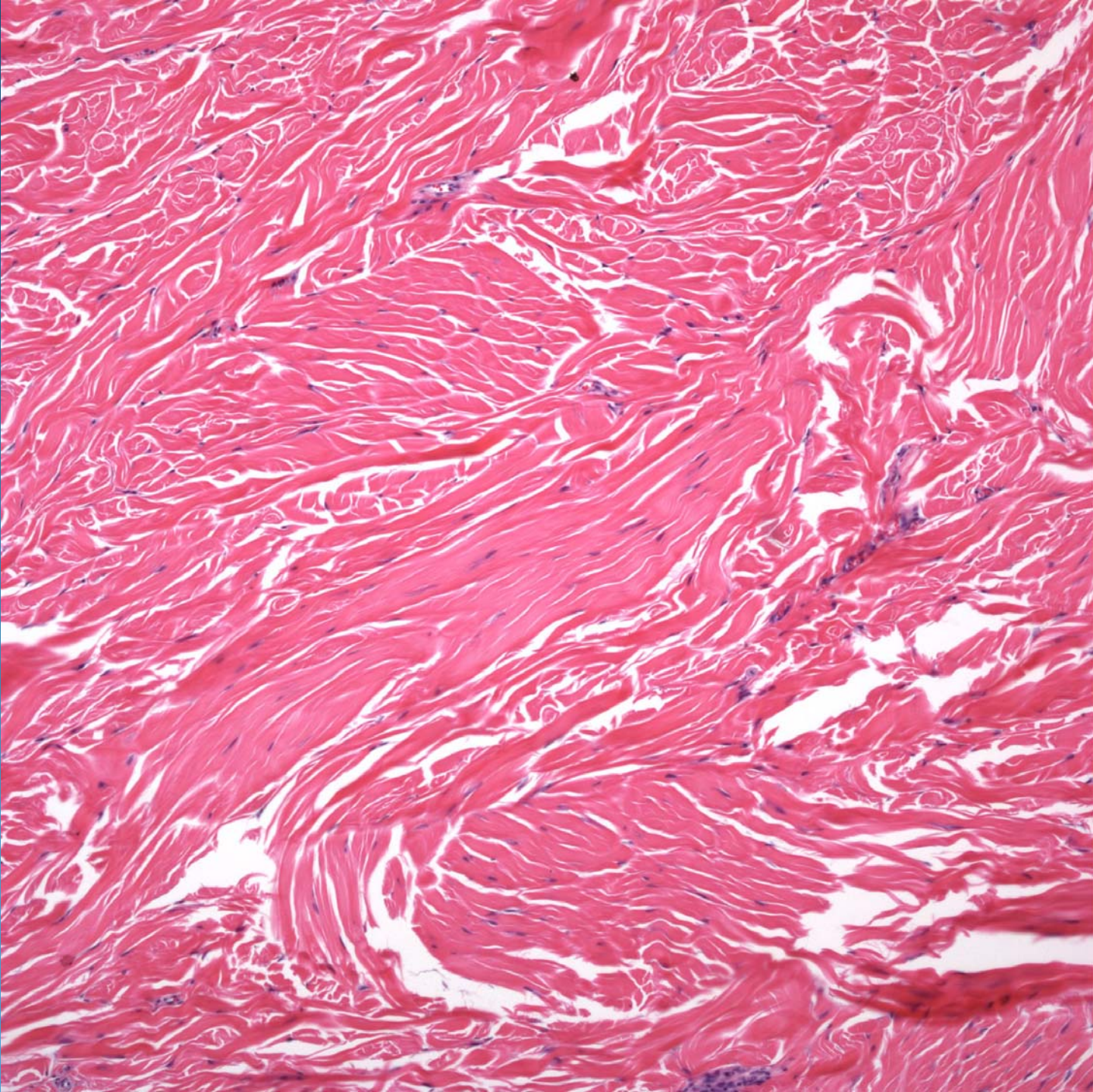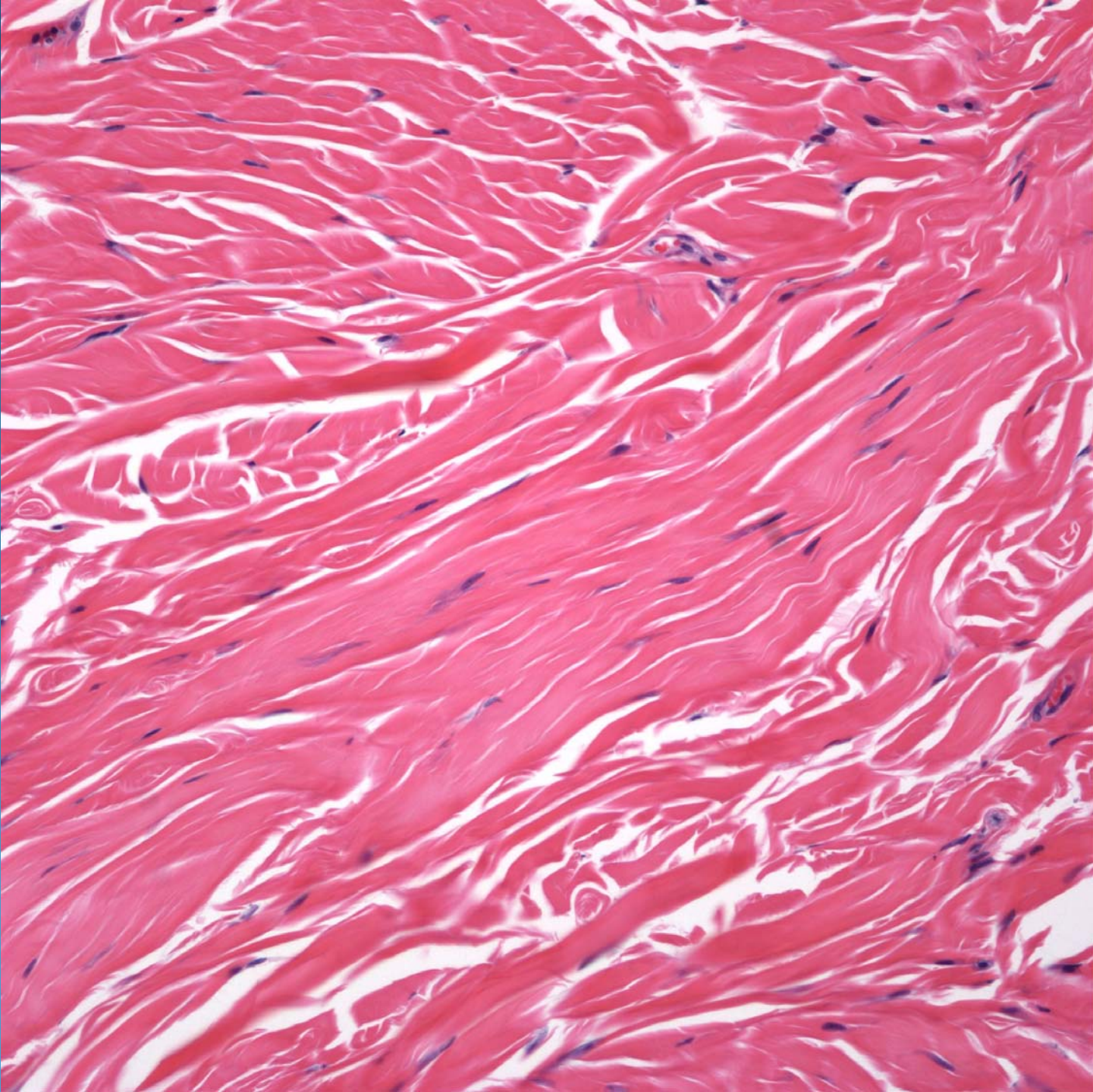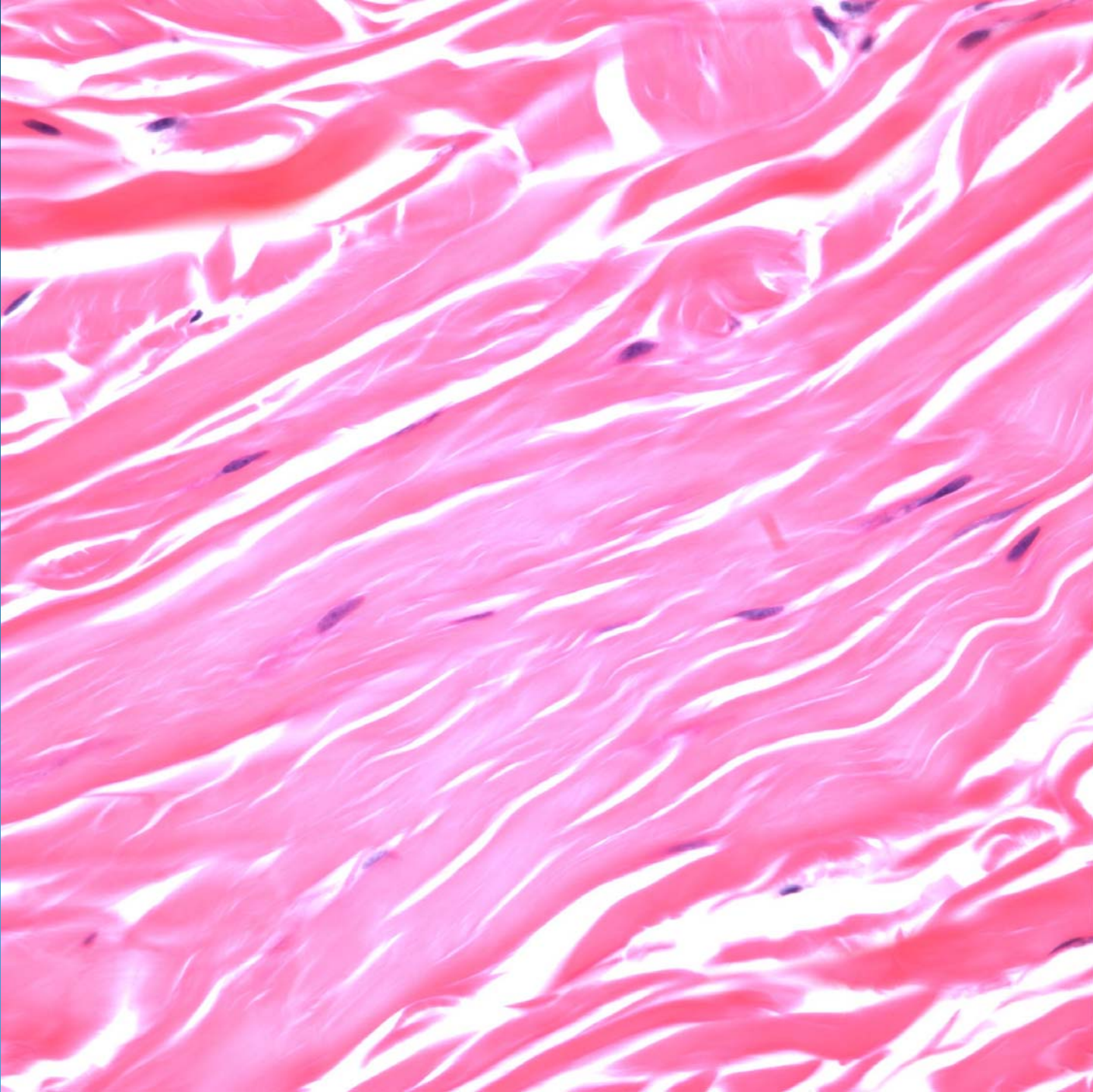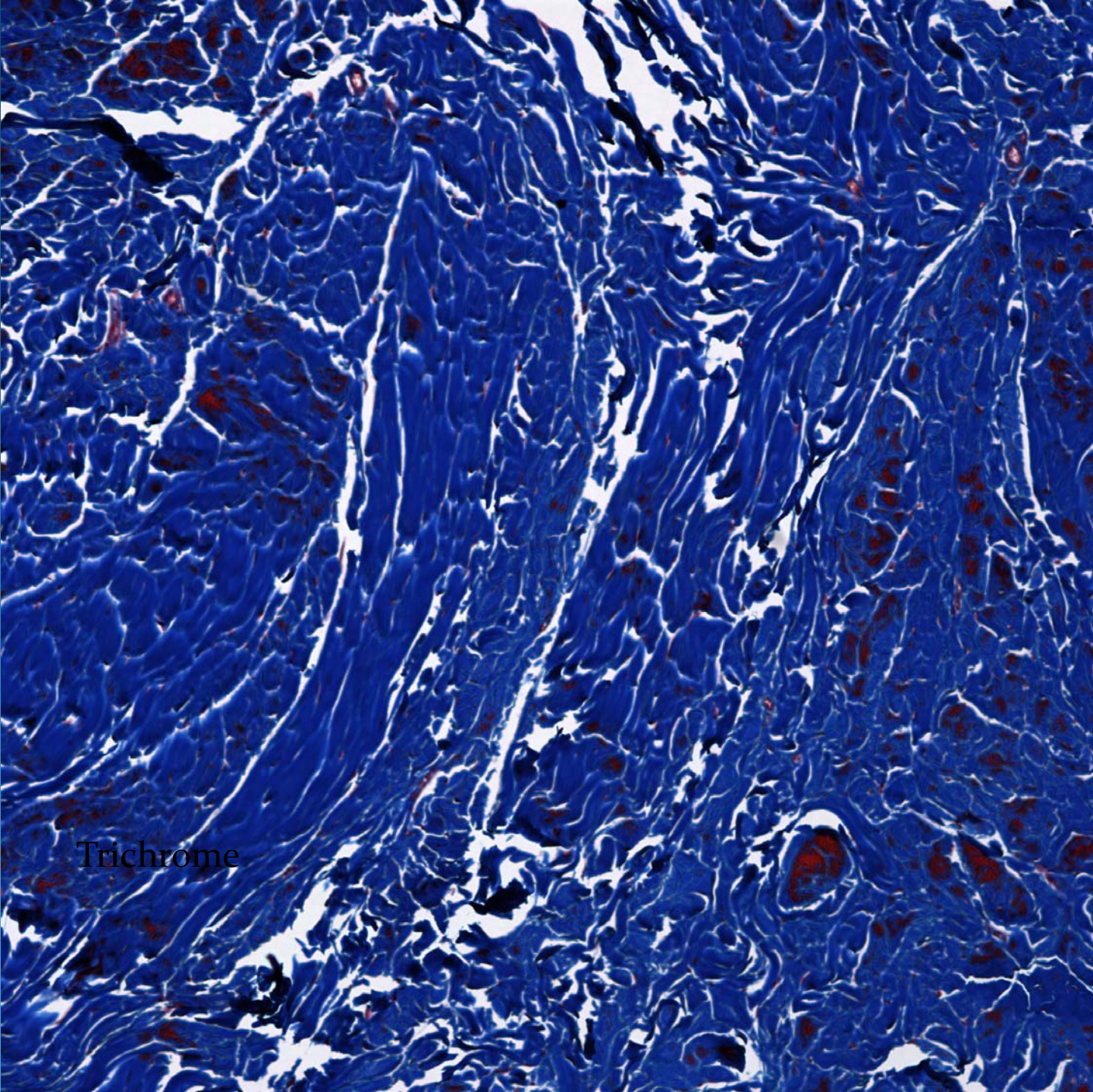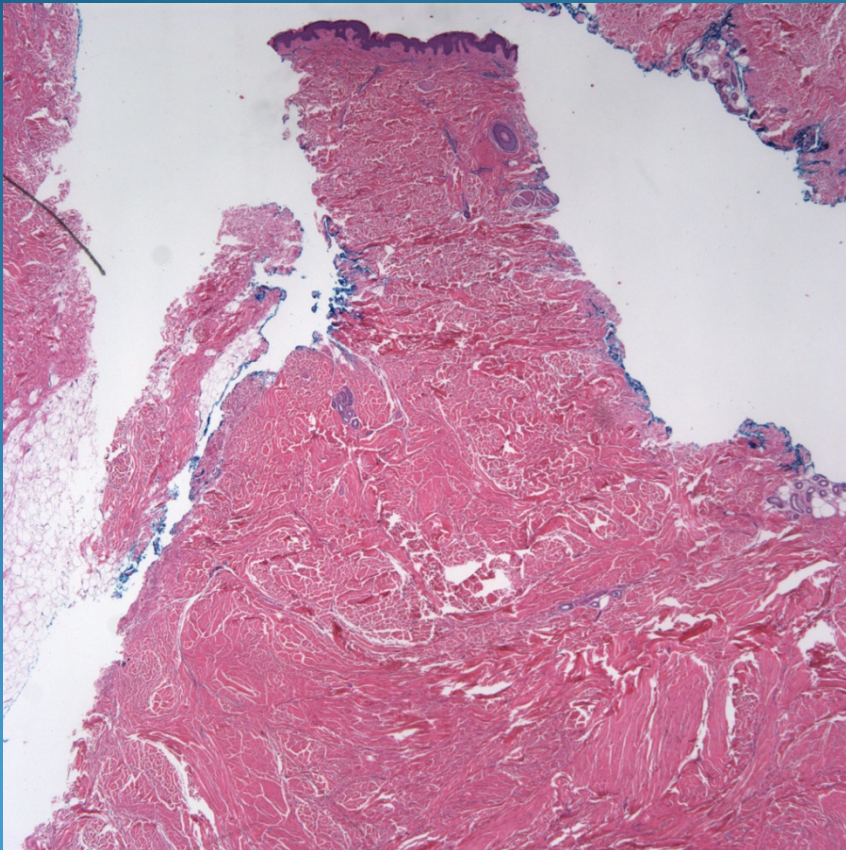


Trichrome

# Collagenoma

# Pearls



- Low power poorly defined area of fibroplasia, usually deep dermis, resembling a scar
- Lacks vertical orientation of scar collagen bundles
- Confirm with trichrome stain, consider IHC