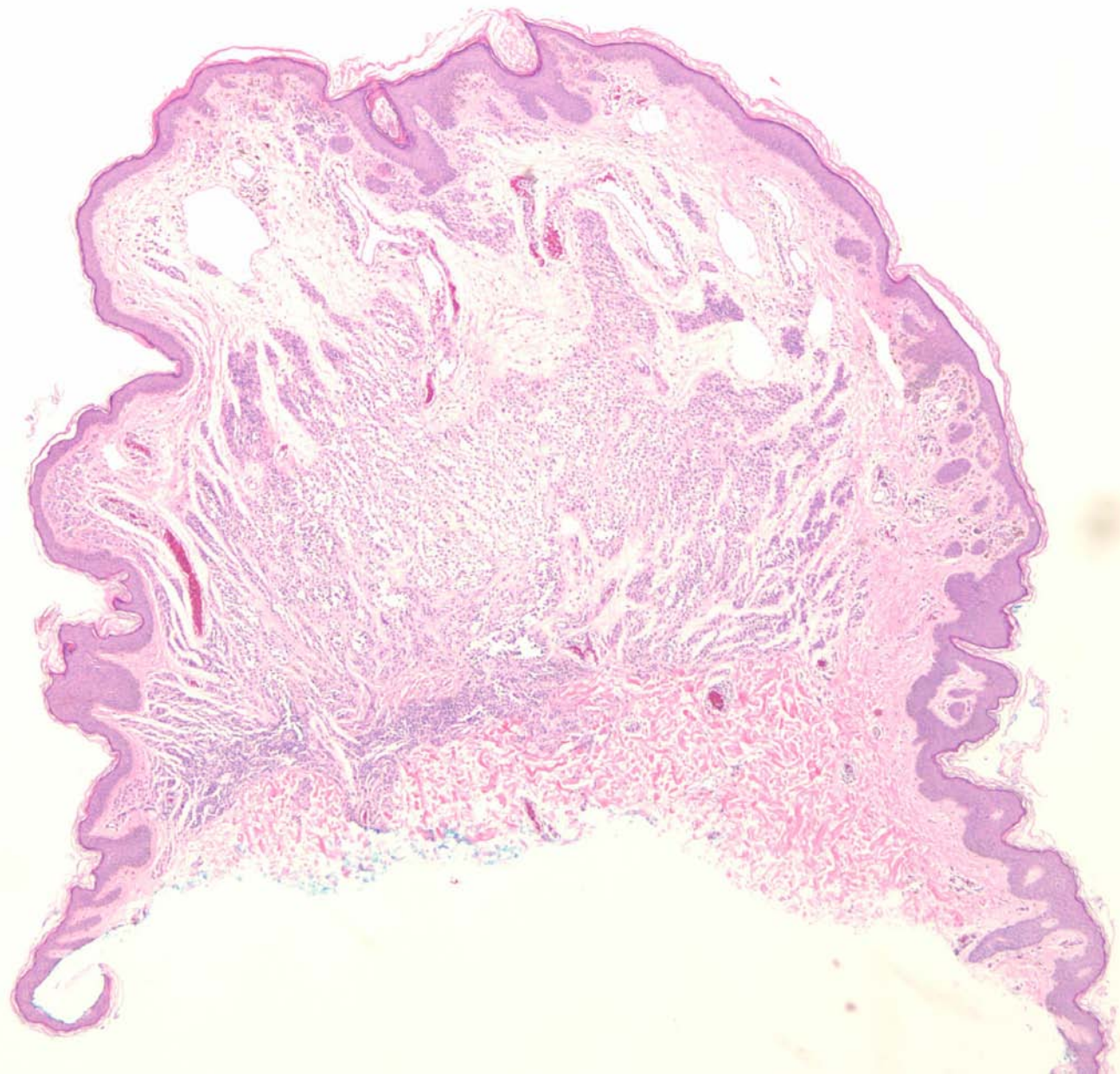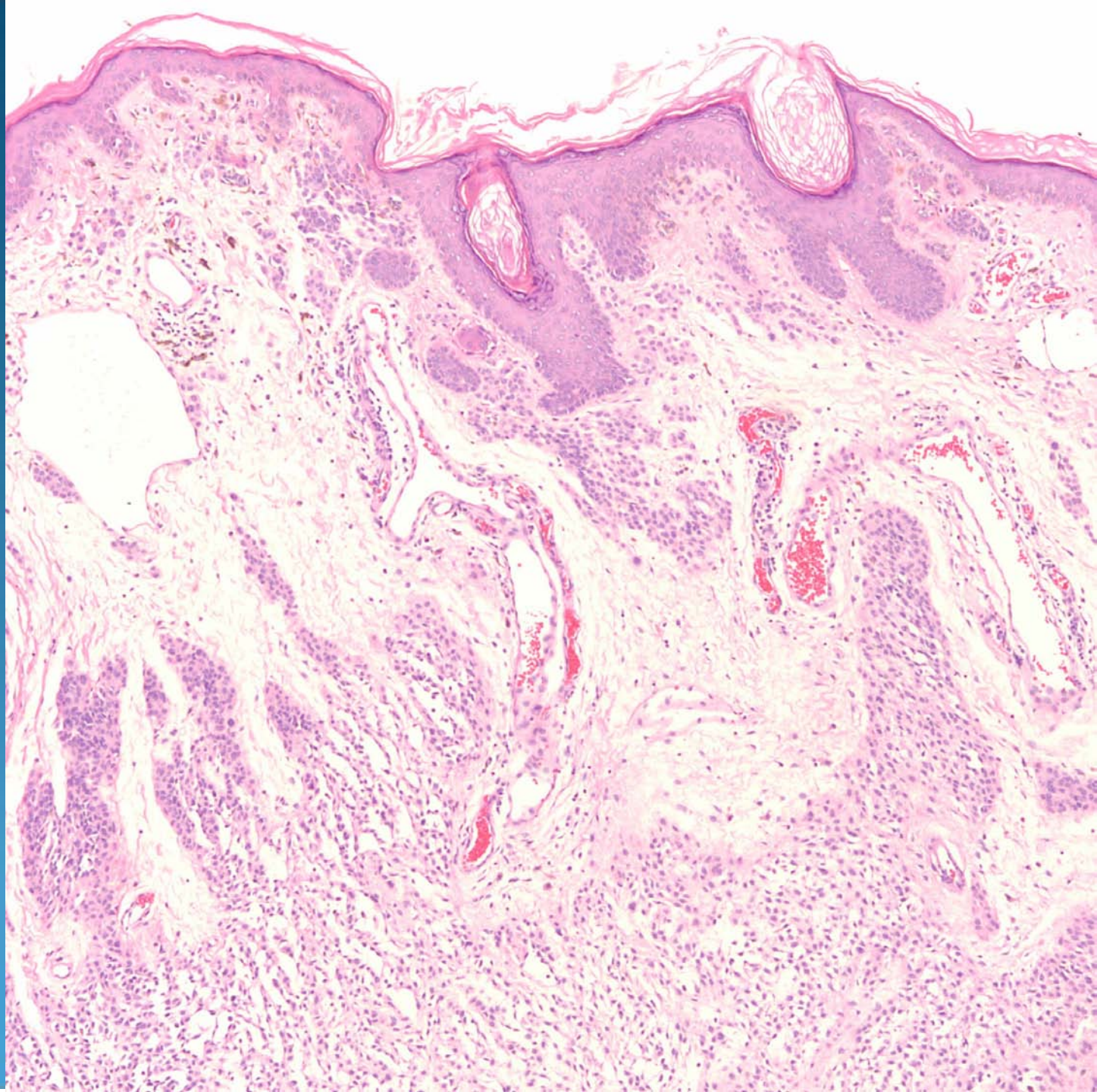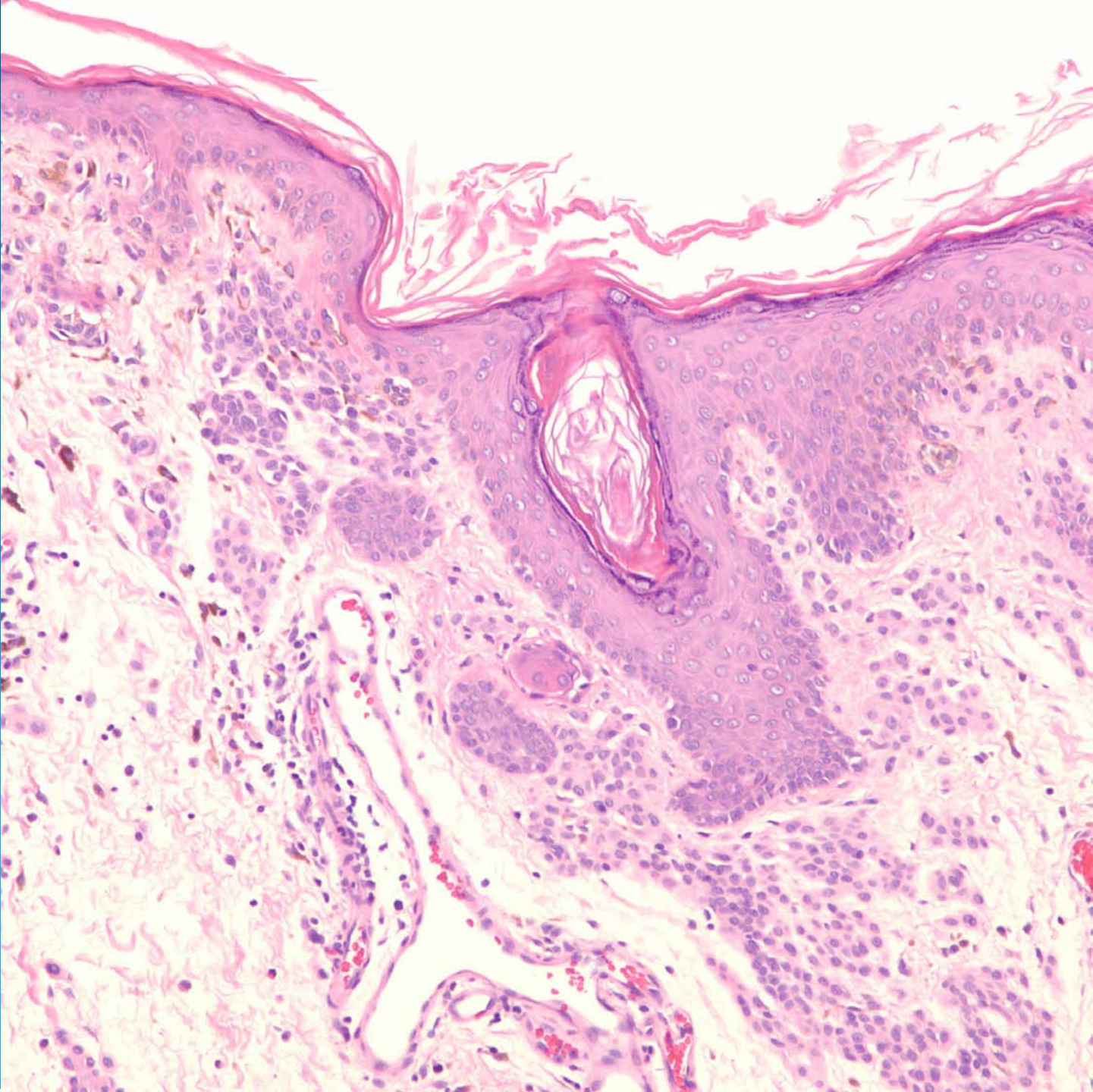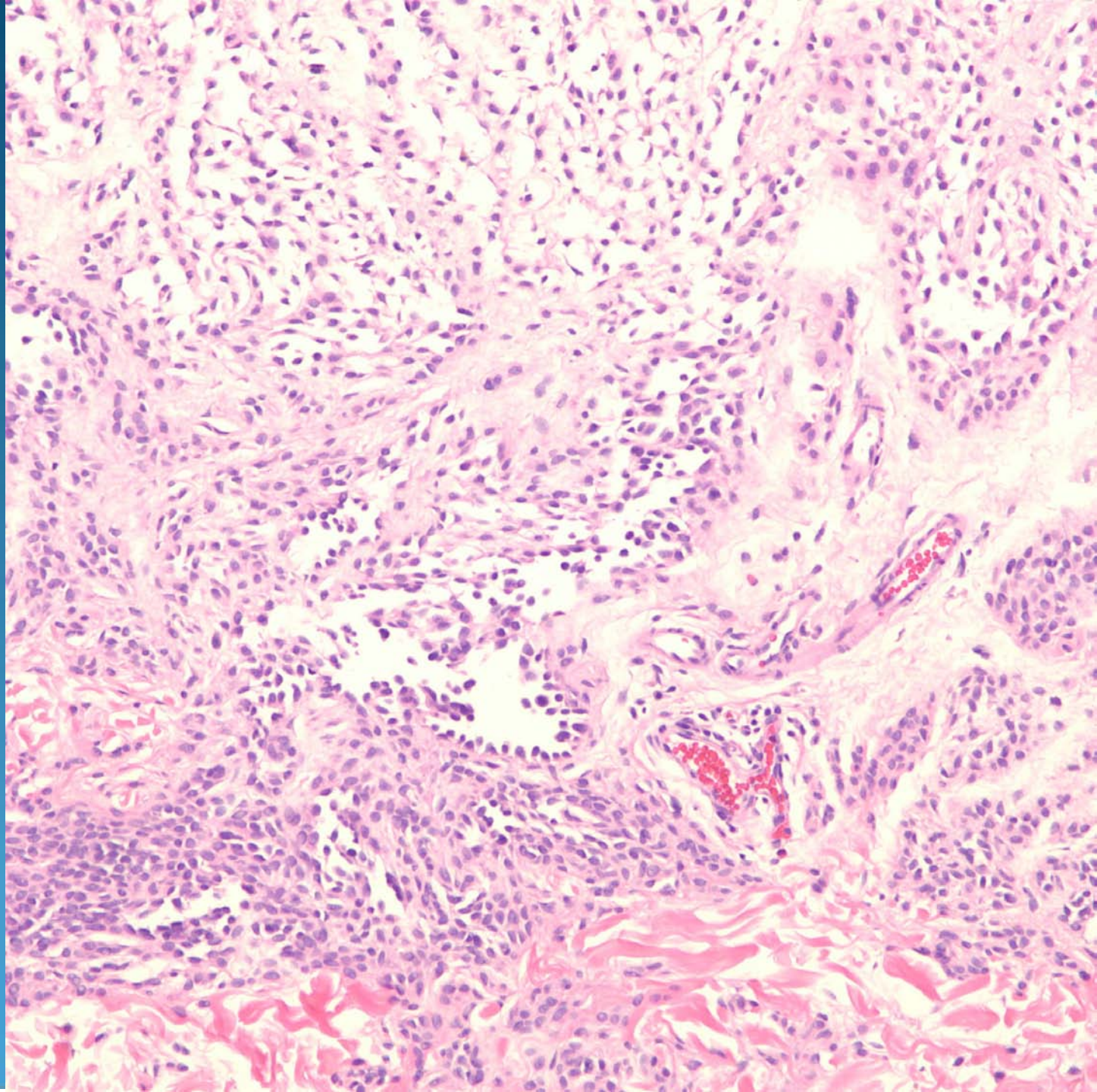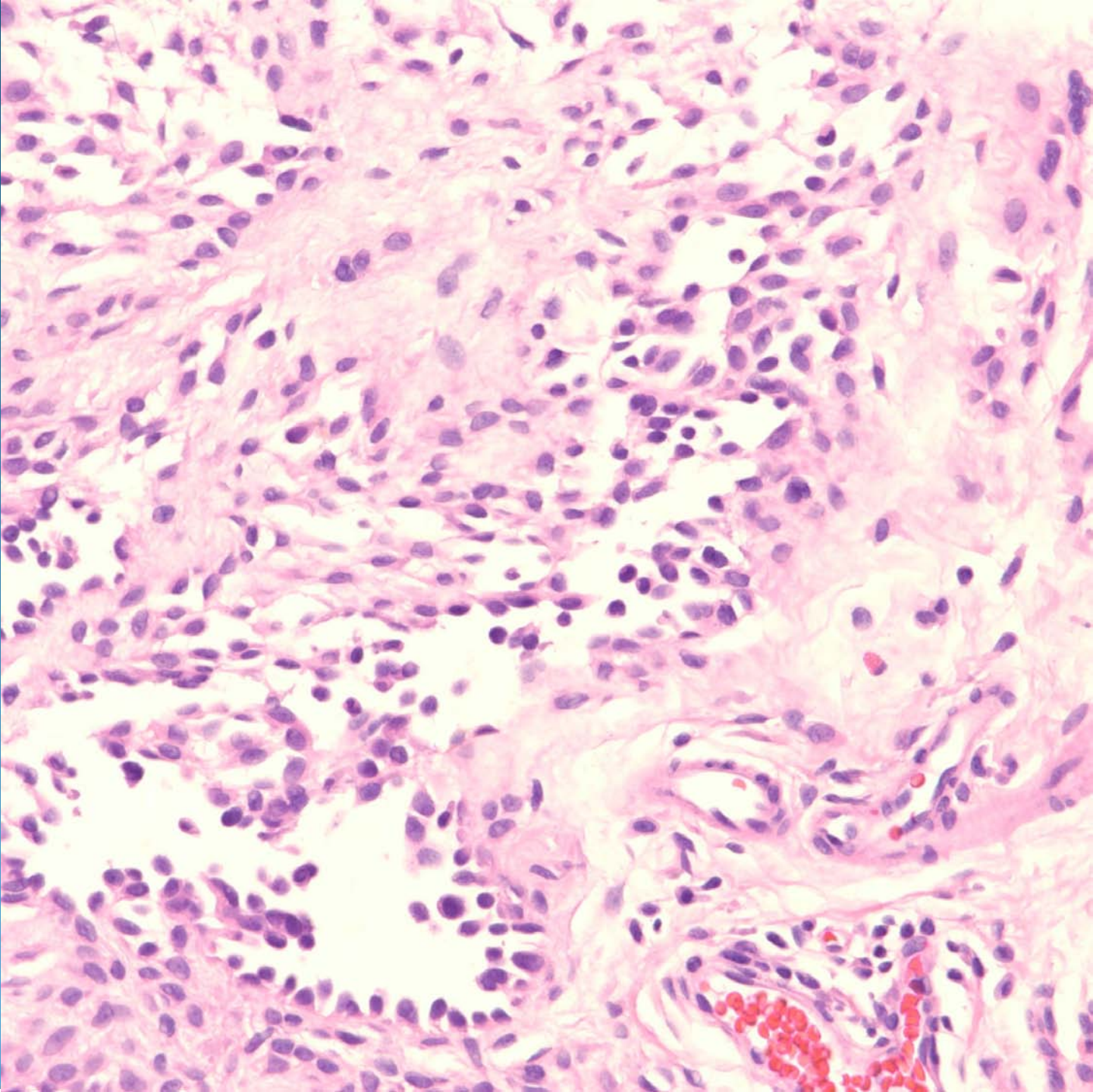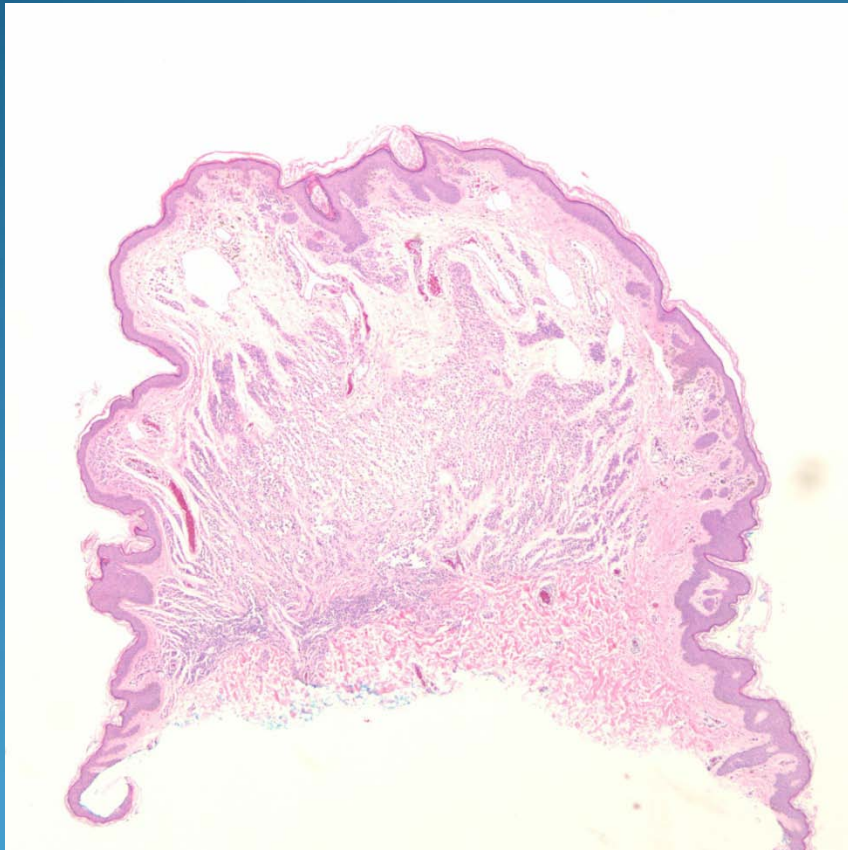


Compound Melanocytic Nevus

Pearls



- May be dome shaped, symmetrical
- Junctional melanocytes merging with dermal melanocytes
- Good maturation with no cytologic atypia or deep mitotic figures