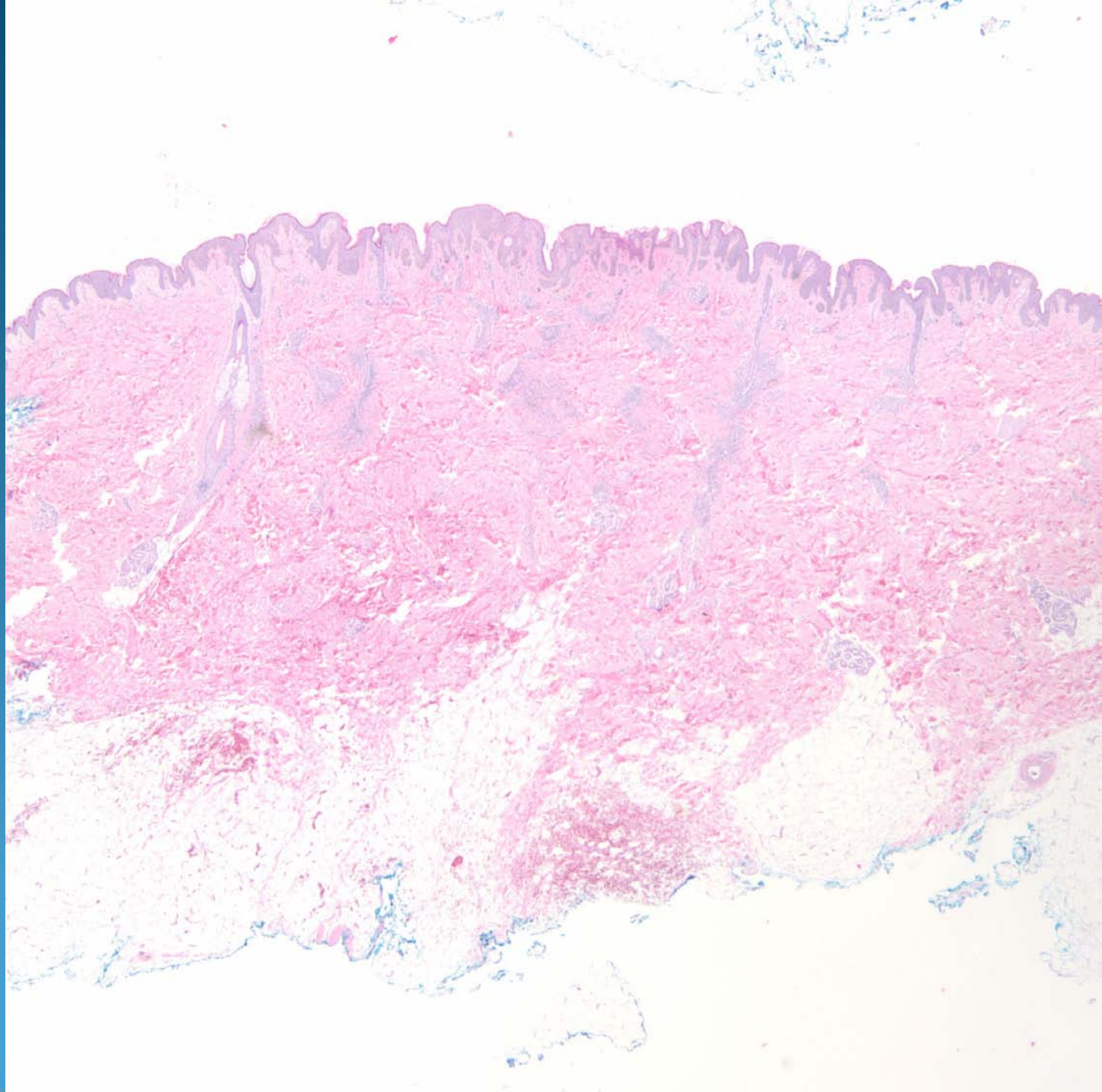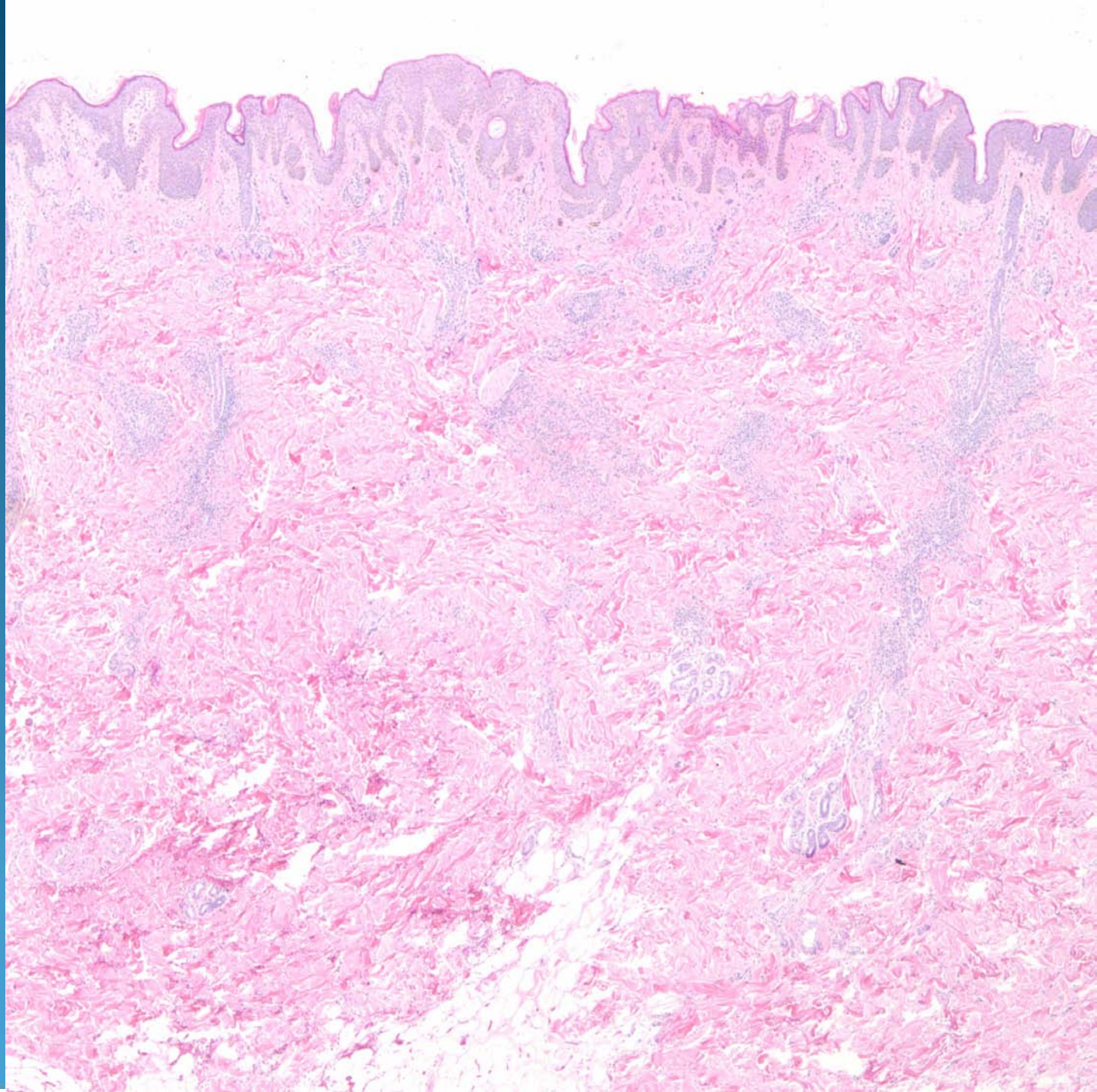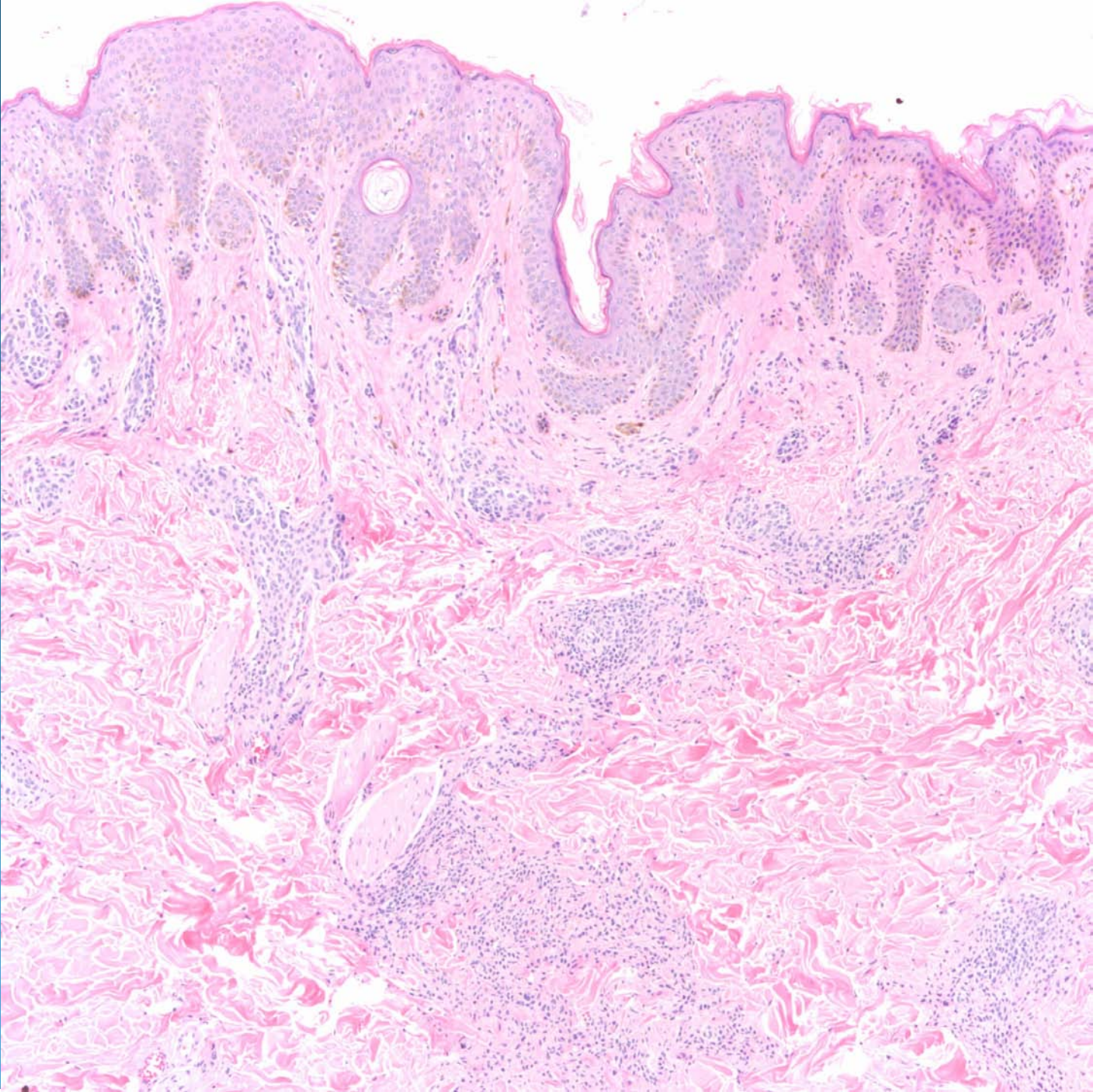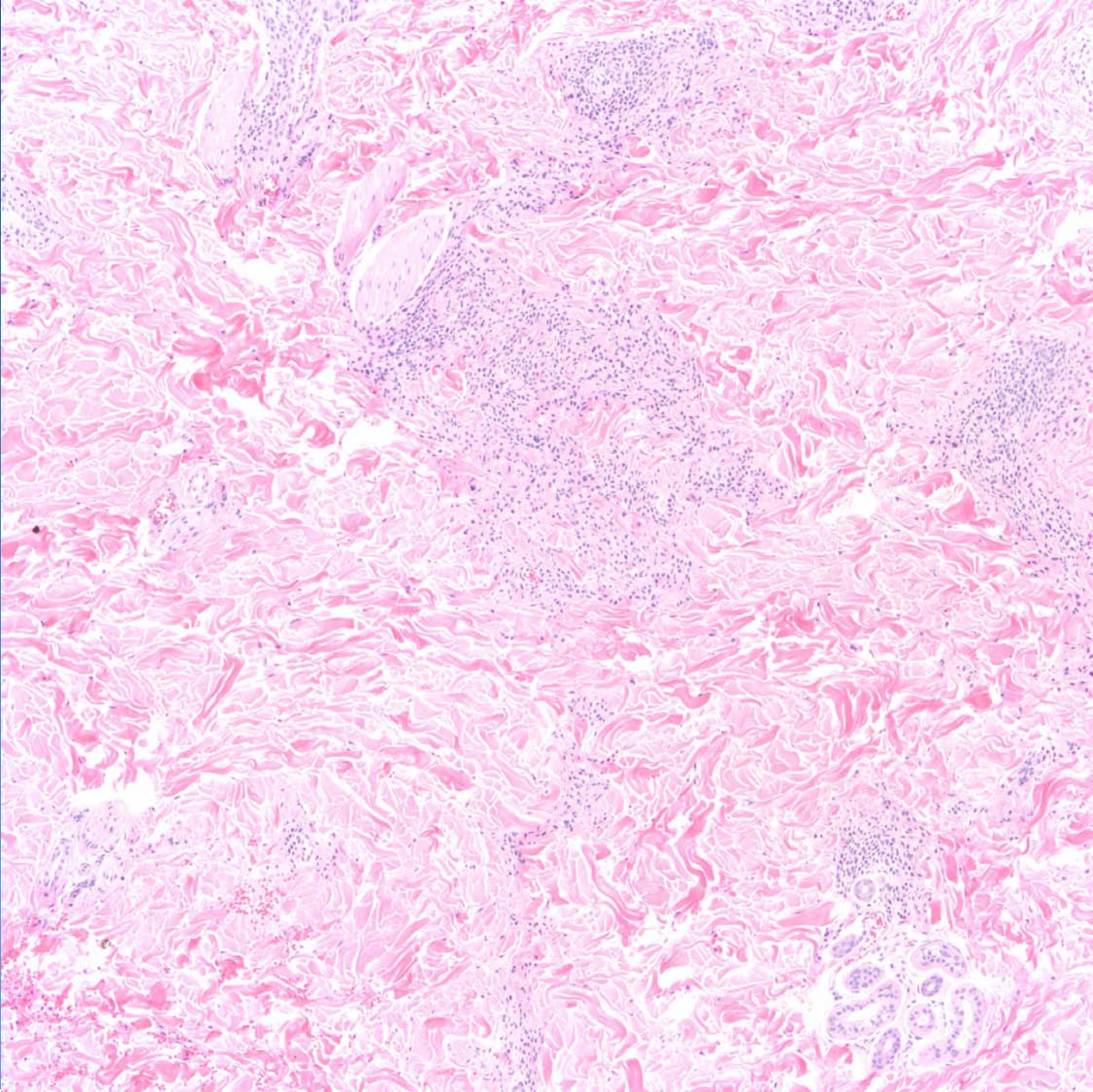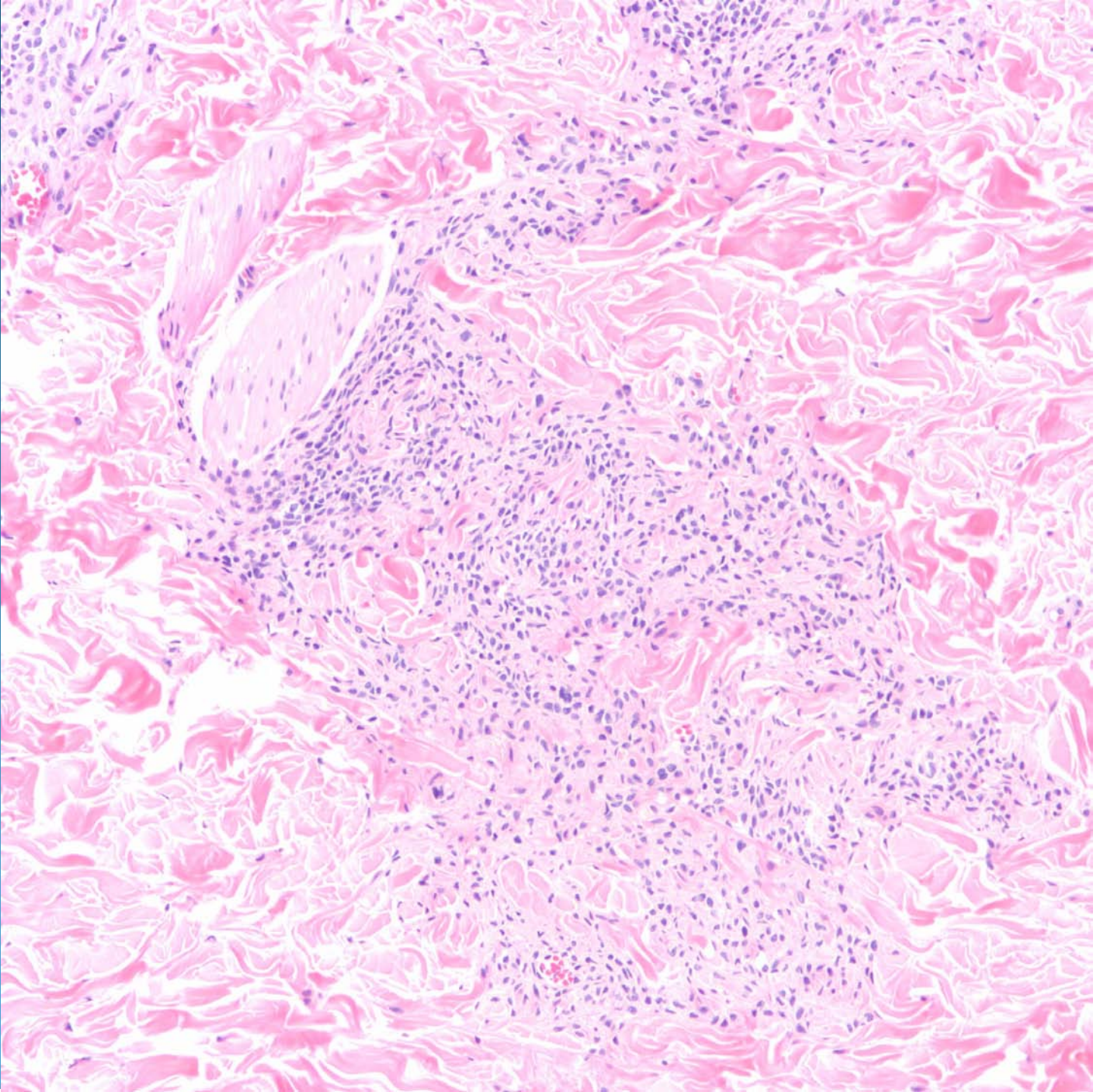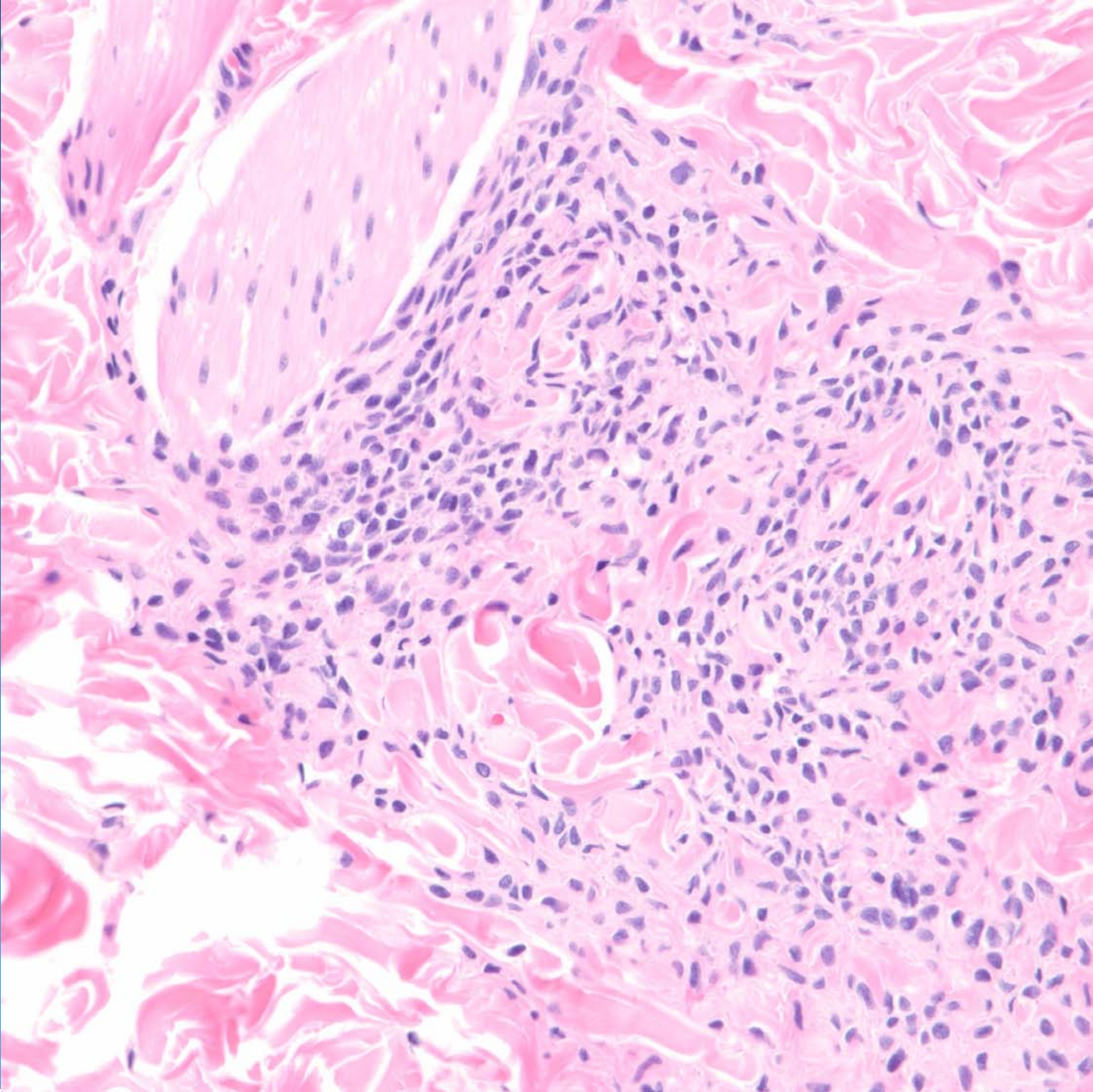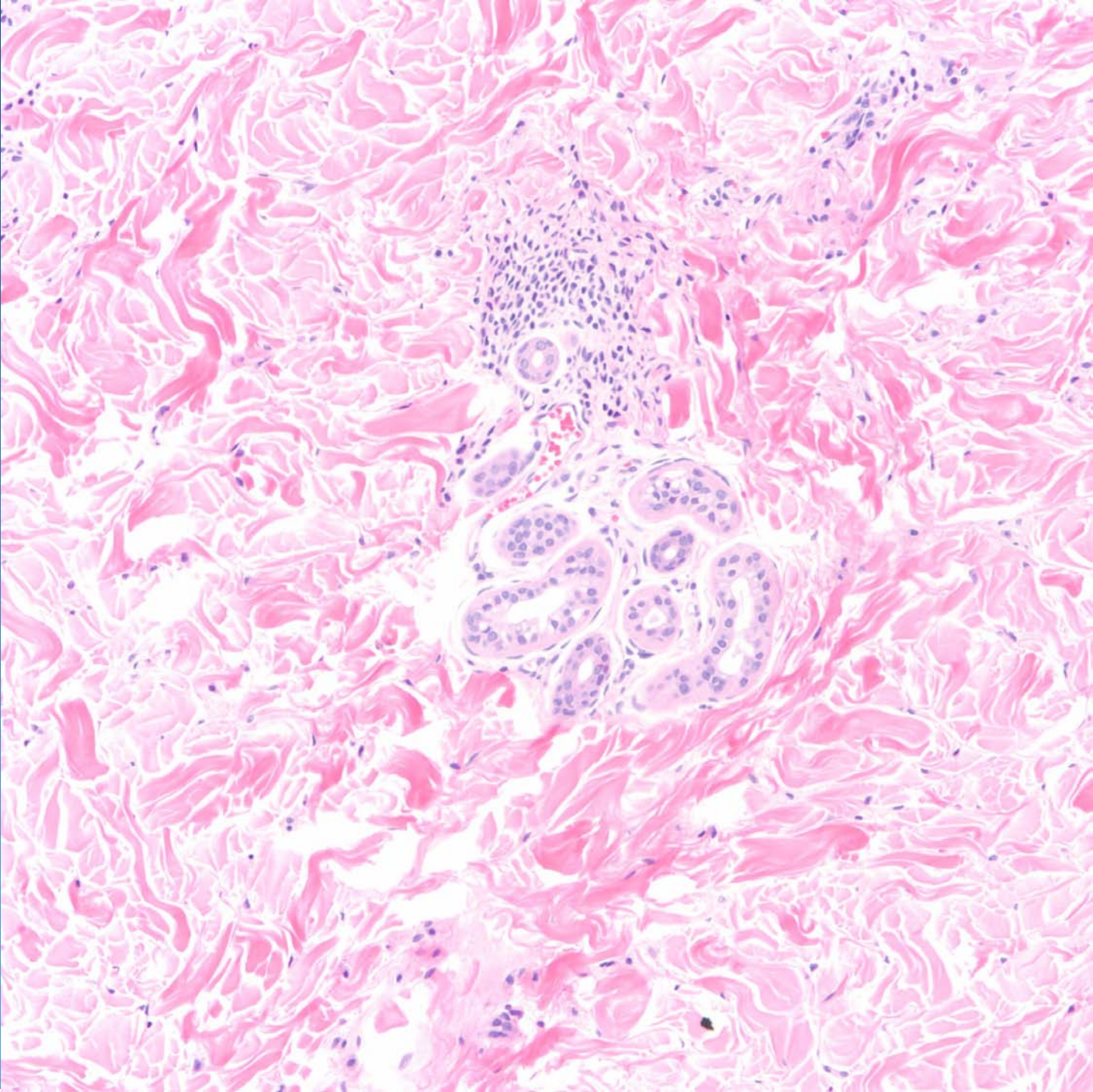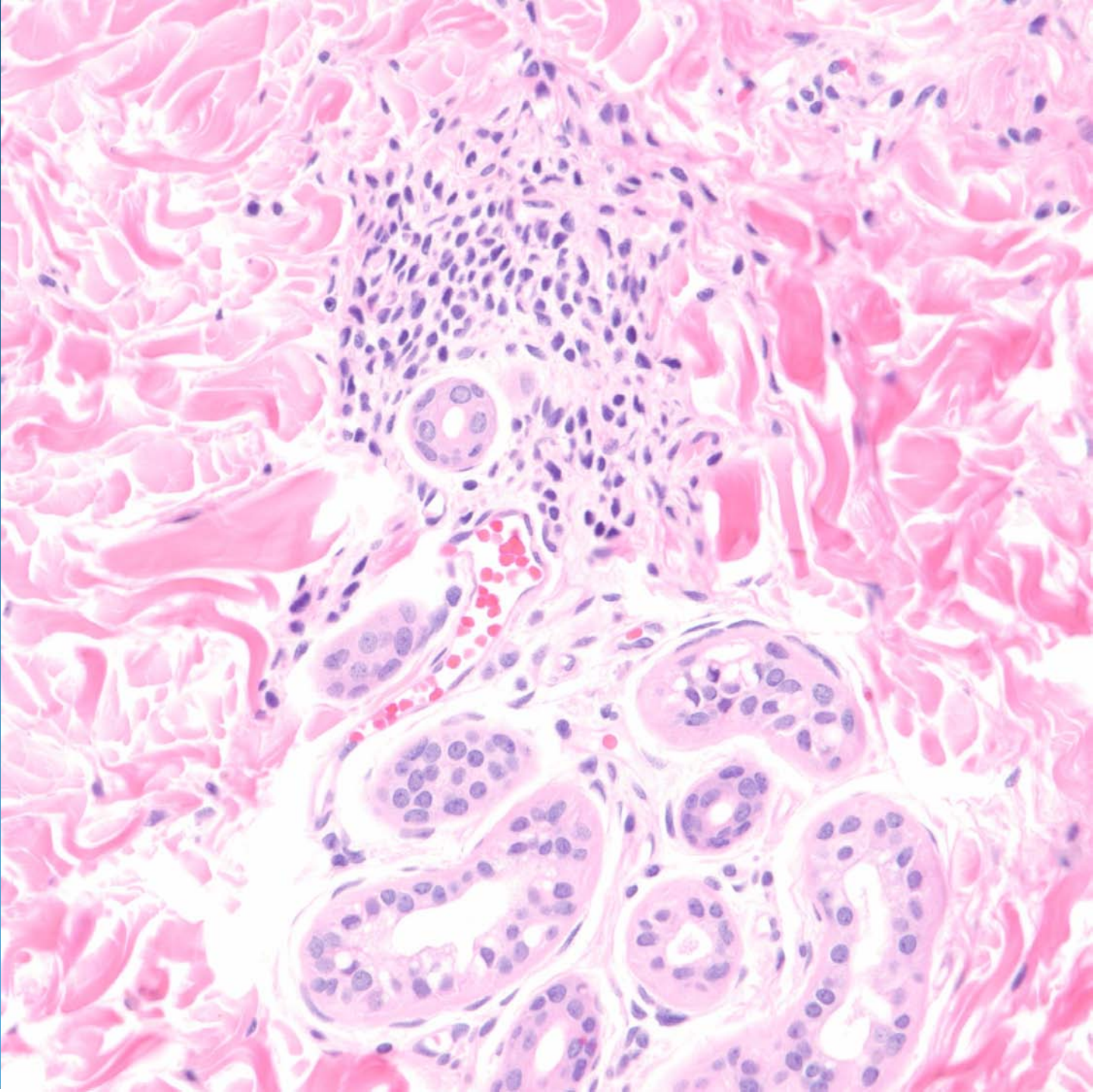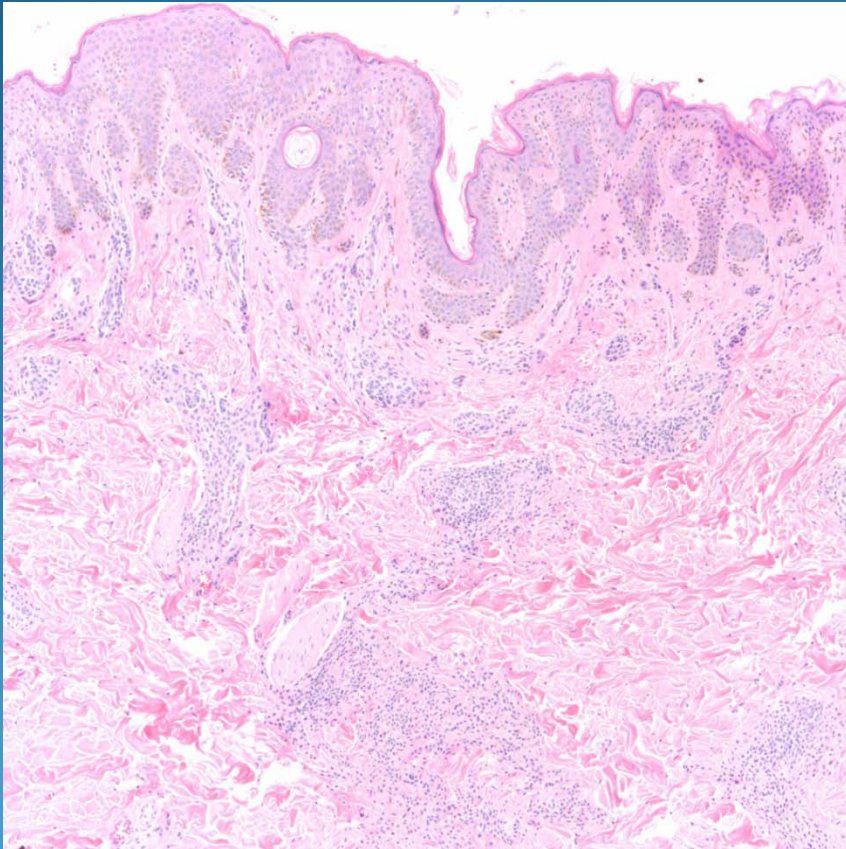


Congenital Melanocytic Nevus

Pearls



- Benign melanocytic nevus with variable compound or intradermal presentations
- Usually not symmetrical with splaying of collagen fibers, extension into adnexal structures, and arrector pilae muscles
- Bland nuclear cytology with maturation