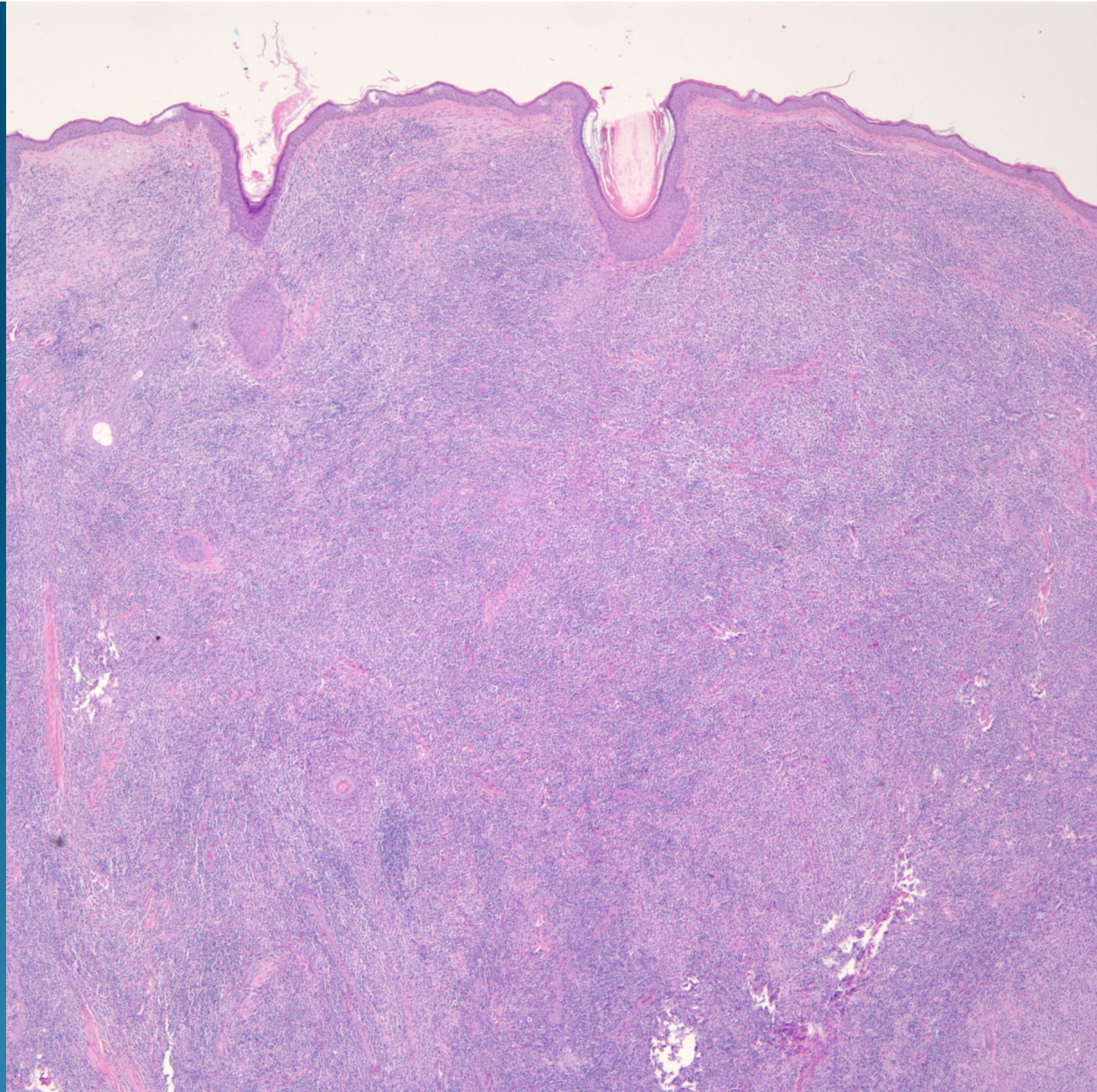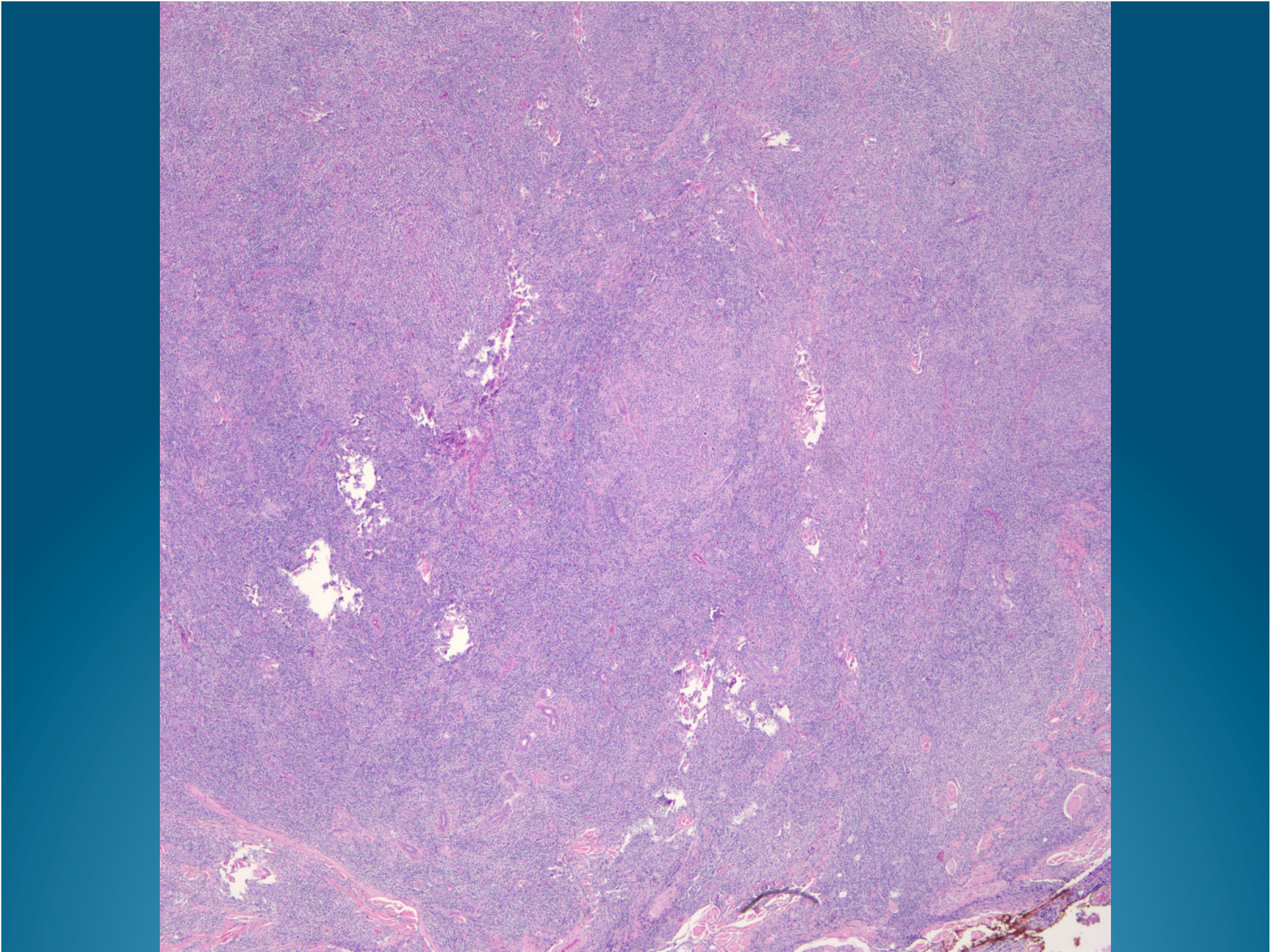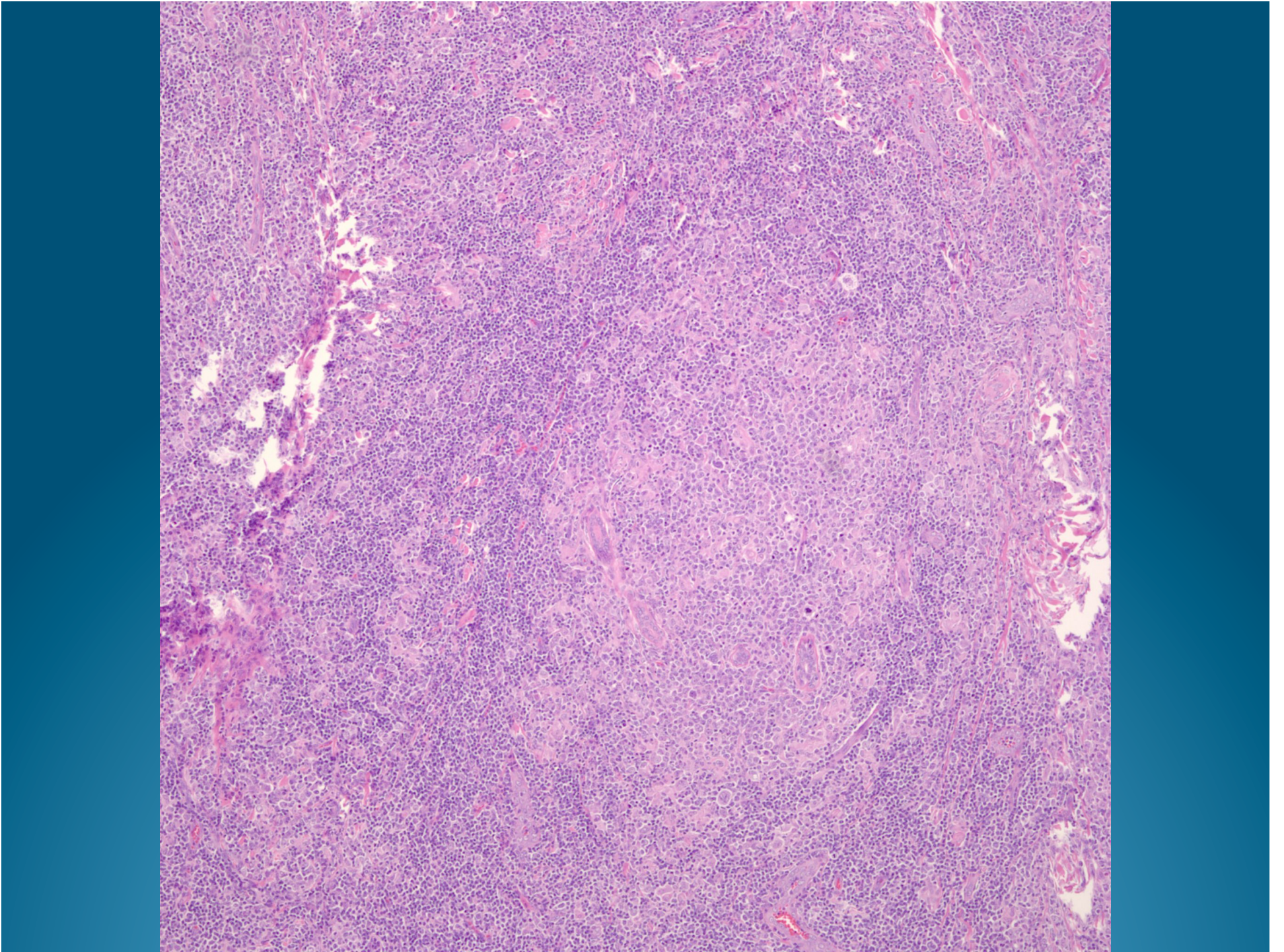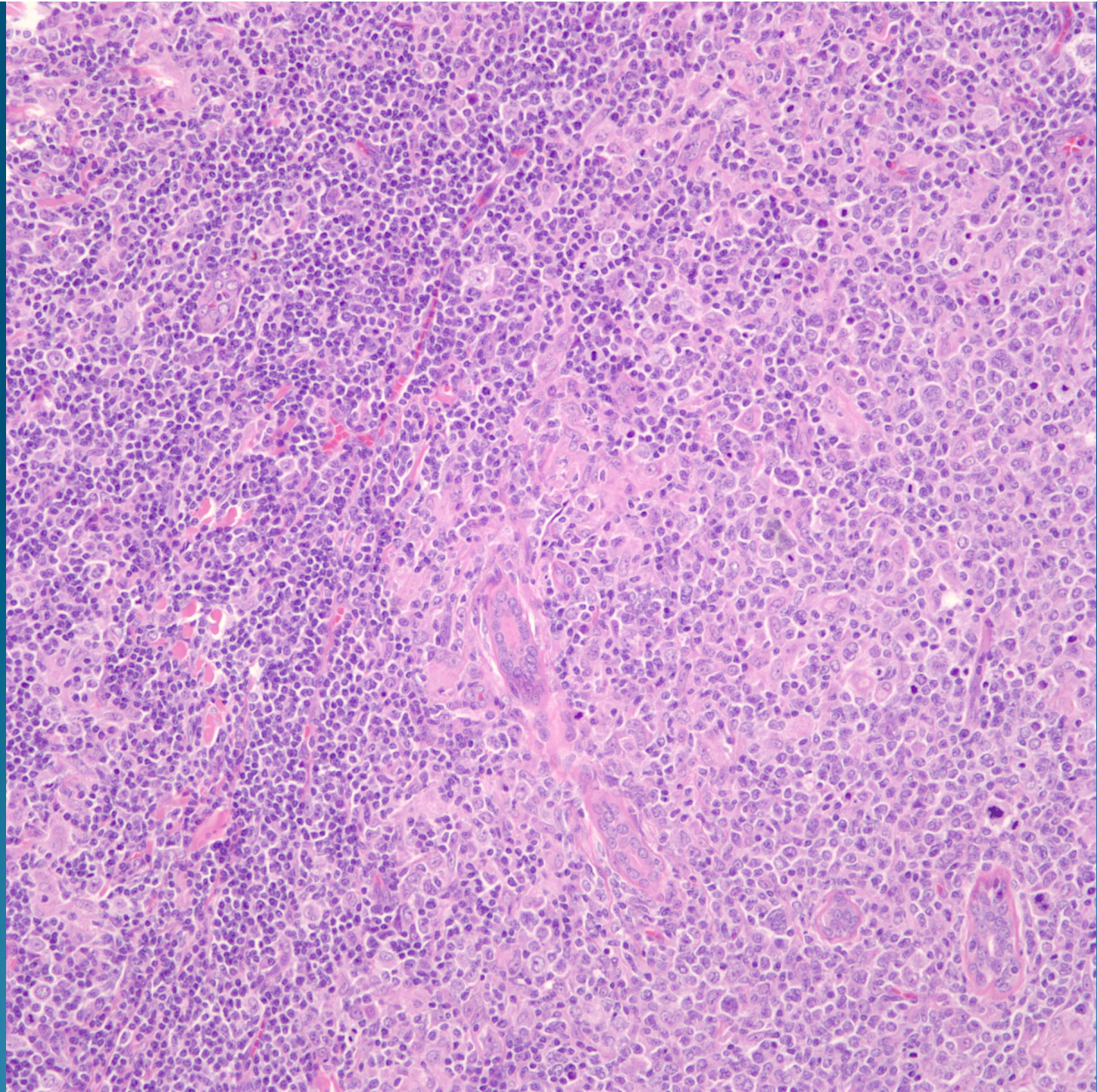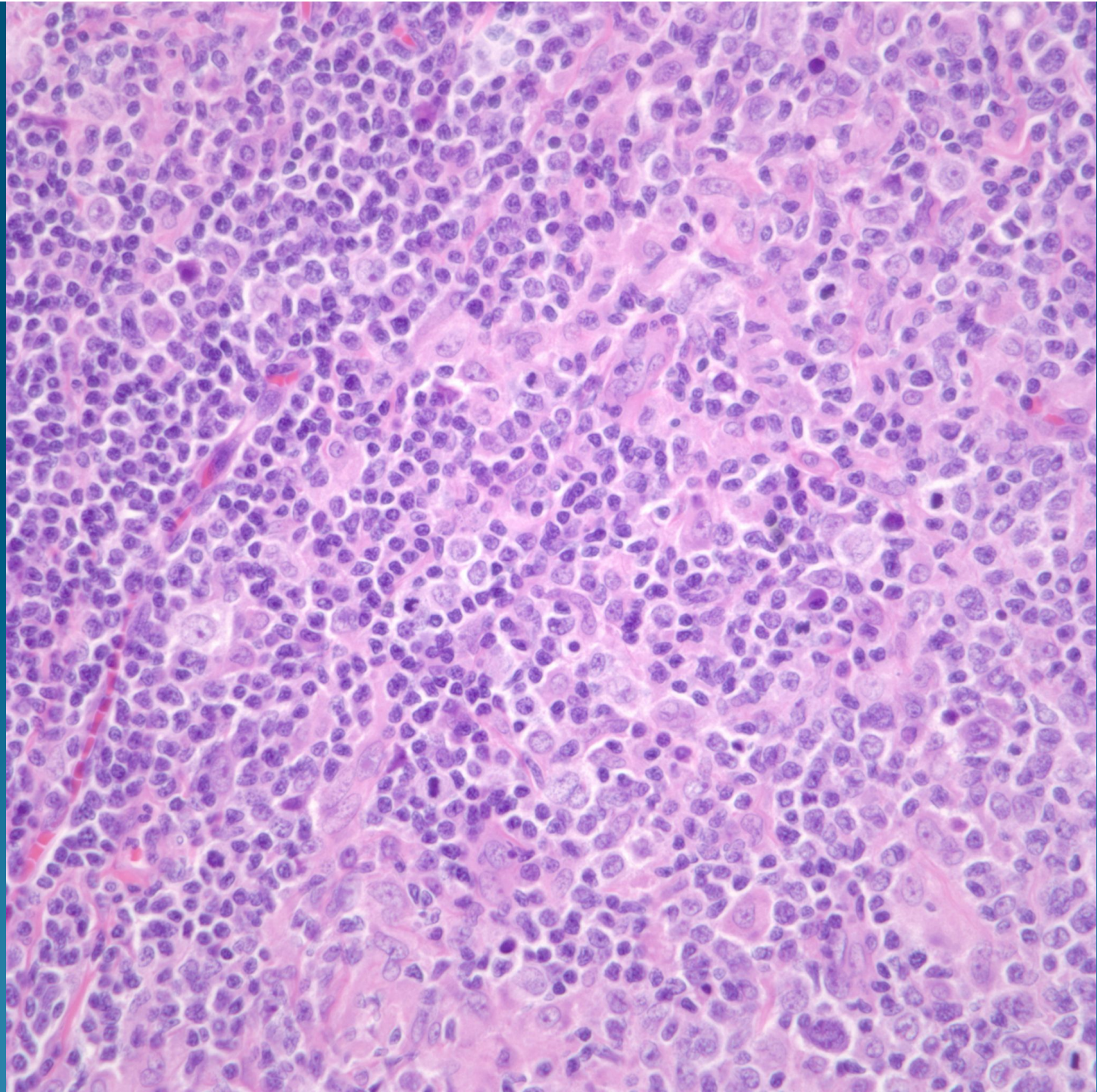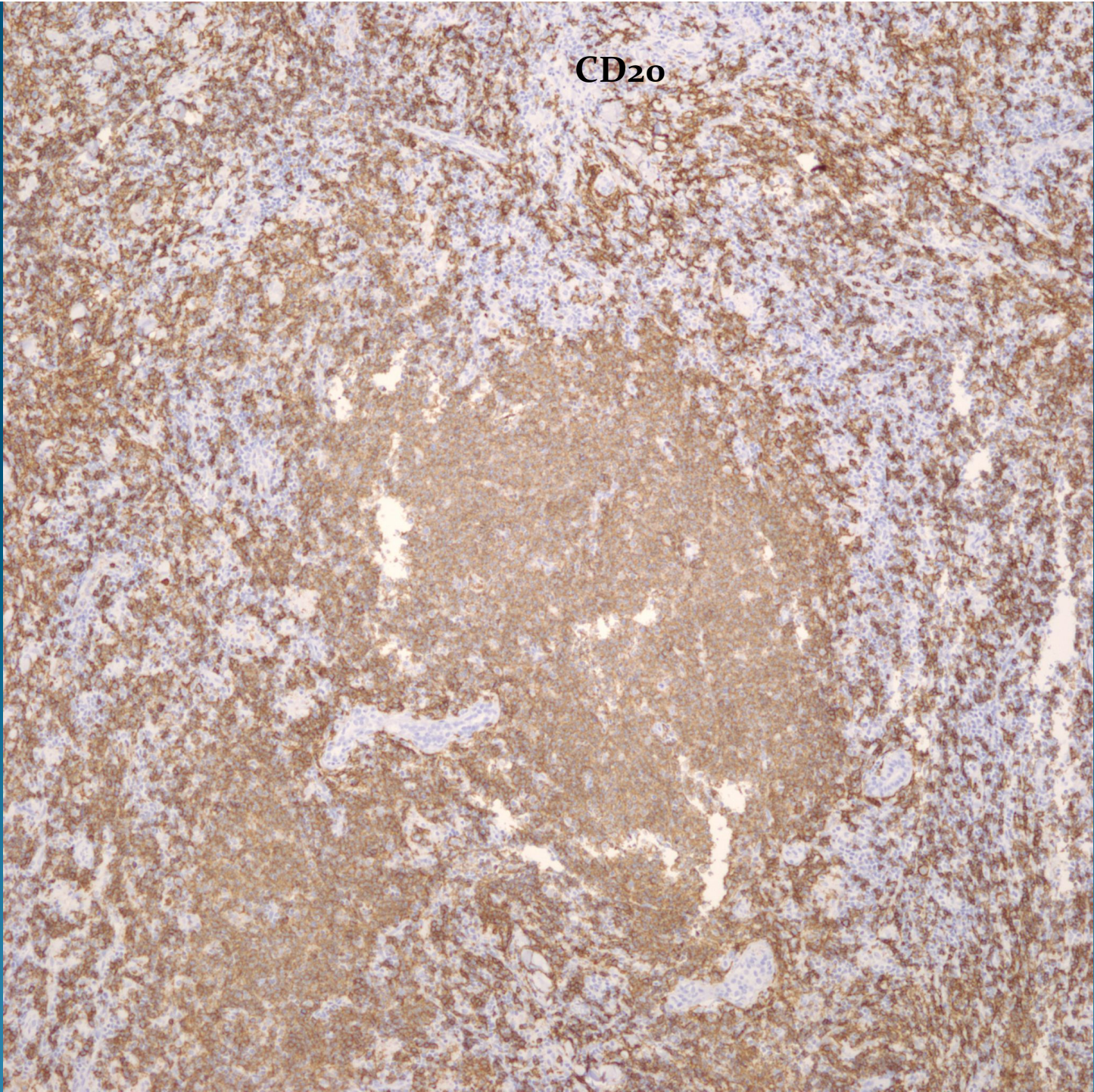
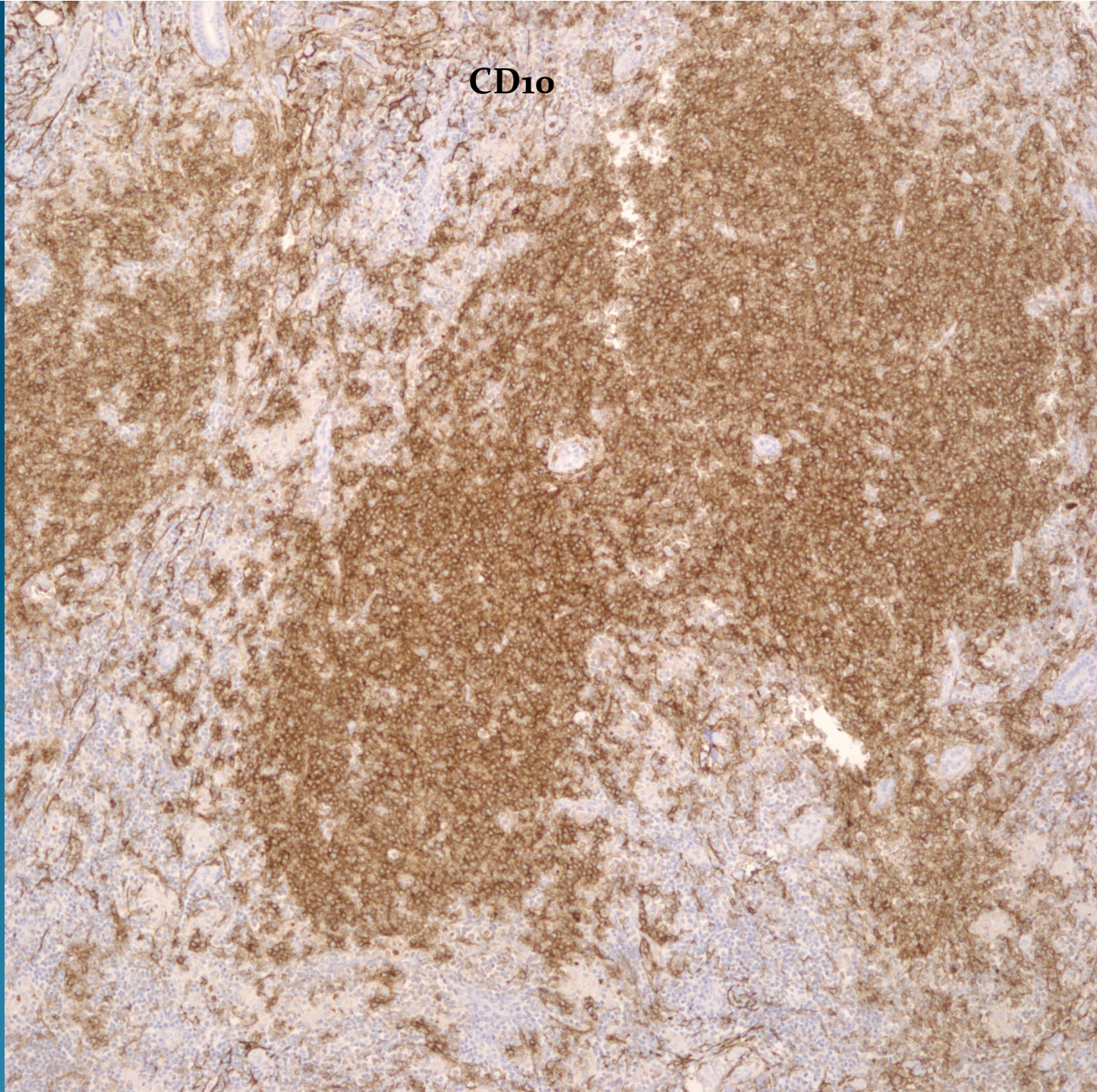


CD20



**CD10**



# What is the best diagnosis?

- A. Mycosis fungoides-tumor stage
- B. Anaplastic large cell lymphoma
- C. Lymphomatoid papulosis
- D. Kimura's disease
- E. Cutaneous B-cell lymphoma



Cutaneous B-cell Lymphoma  
Follicle Center Cell Type  
Low Grade

Dense and diffuse dermal lymphoid infiltrate

Follicular pattern with mantle zones

Small lymphs with Cleaved nuclear contours

Bottom heavy infiltrate

