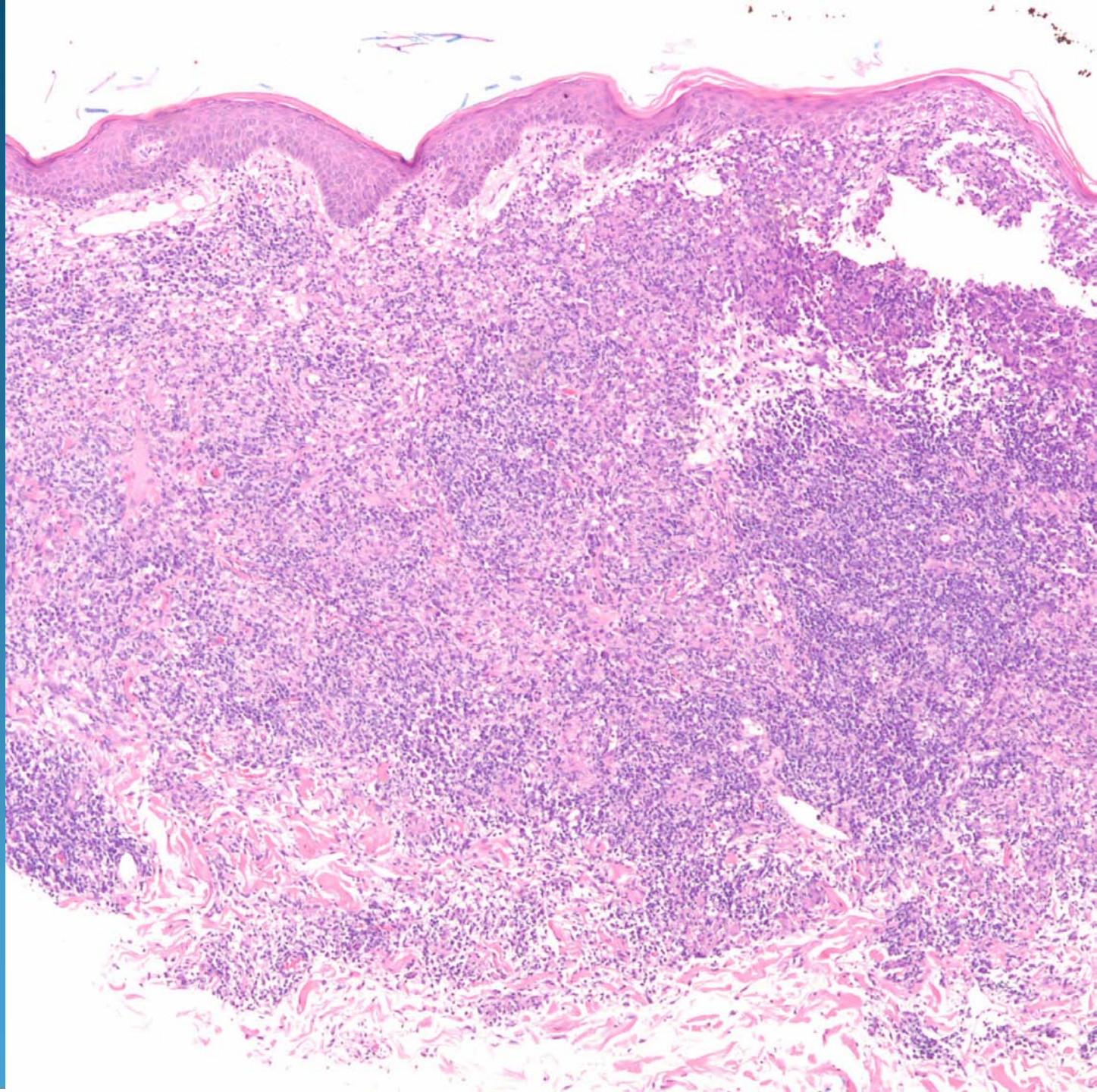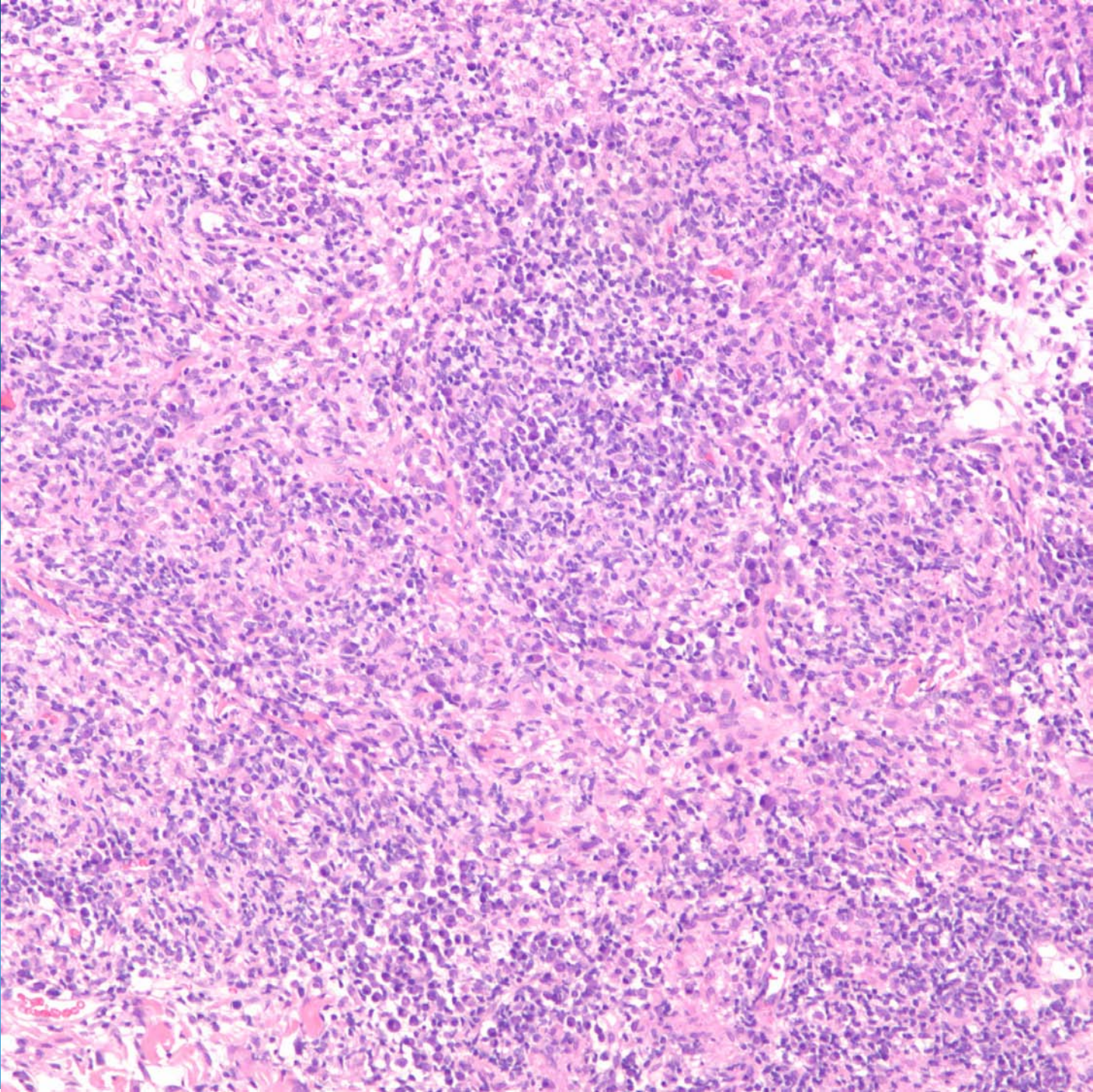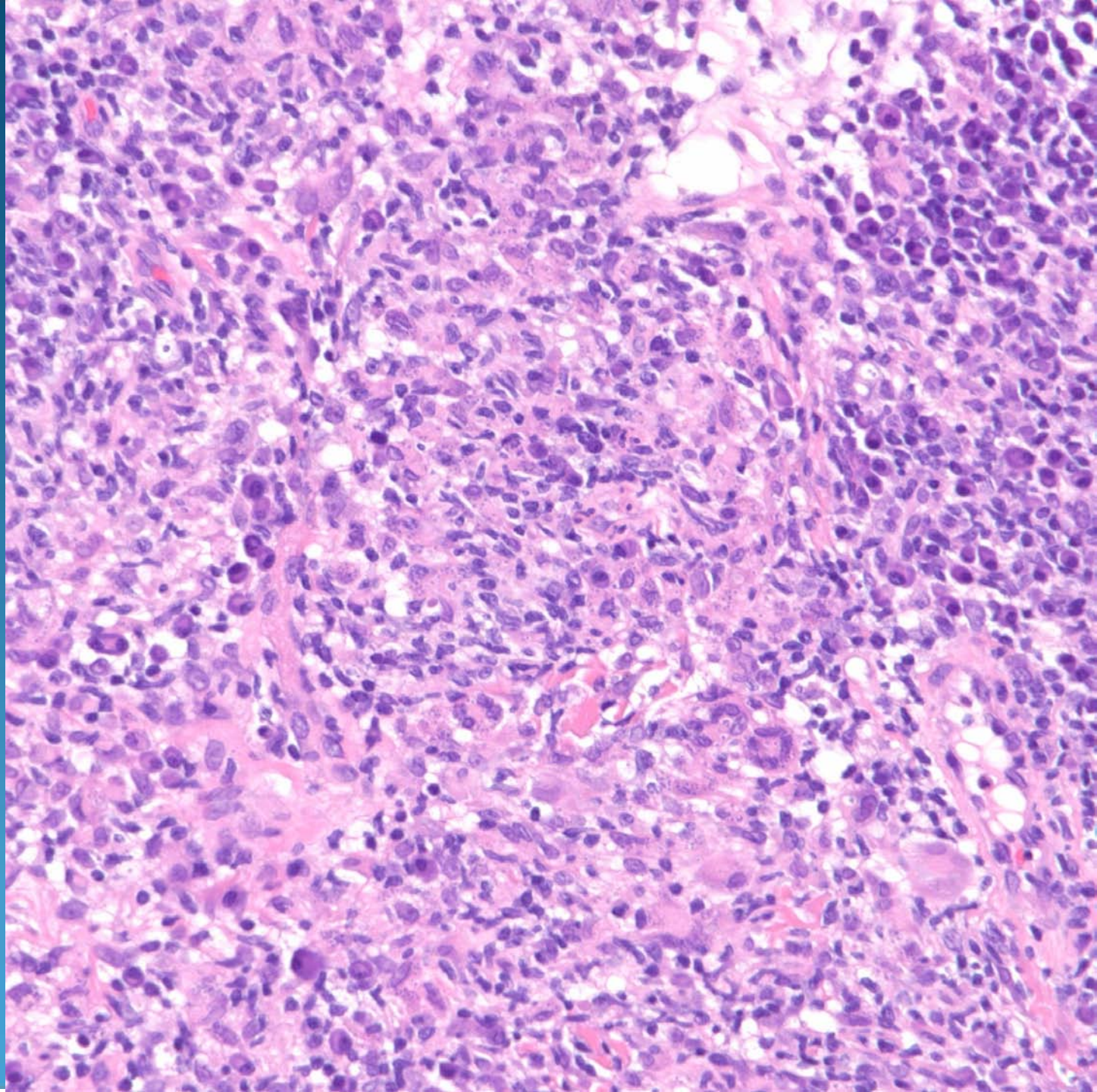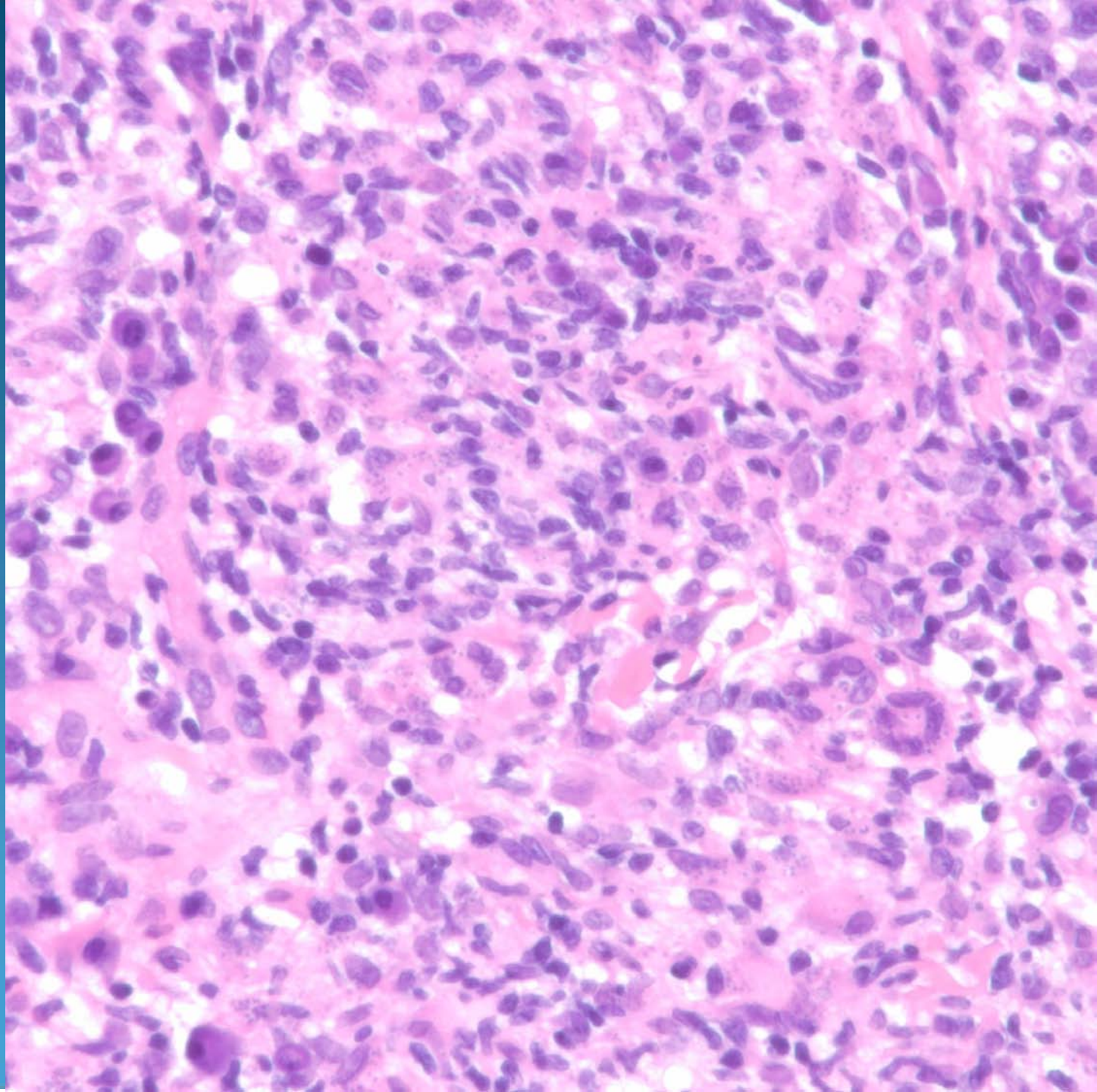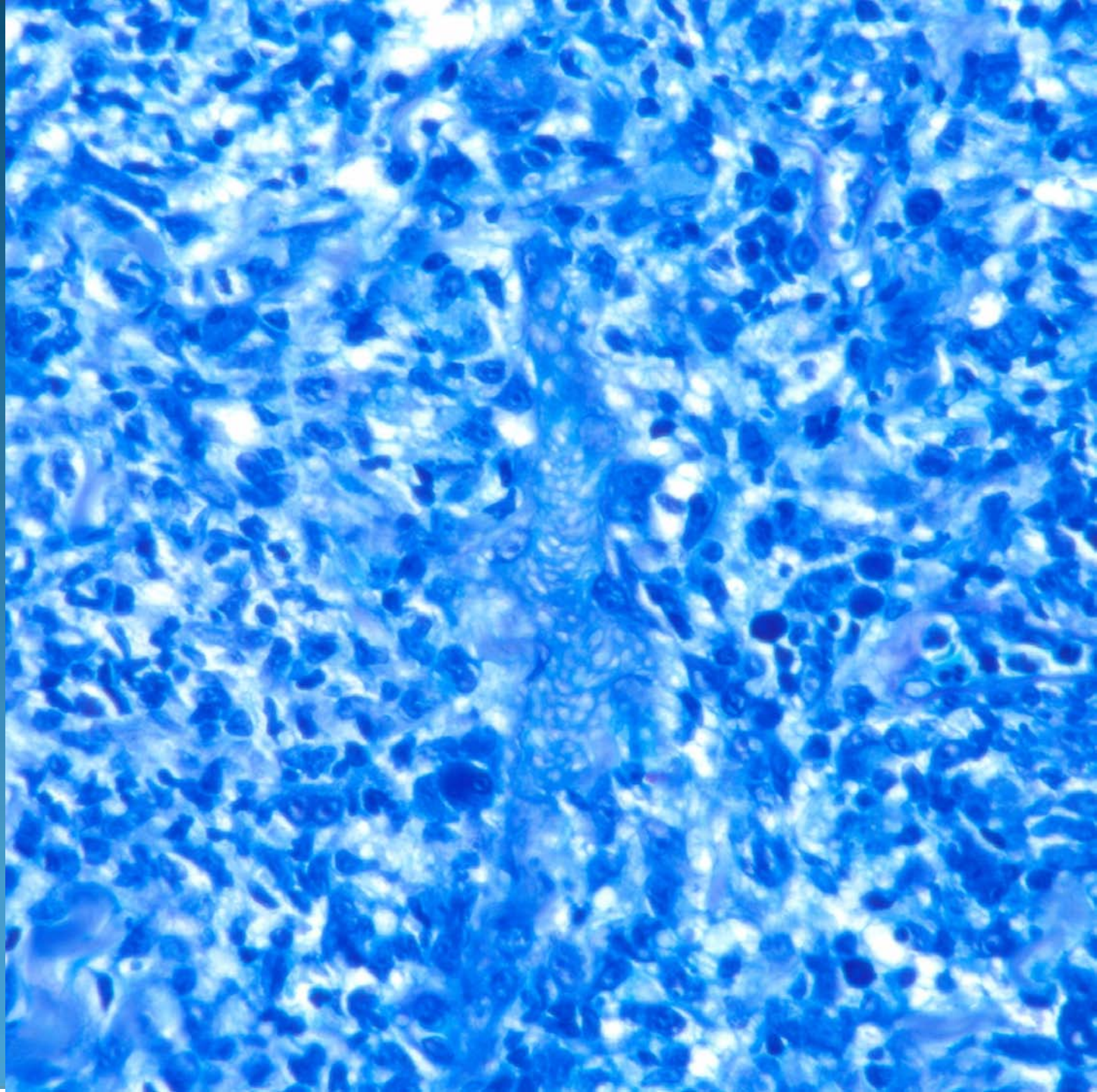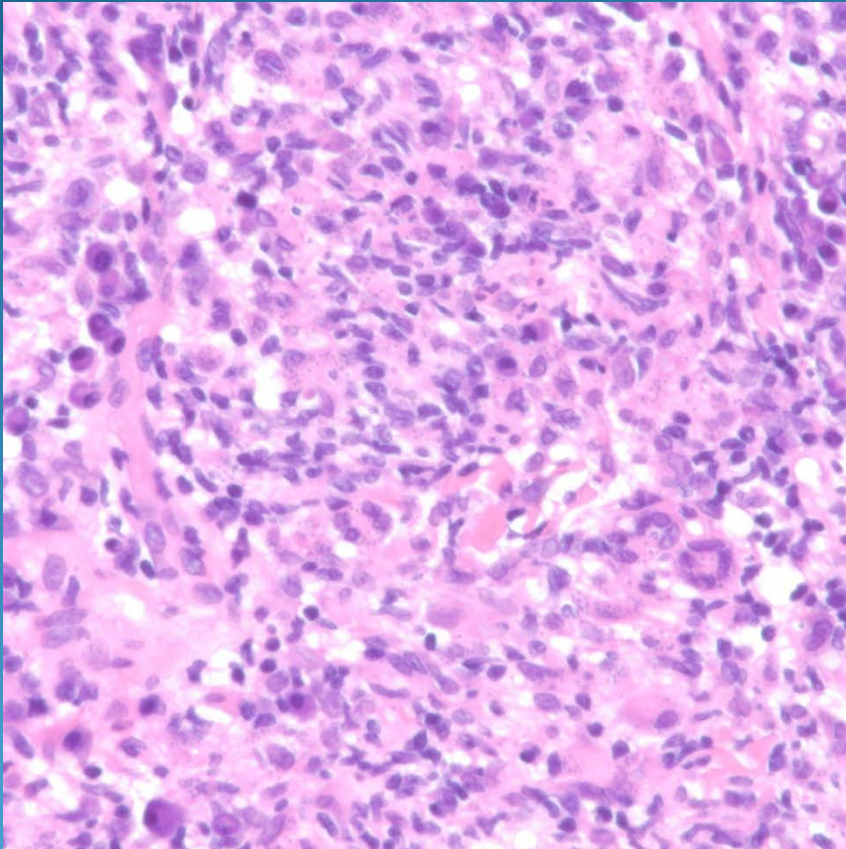


Leishmaniasis

Pearls



- Diffuse and nodular mixed inflammatory infiltrate with giant cells
- Histiocytes stuffed with amastigotes, very tiny about 1 micron
- Confirm with Giemsa+ and GMS/PAS-