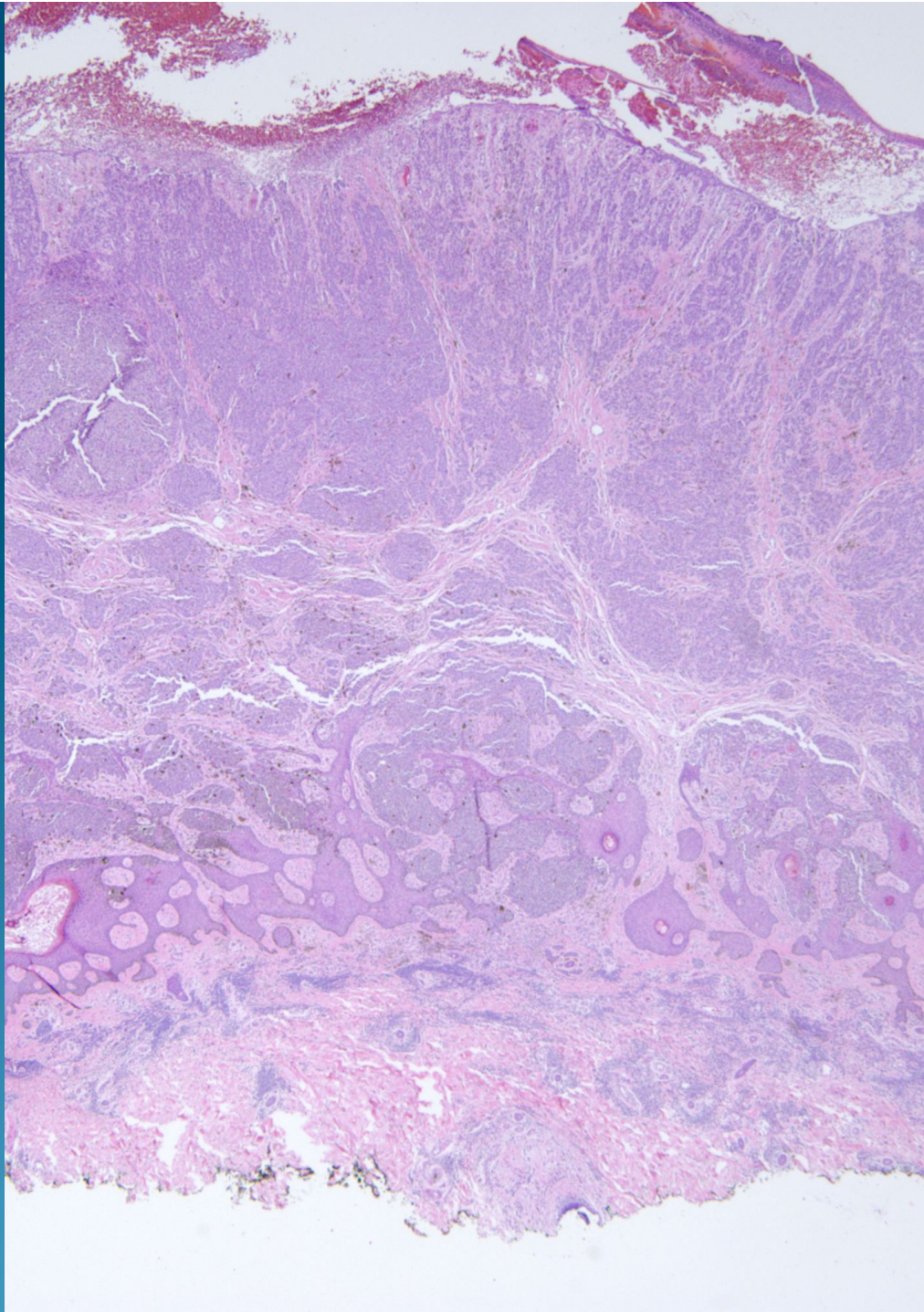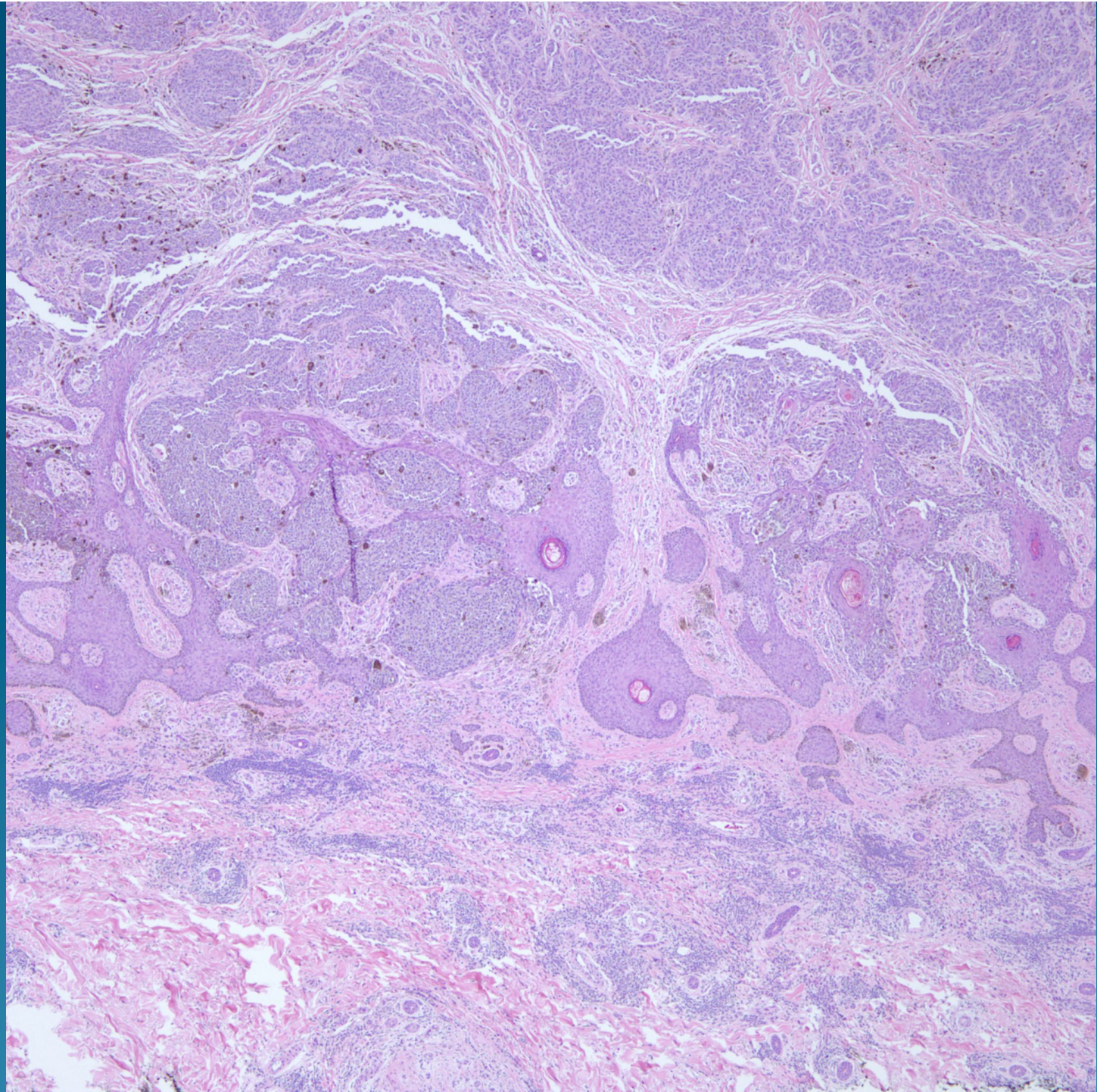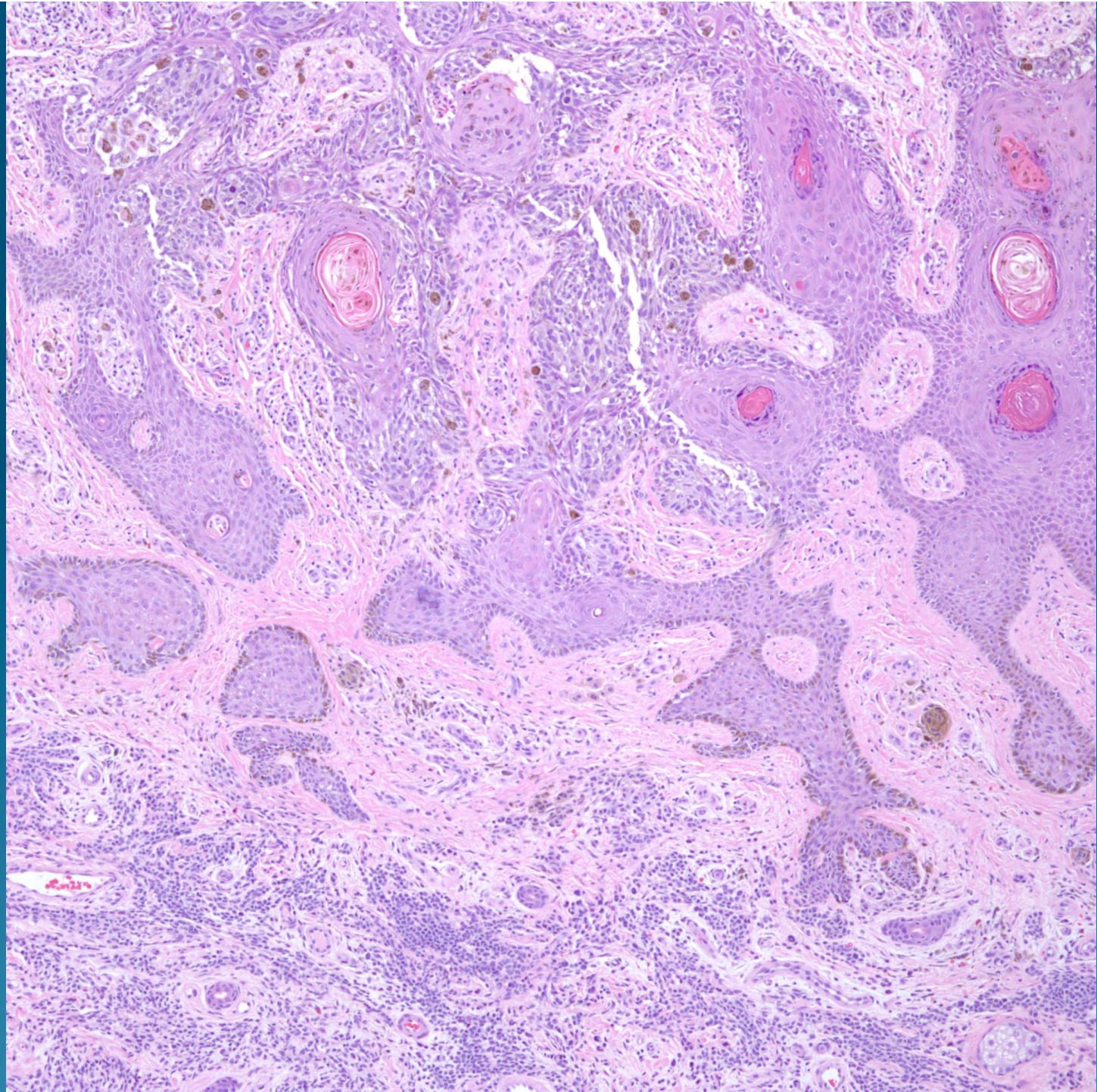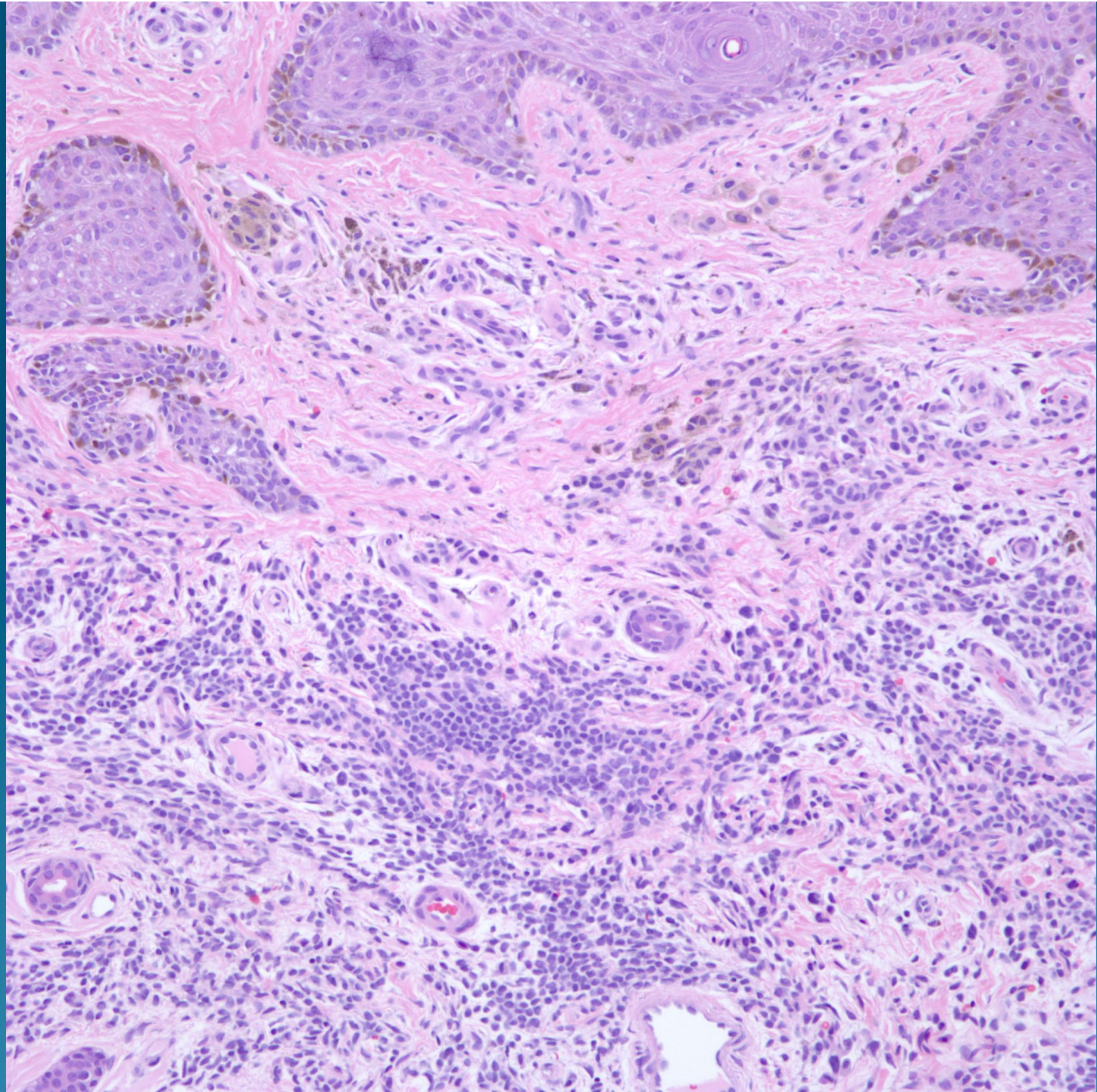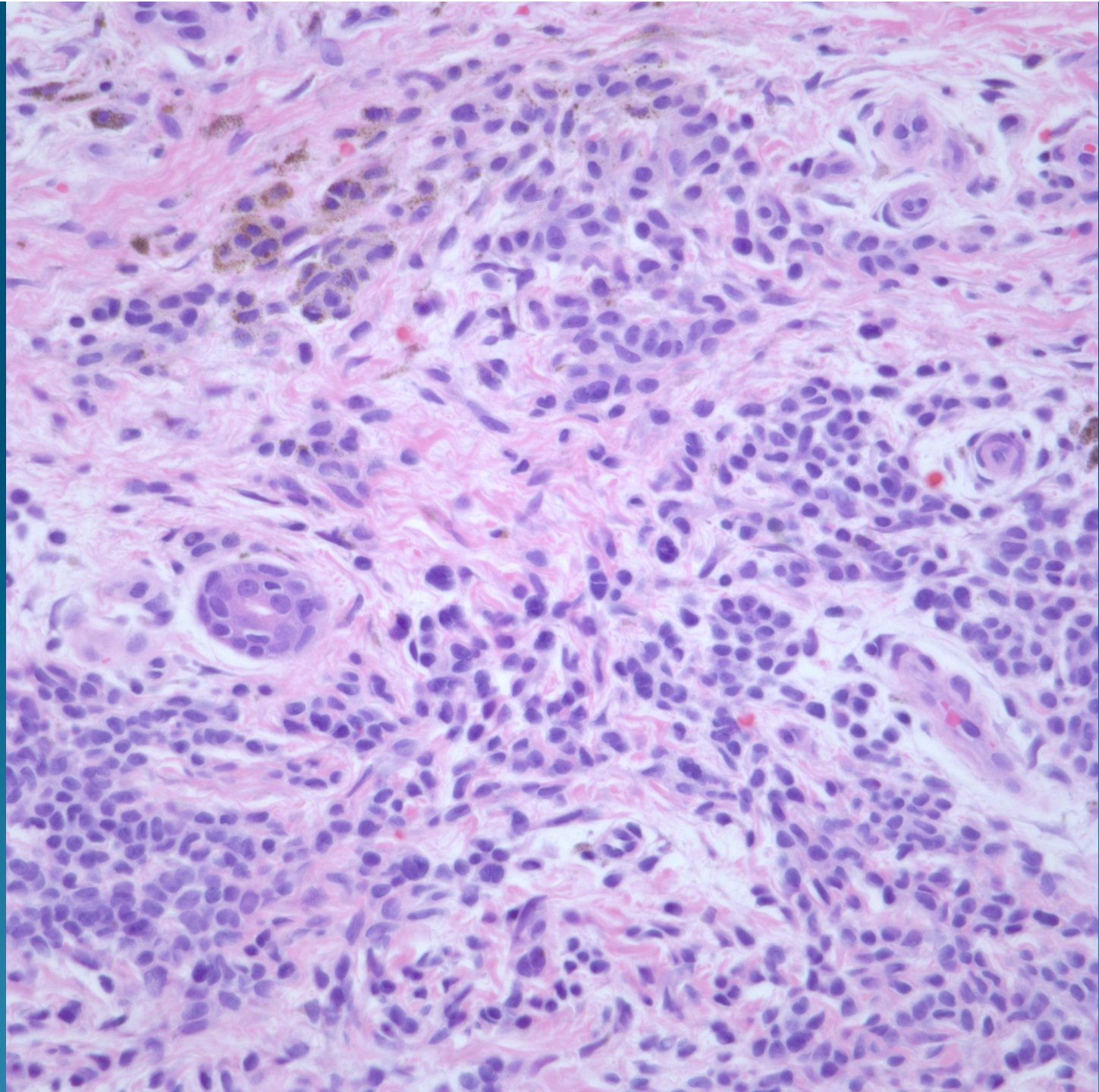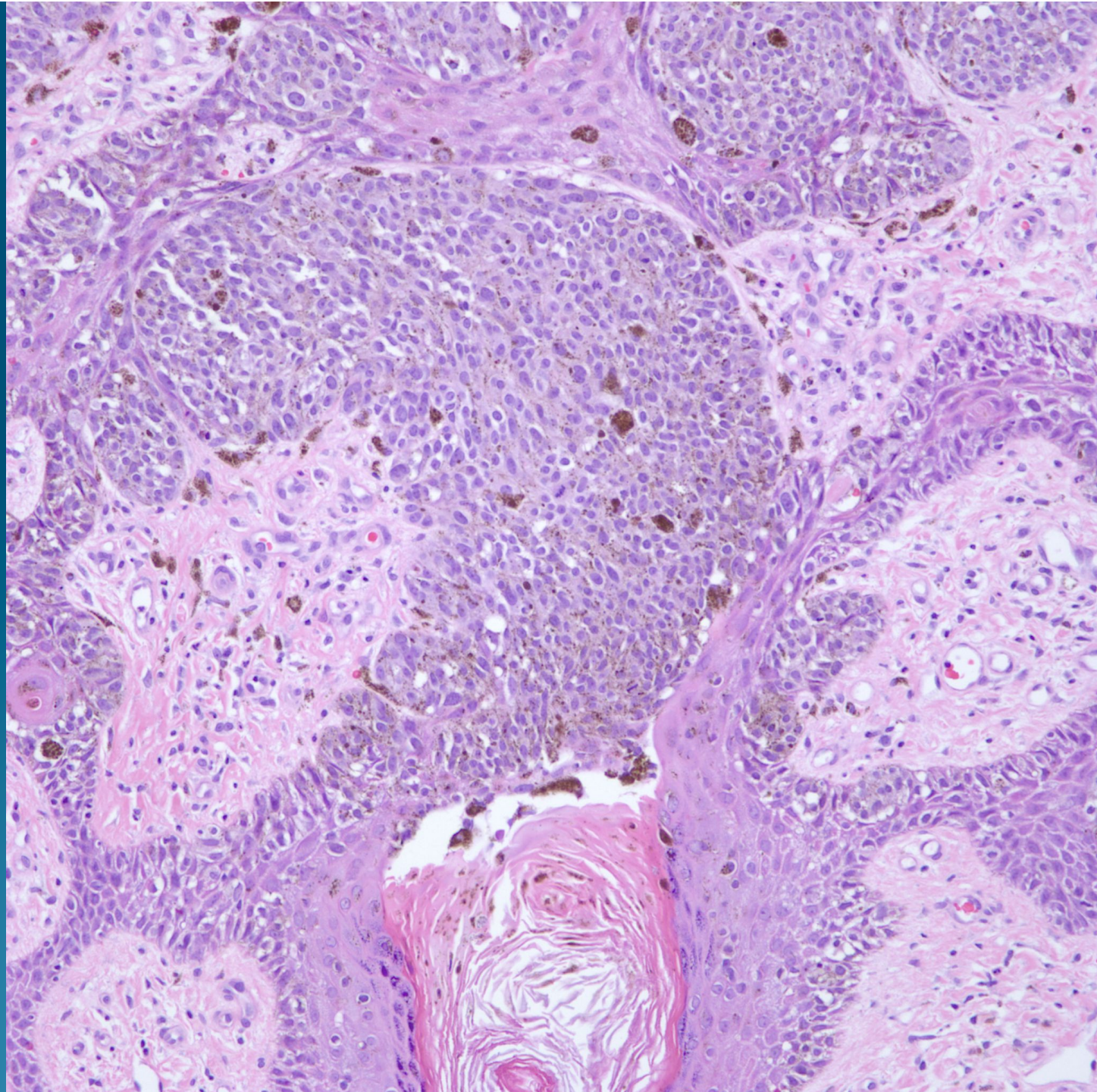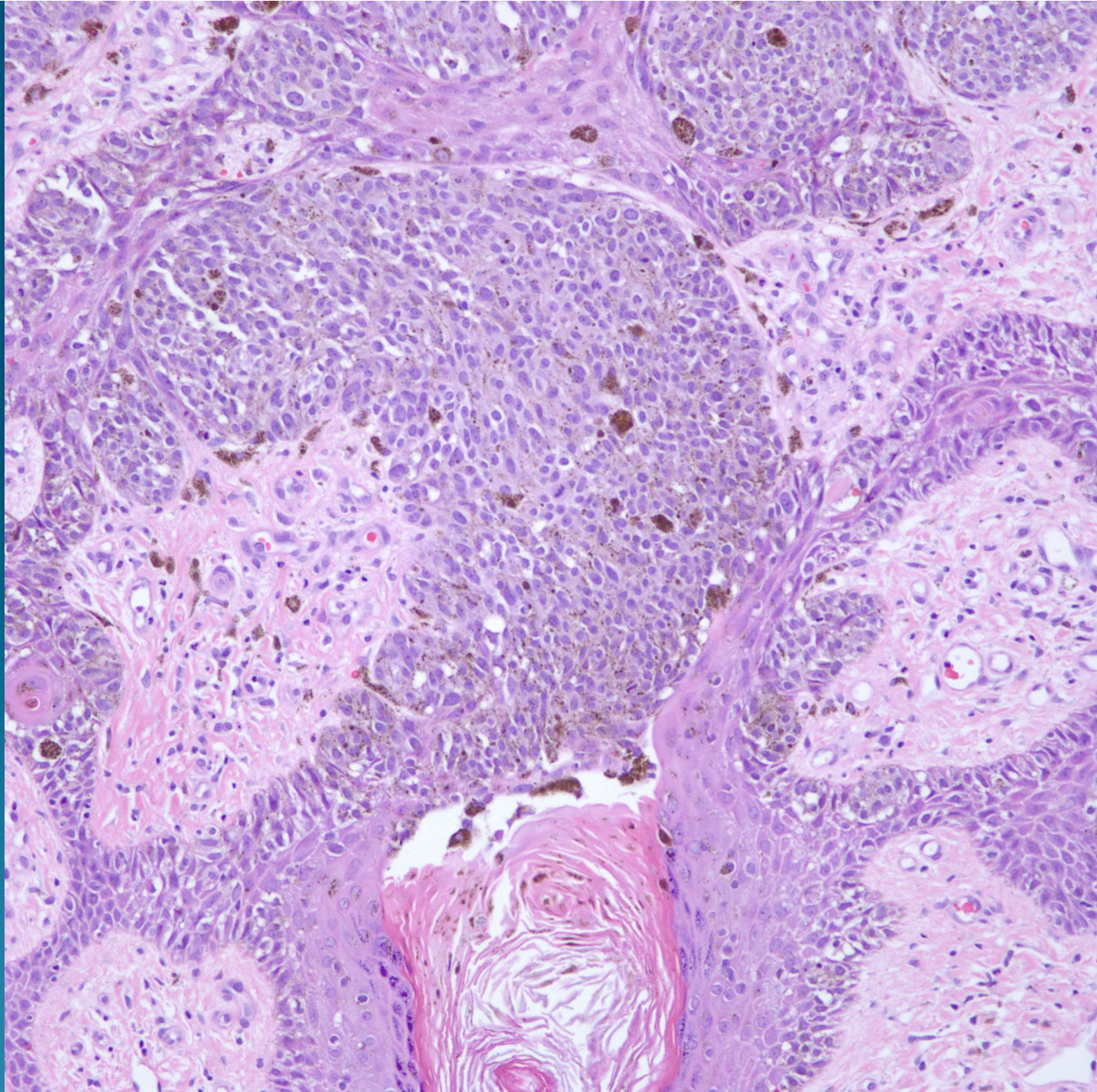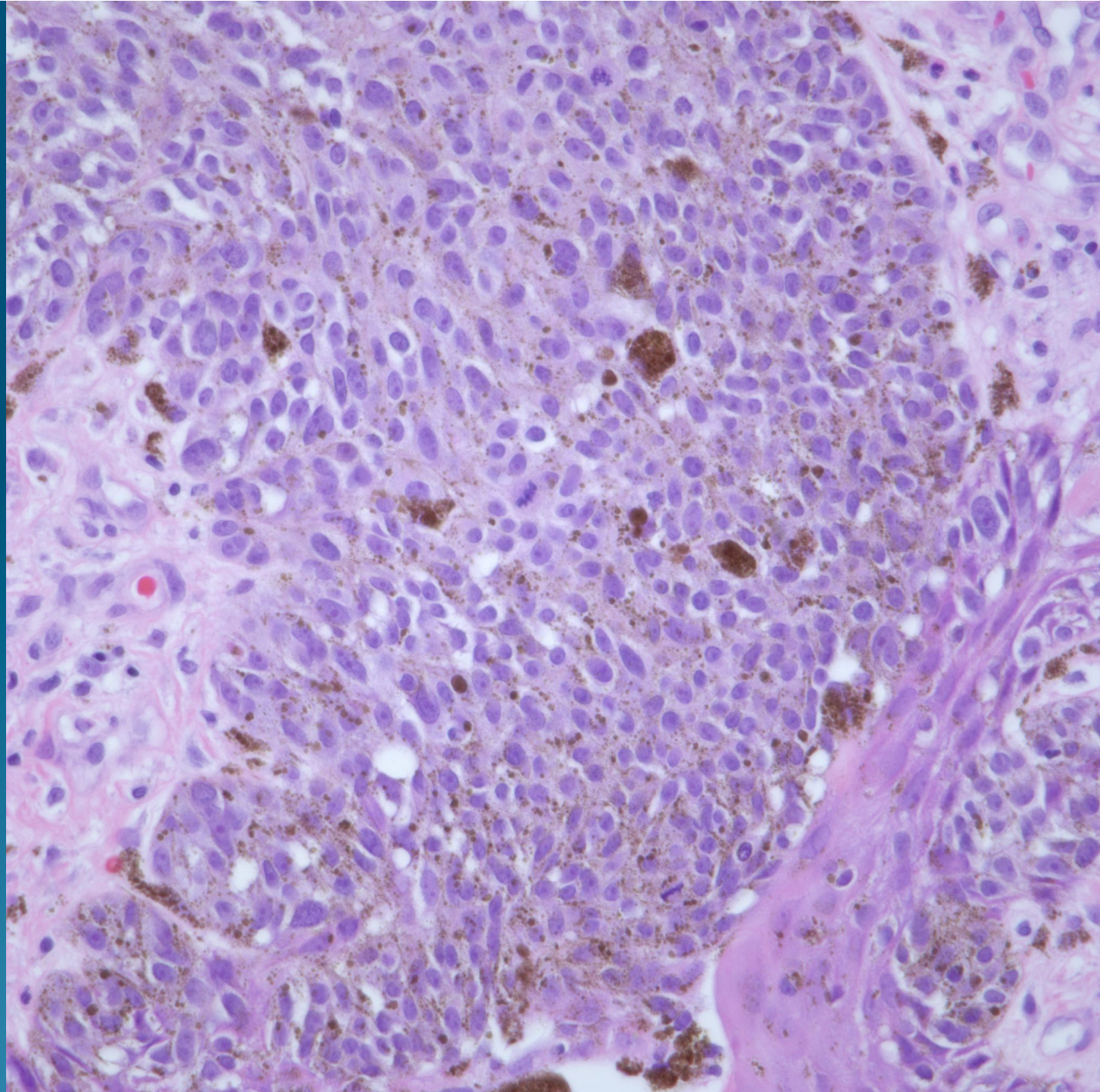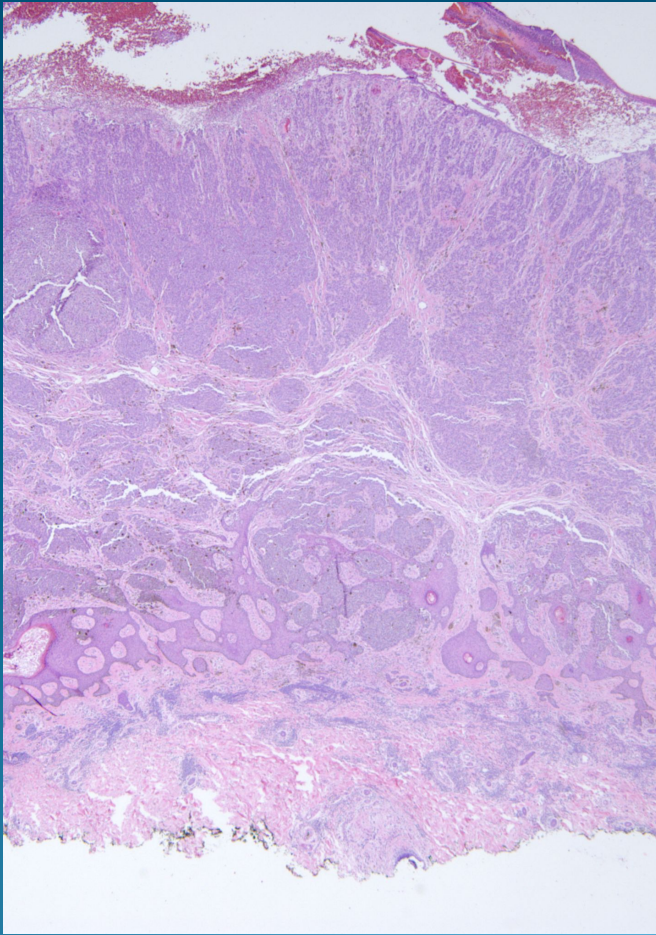


Malignant Melanoma Arising with Pre-existing melanocytic nevus

Pearls



- Melanocytic nevus may be admixed with melanoma
- Cytology usually distinct between melanoma and nevus cells however, absolute distinction may be difficult in select cases
- FISH may be helpful adjunct with micro-dissection of interface areas