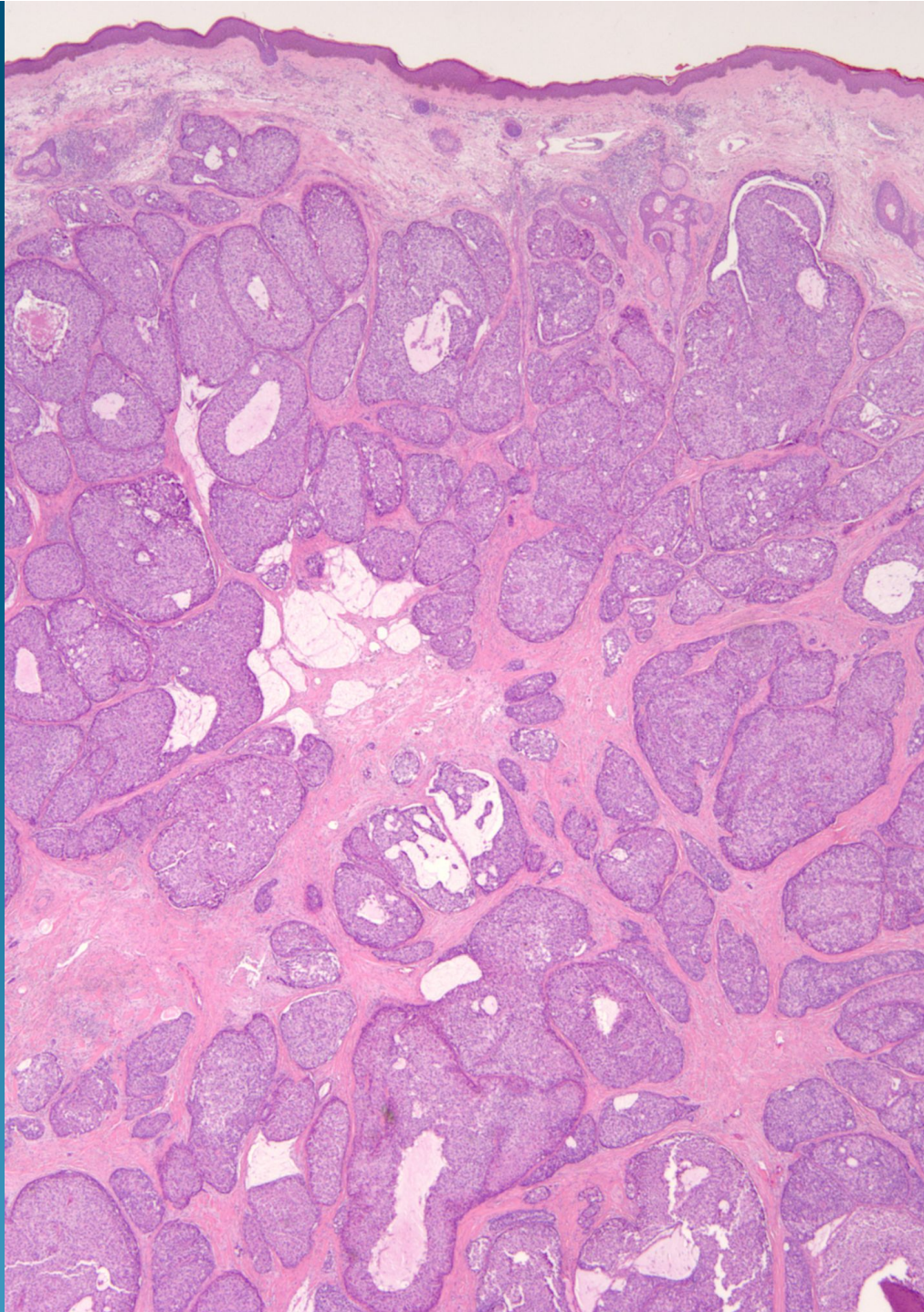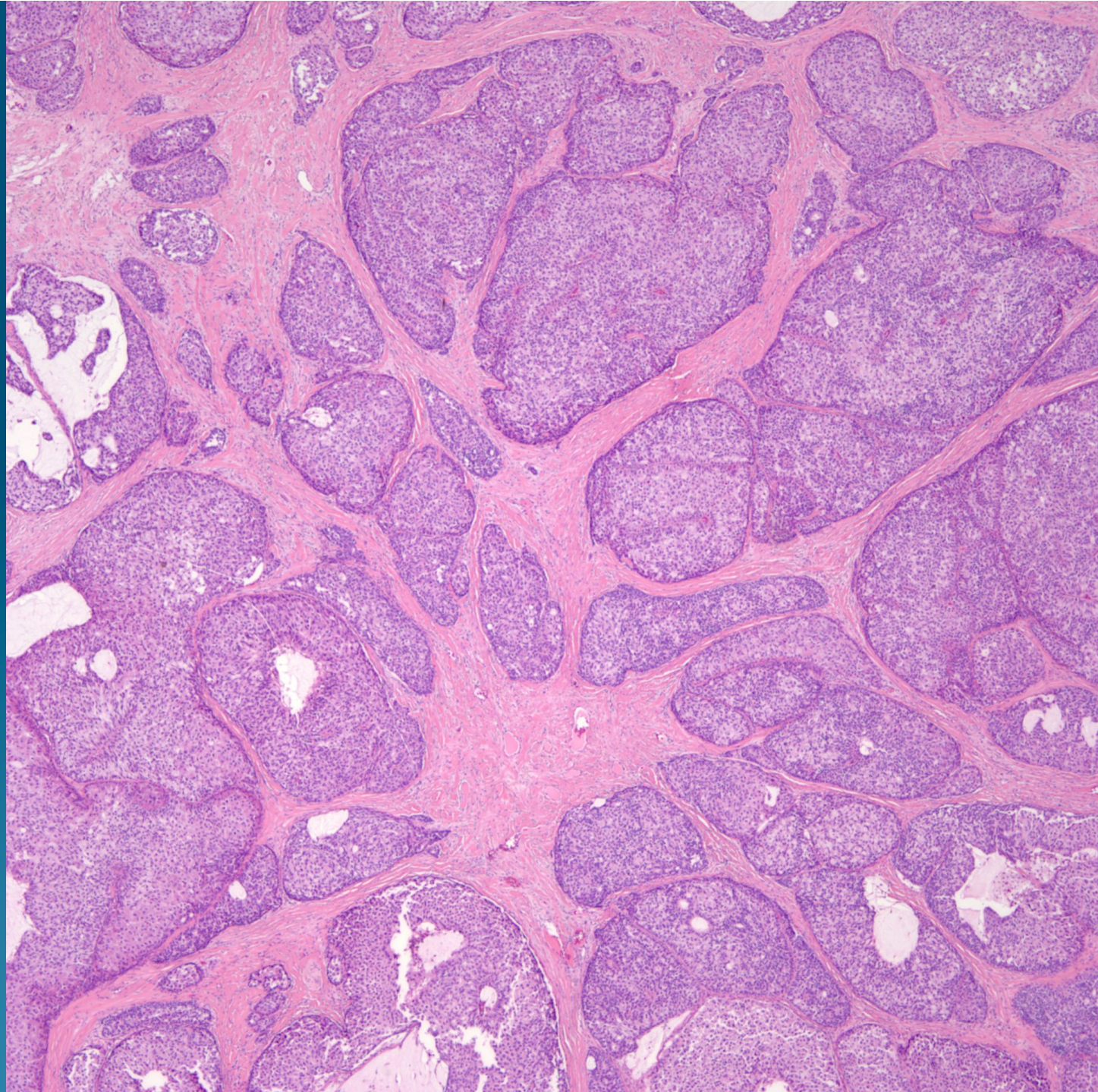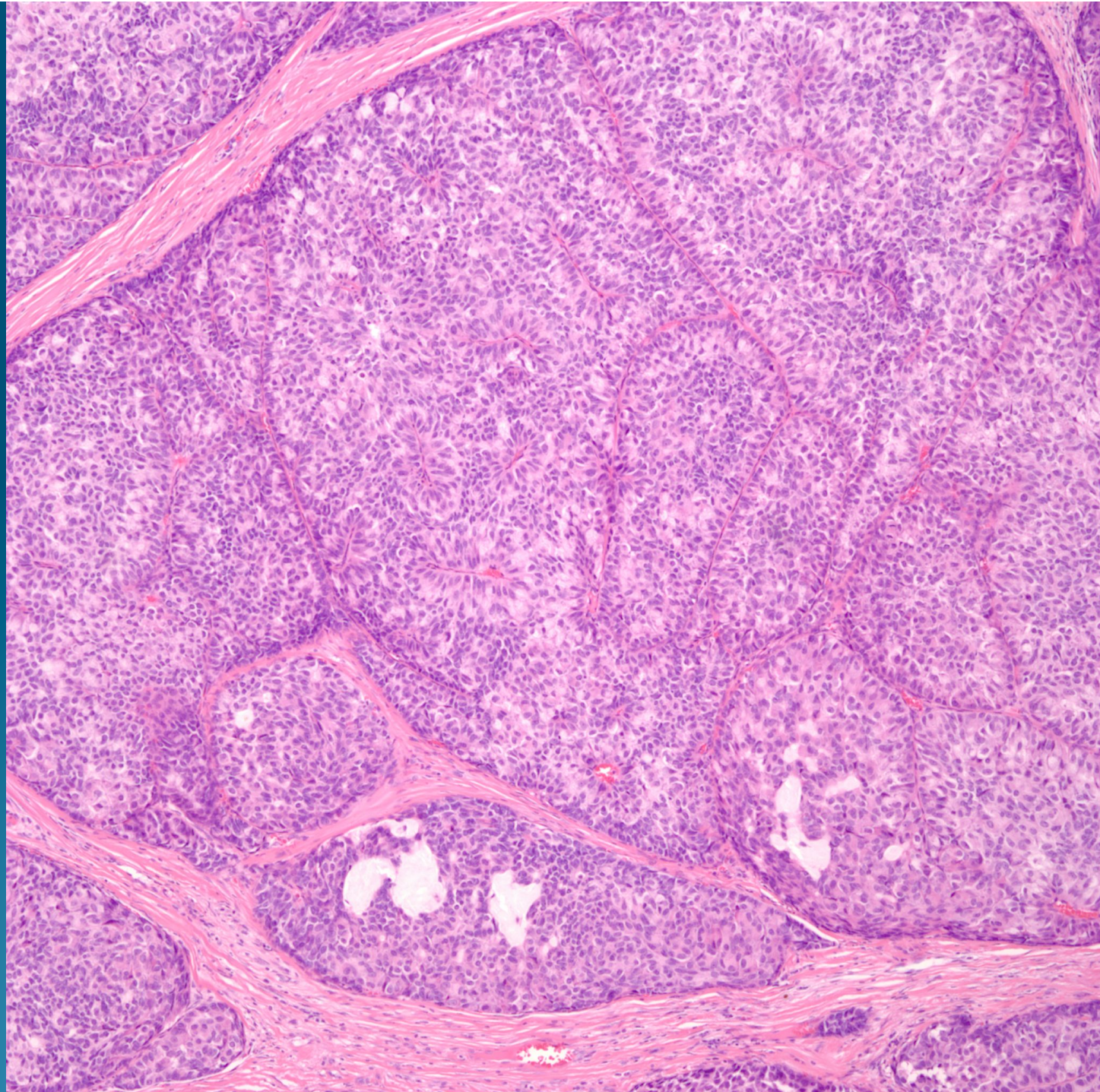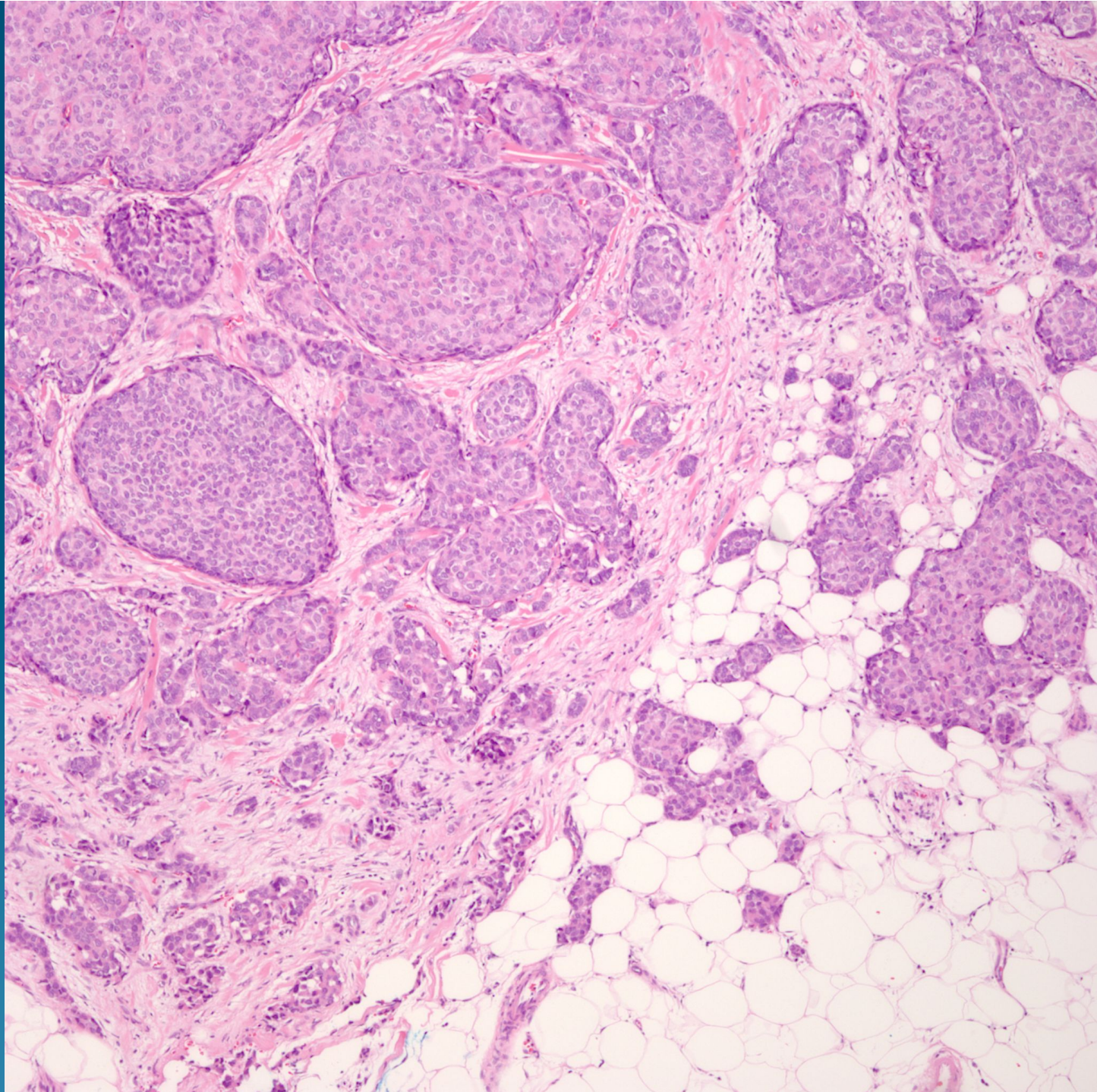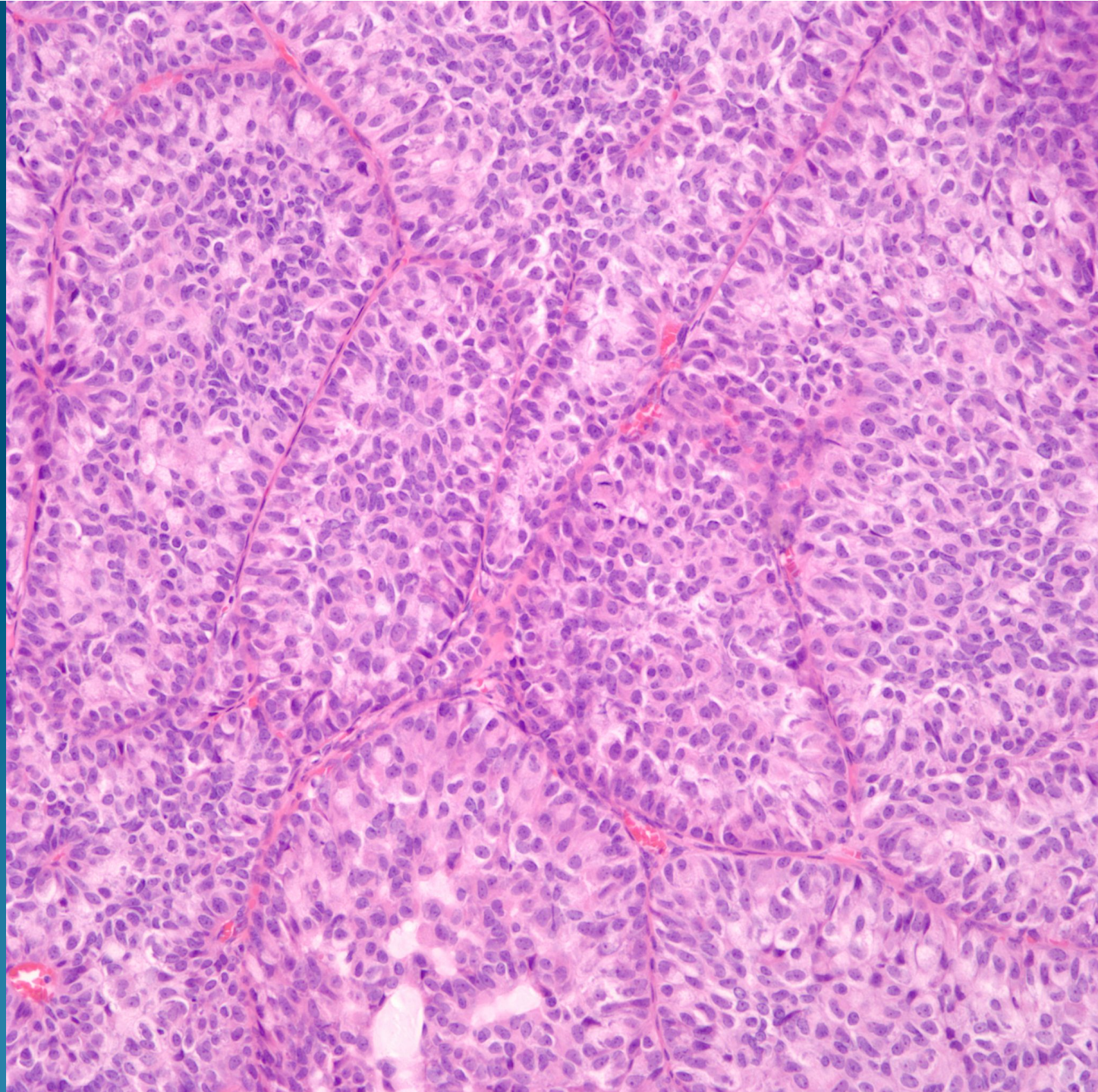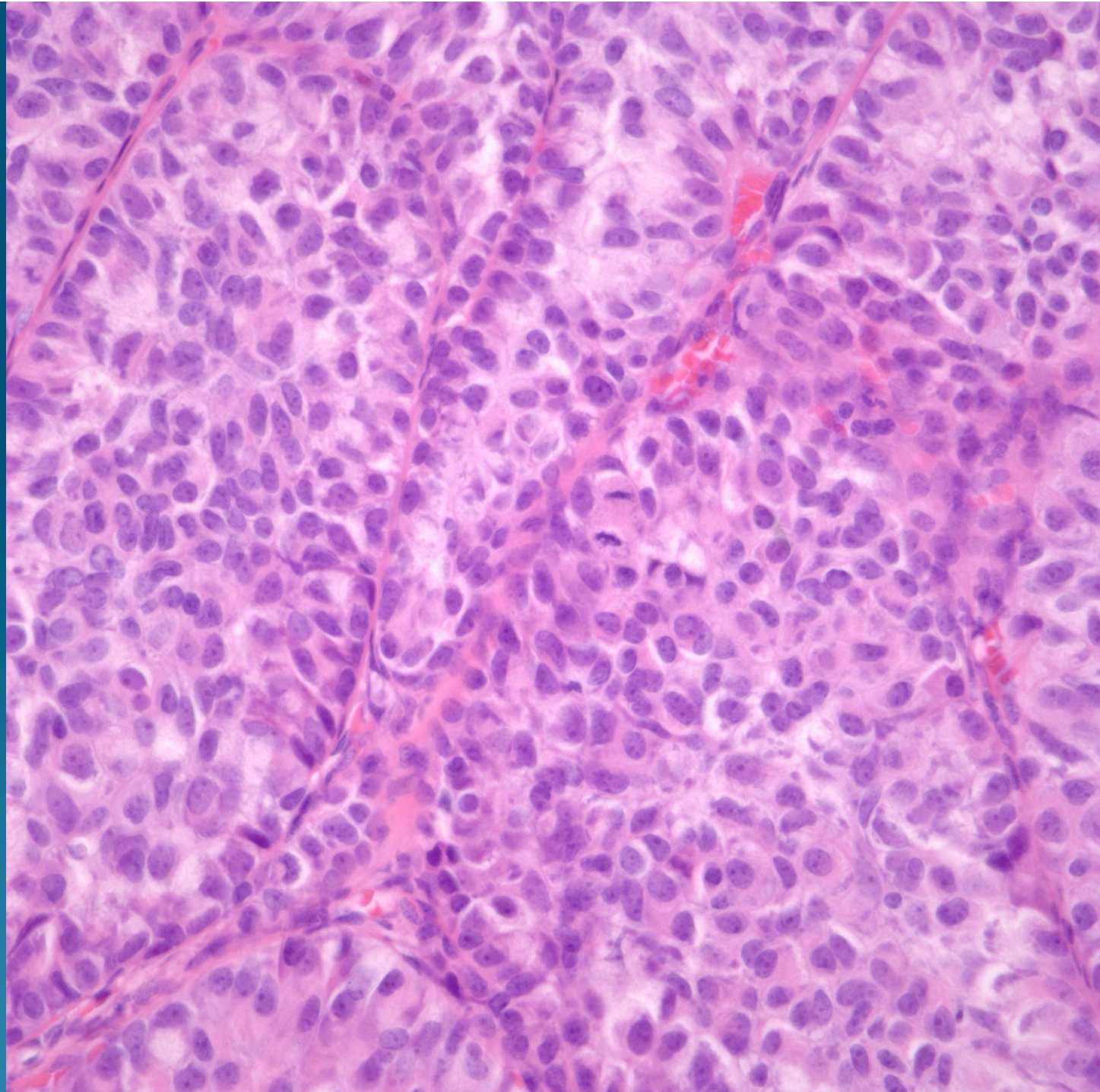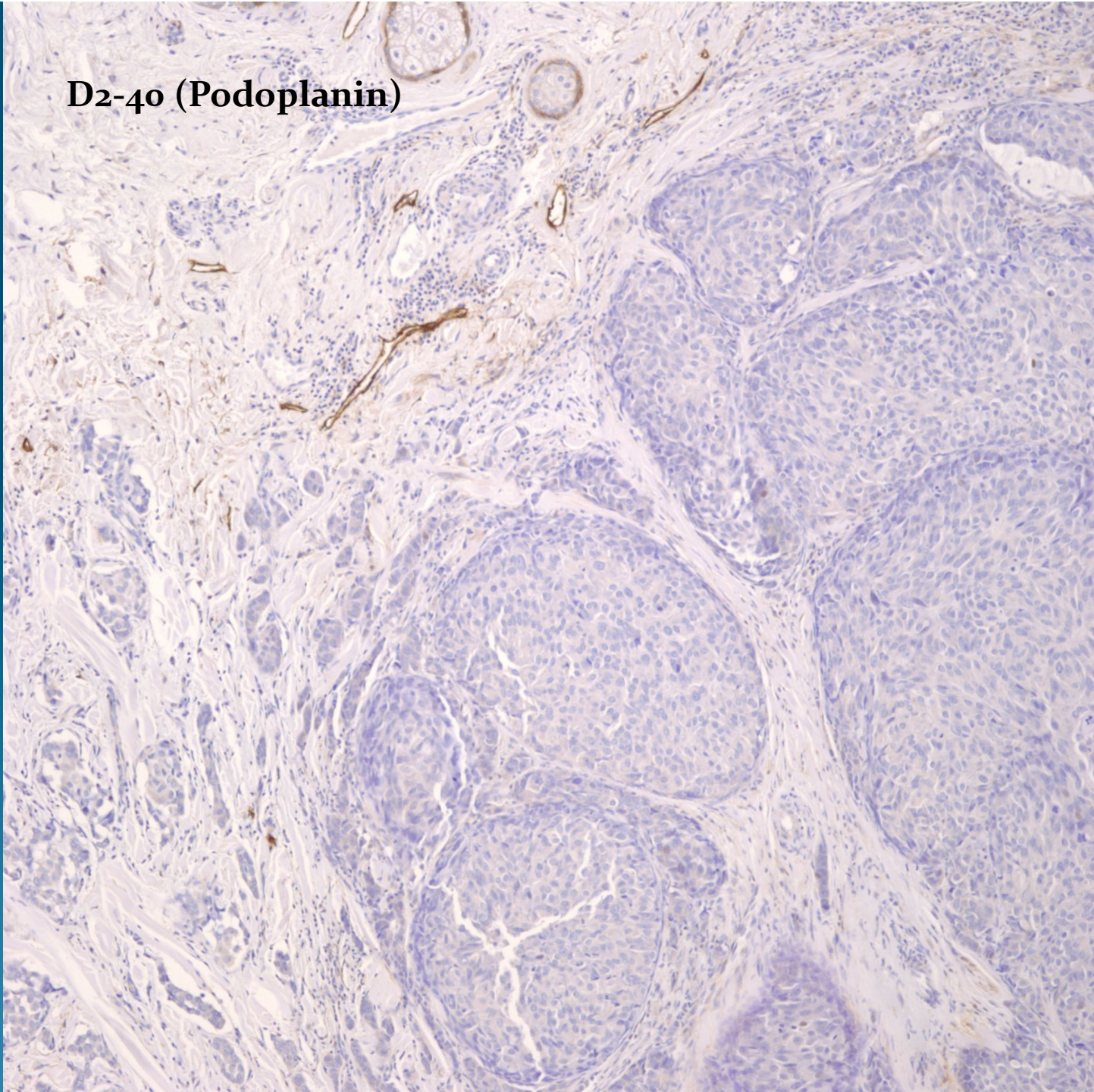


**D2-40 (Podoplanin)**



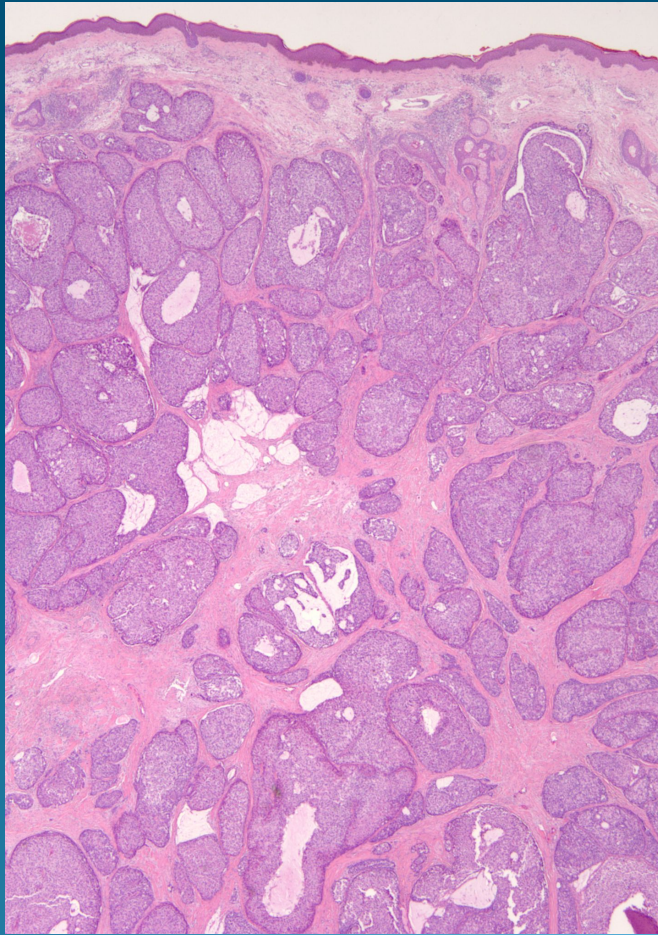
# What is the best diagnosis?

- A. Porocarcinoma
- B. Metastatic adenocarcinoma
- C. Basal Cell Carcinoma
- D. Pilomatrical Carcinoma
- E. Epithelioid Angiosarcoma



# Metastatic Adenocarcinoma- Unknown Primary

# Pearls



- Metastatic adenocarcinoma may mimic primary adnexal carcinomas
- Ultimate diagnosis may rest upon clinical-pathologic correlation
- IHC may be helpful
- D2-40 and p63 recently found to be positive in large series of primary skin adnexal carcinomas and negative in metastatic adenocarcinomas to the skin