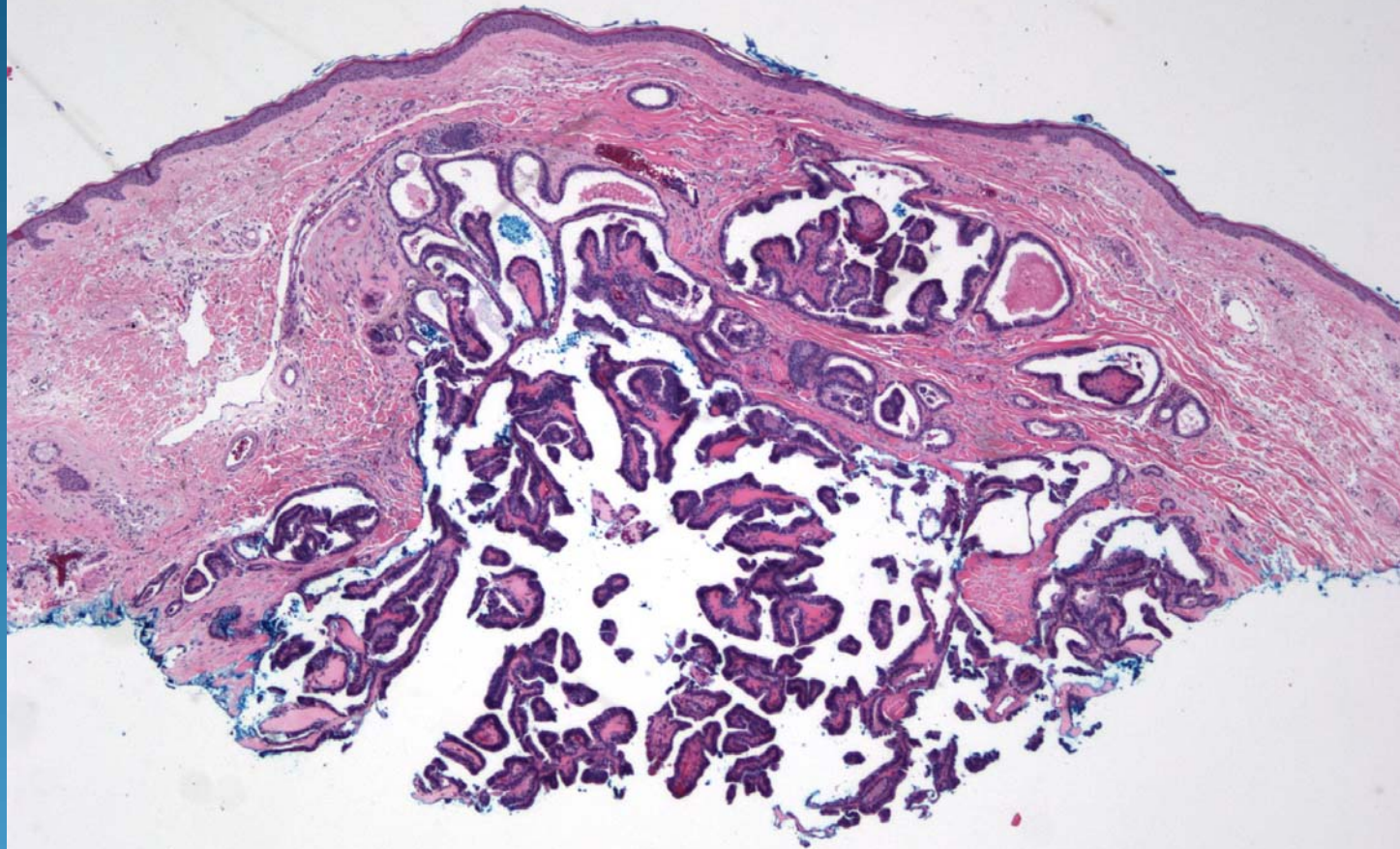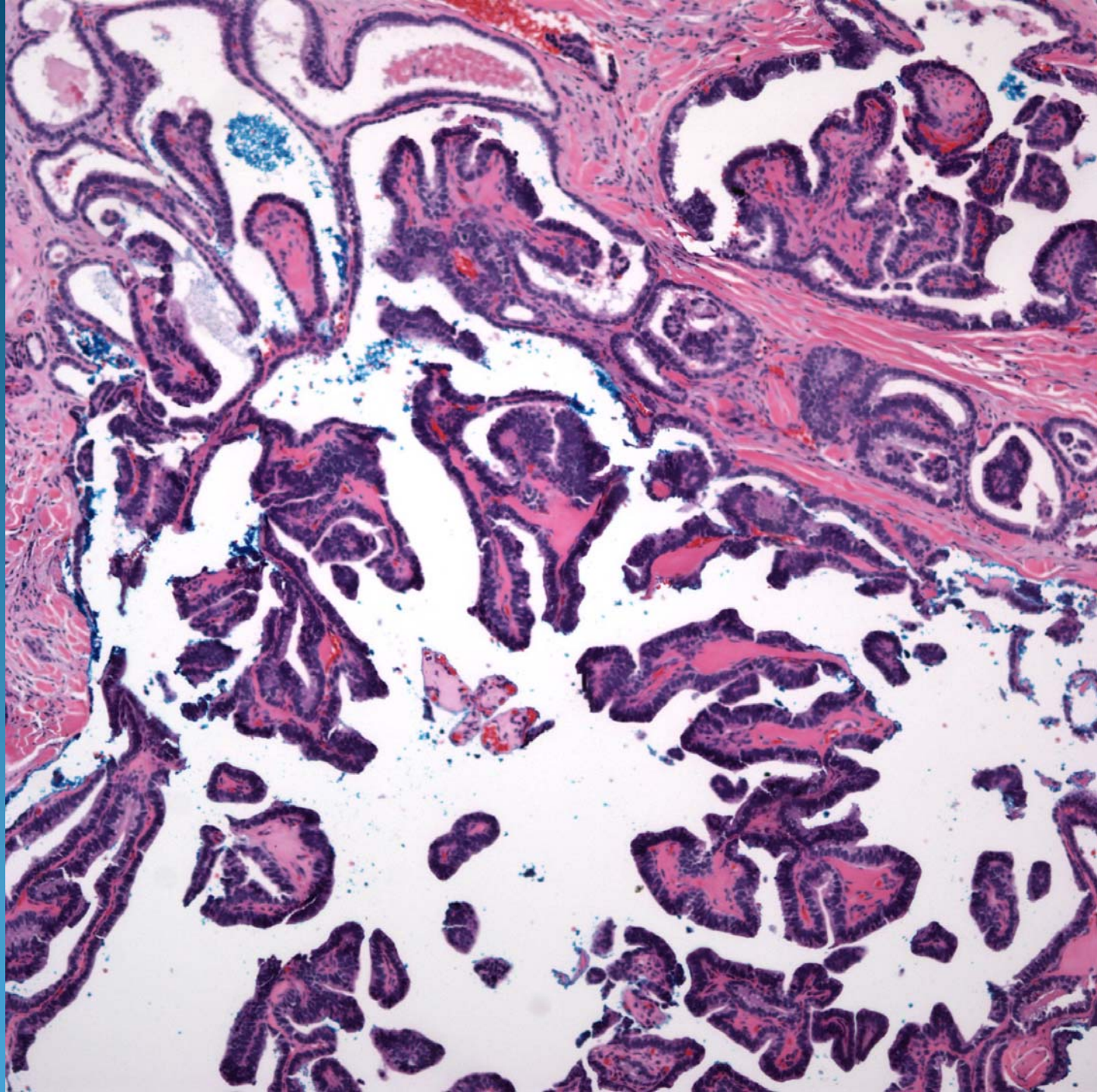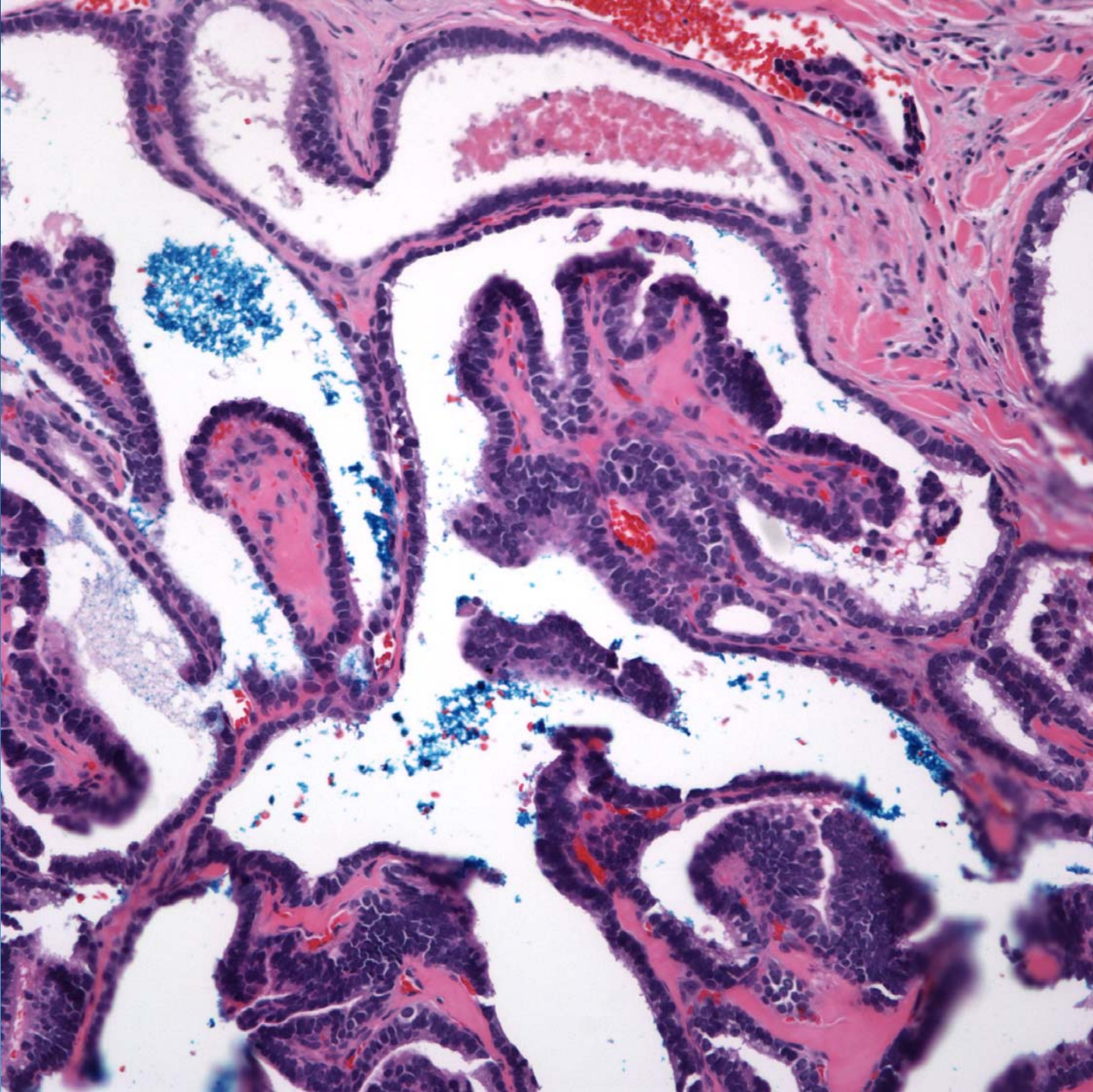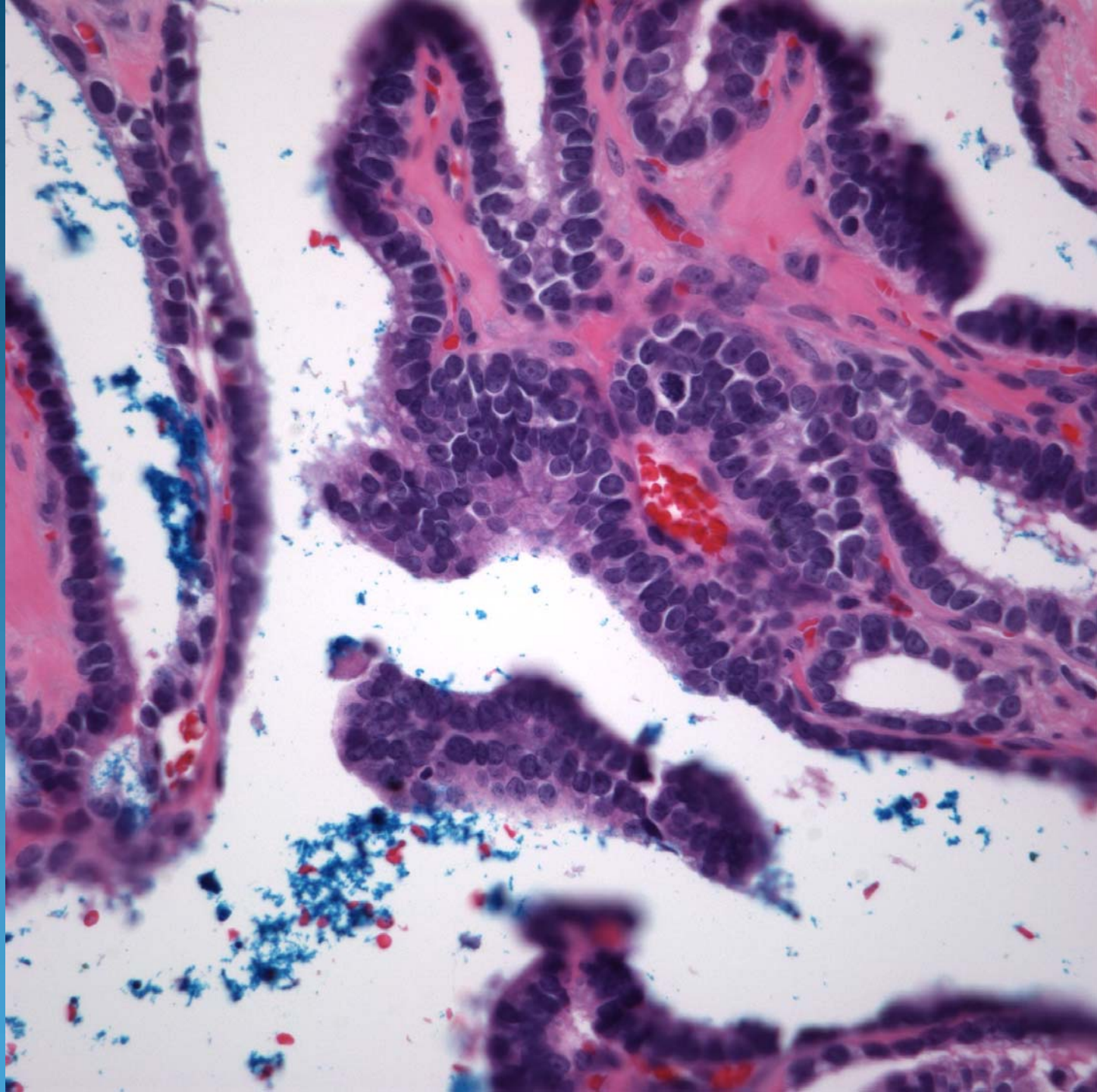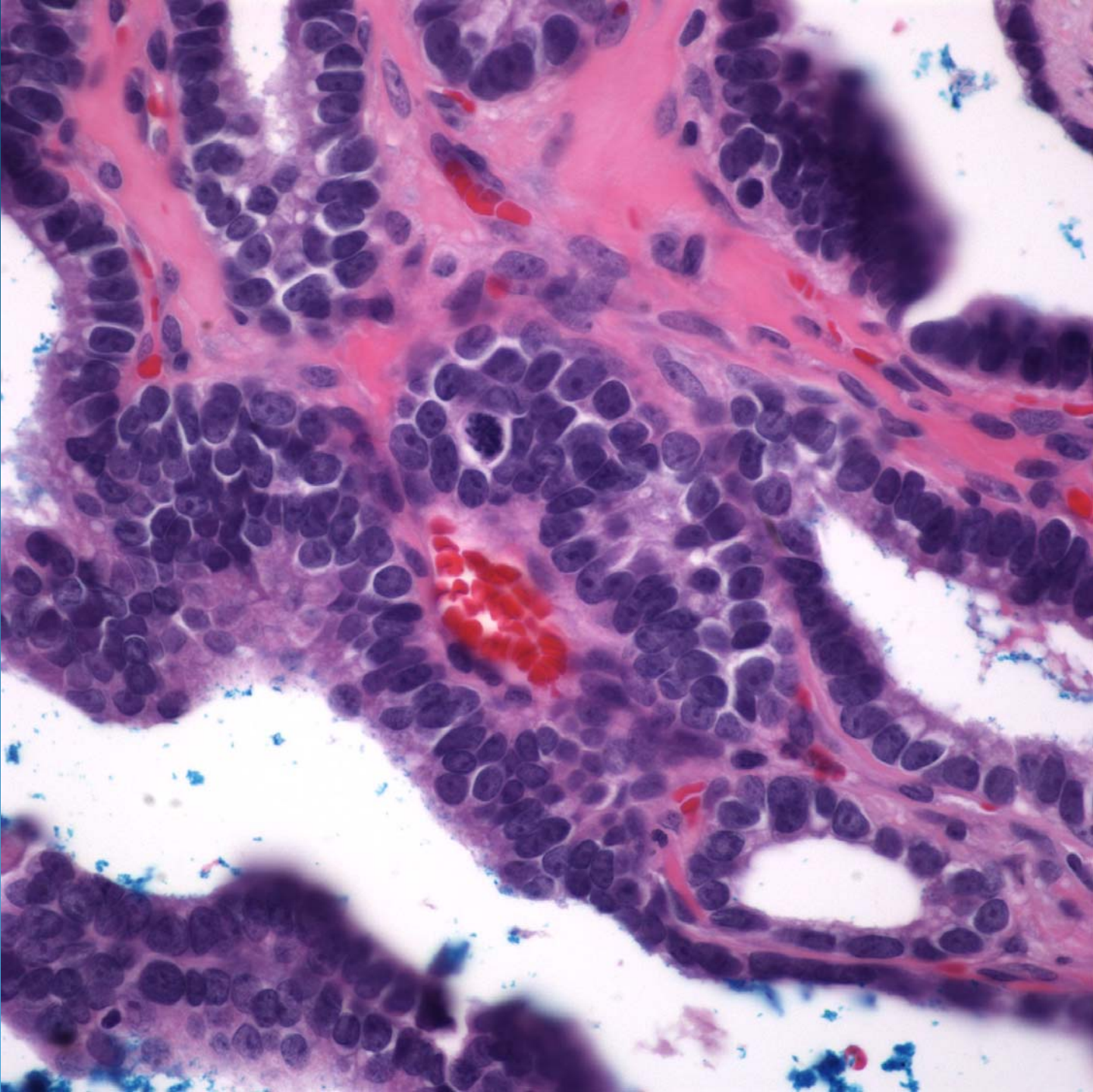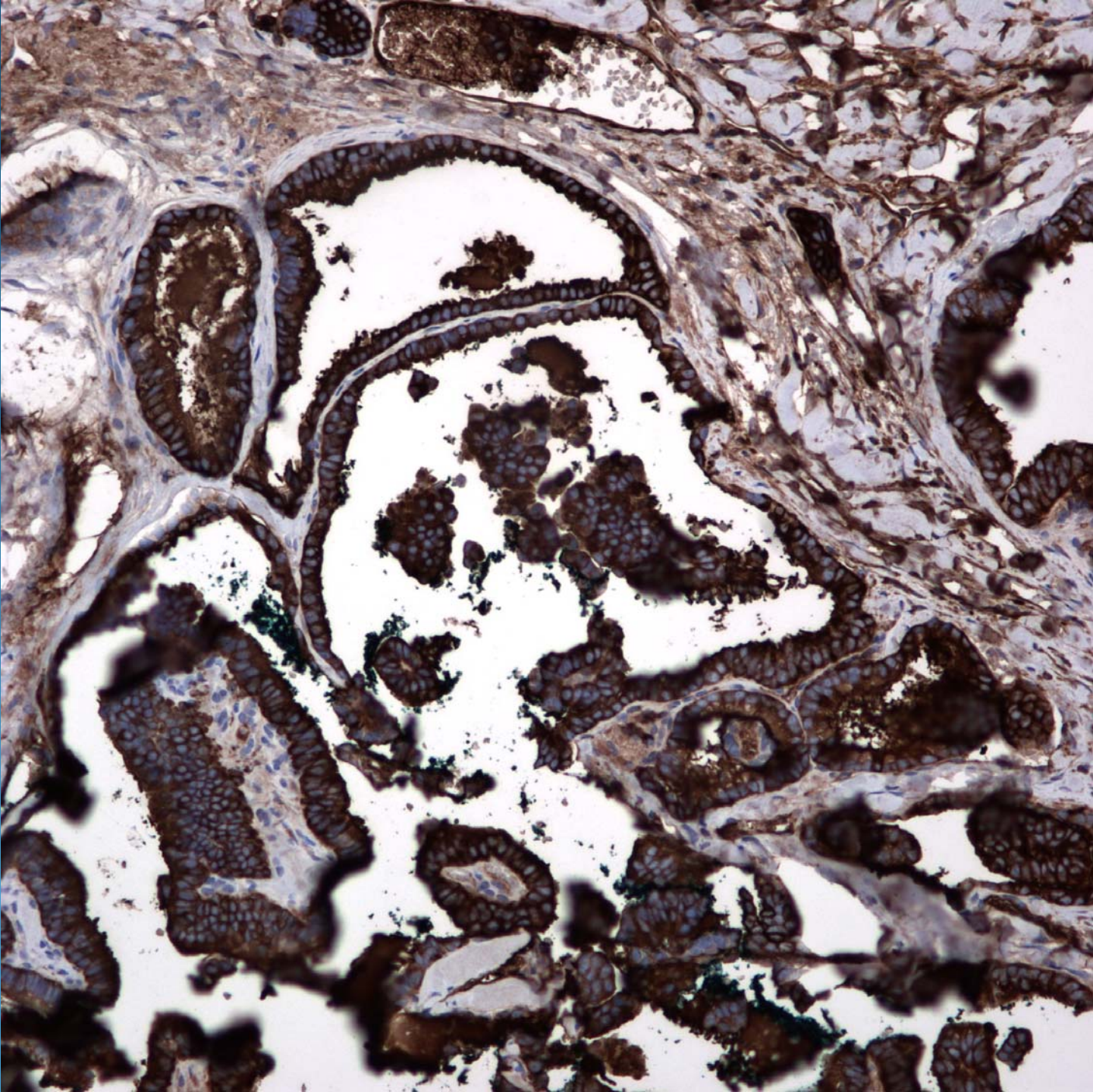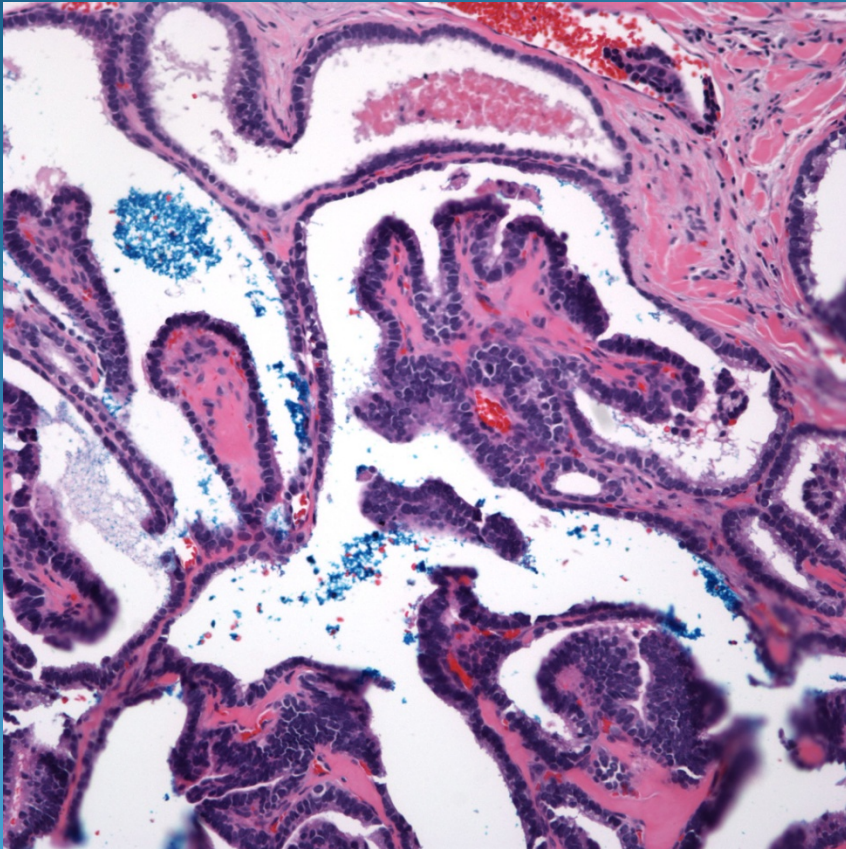


Metastatic Papillary  
Adenocarcinoma, Thyroid Primary



# Pearls



- Primary papillary carcinomas of the skin are exceedingly rare
- Look for true fibrovascular cores
- Metastatic carcinoma until proven otherwise
- May need IHC to confirm organ of origin