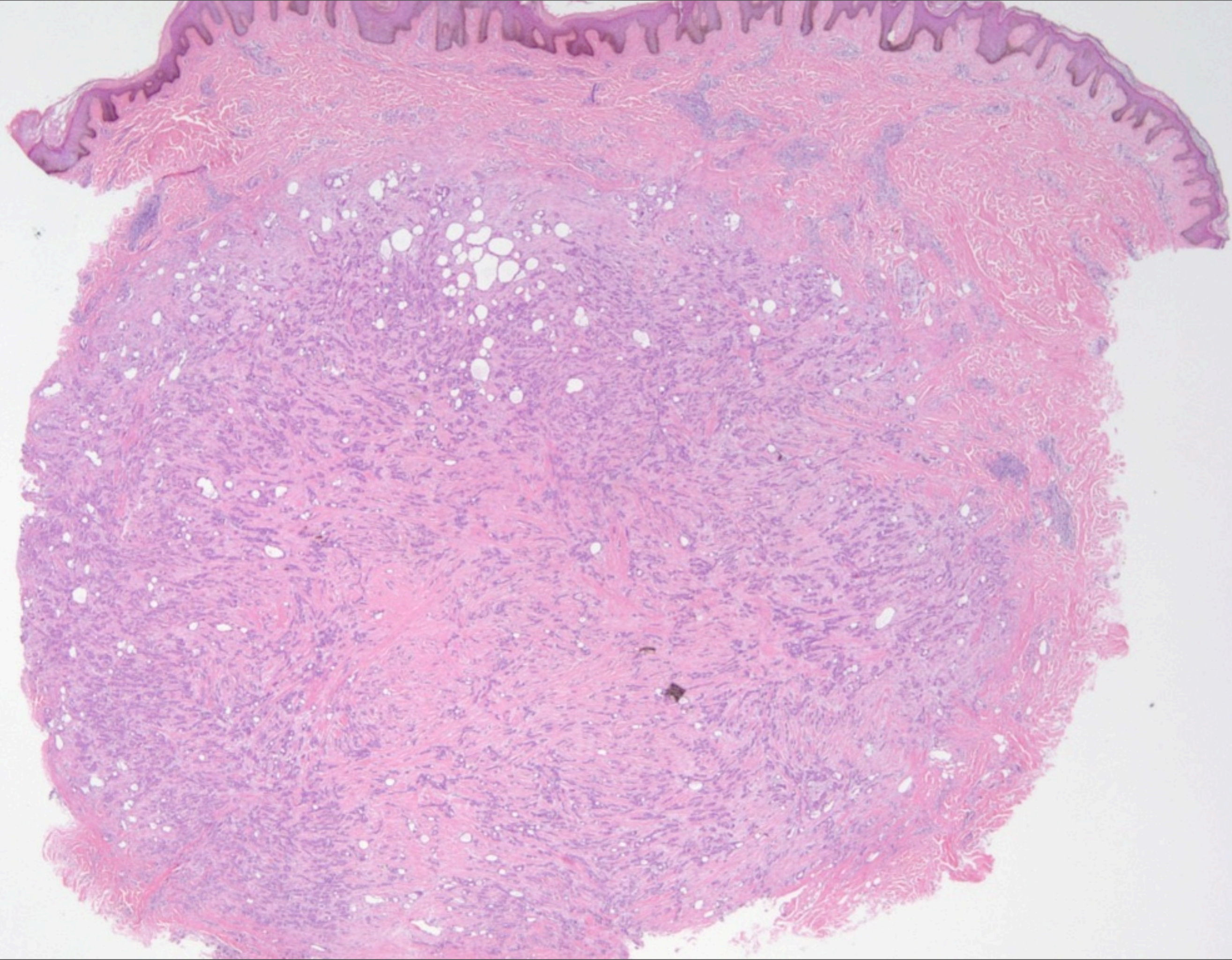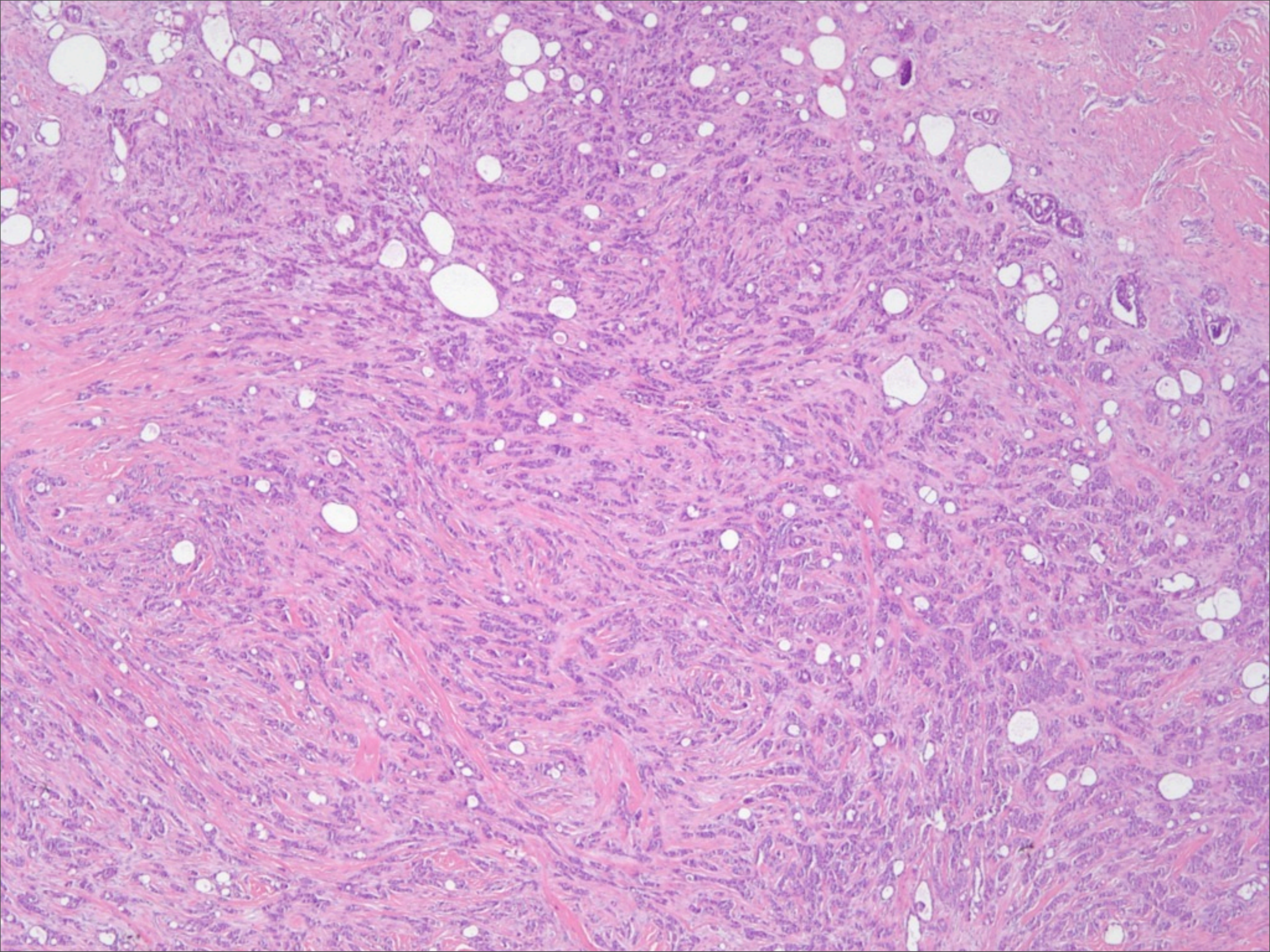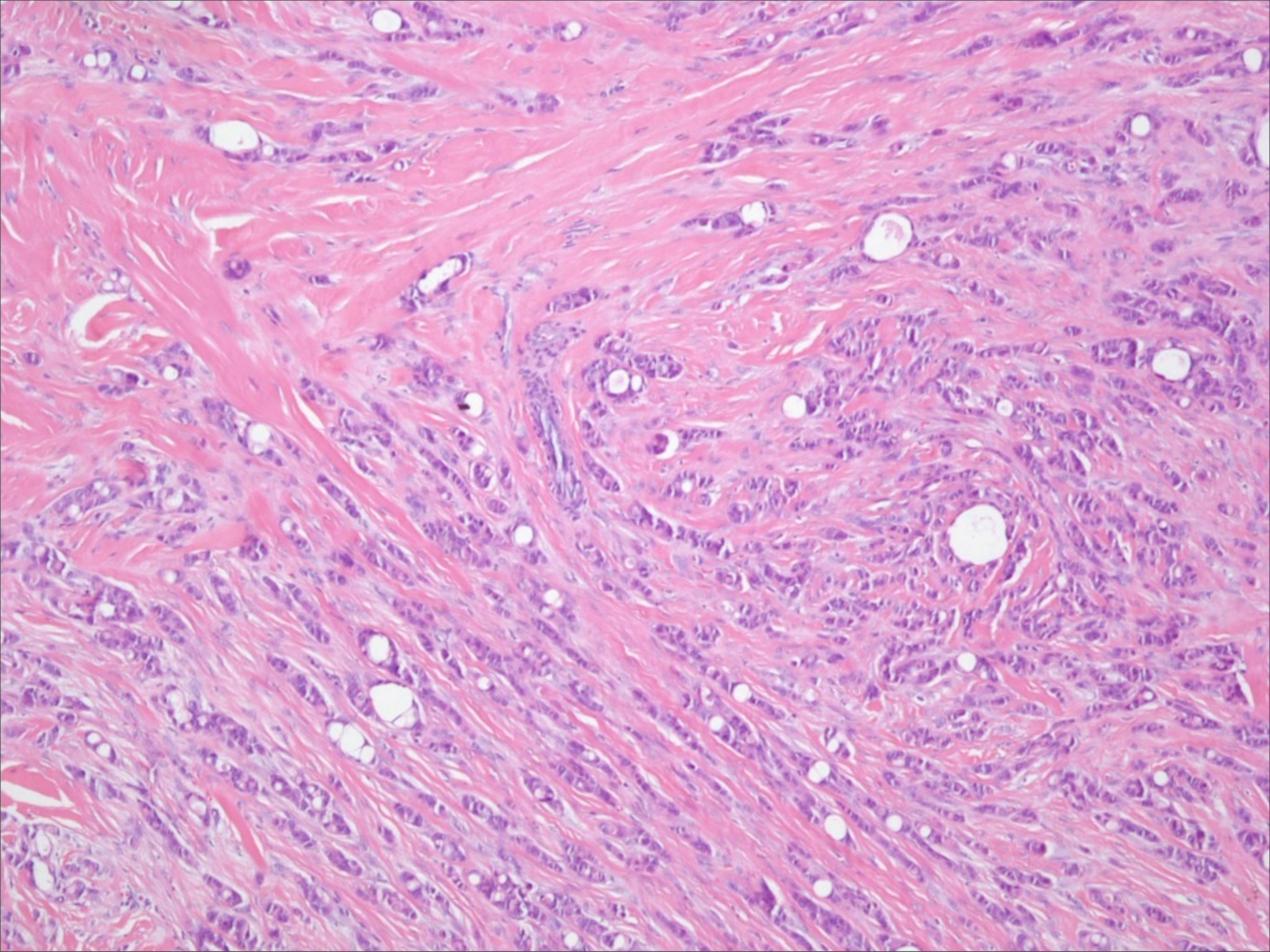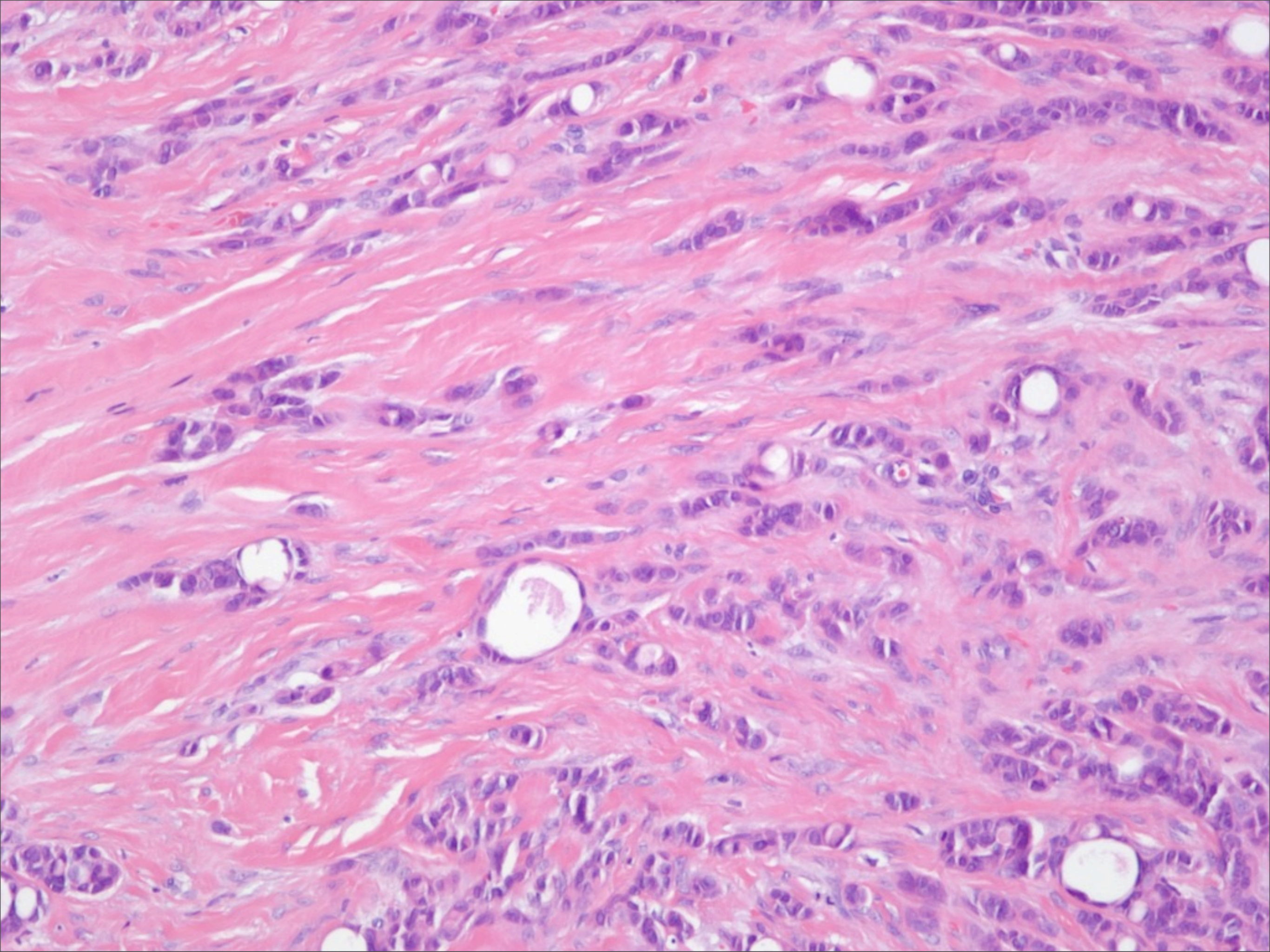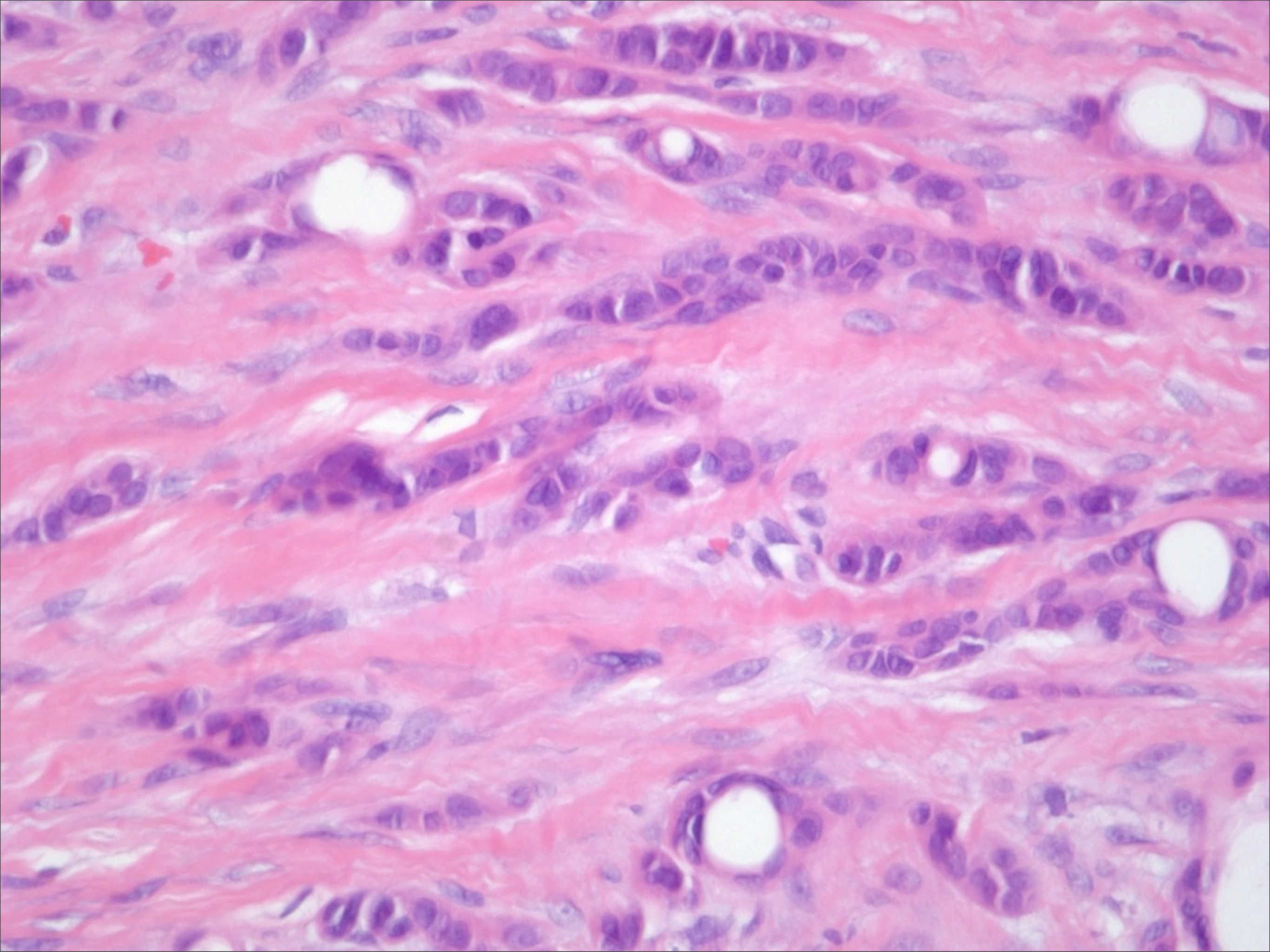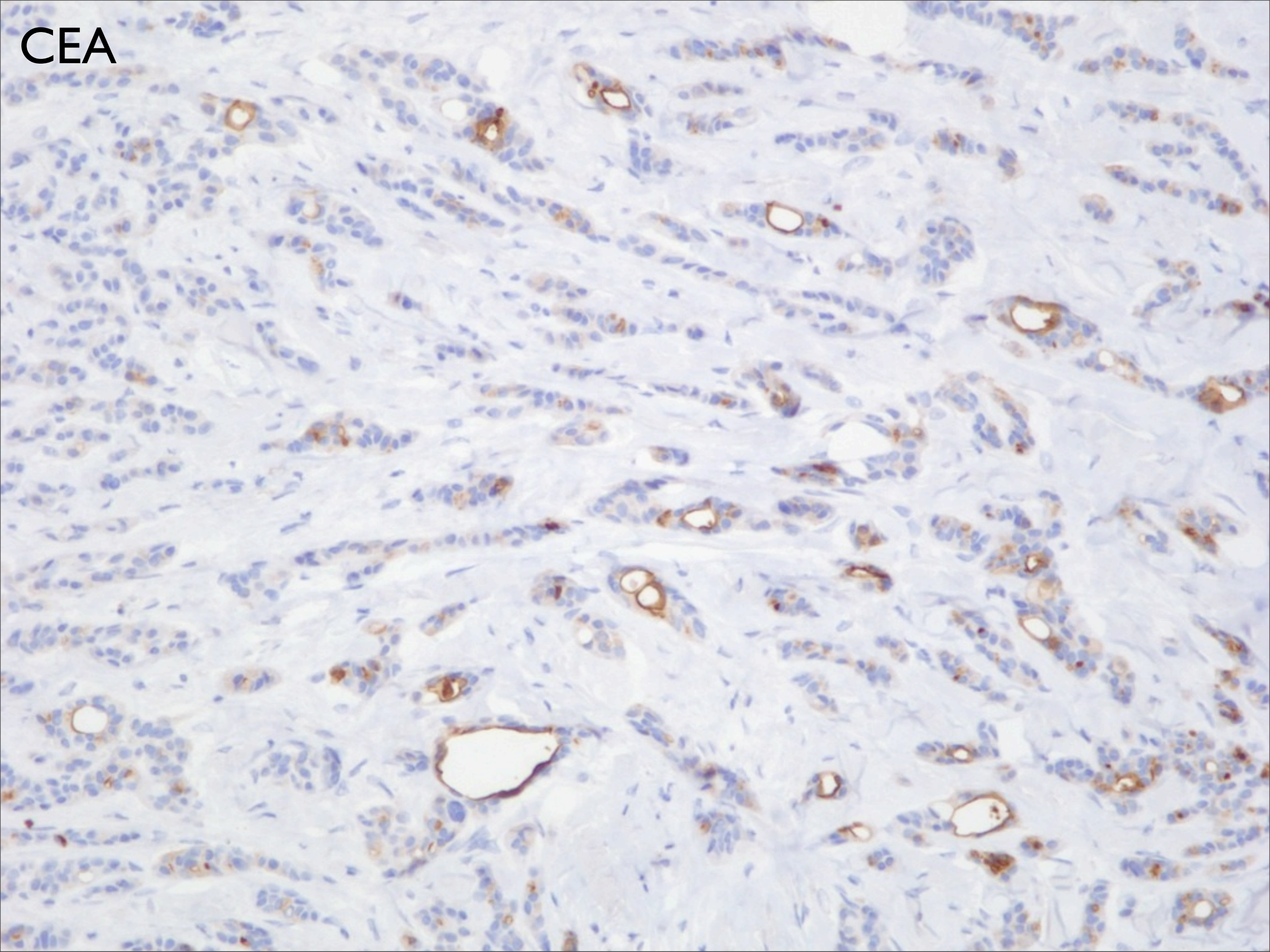
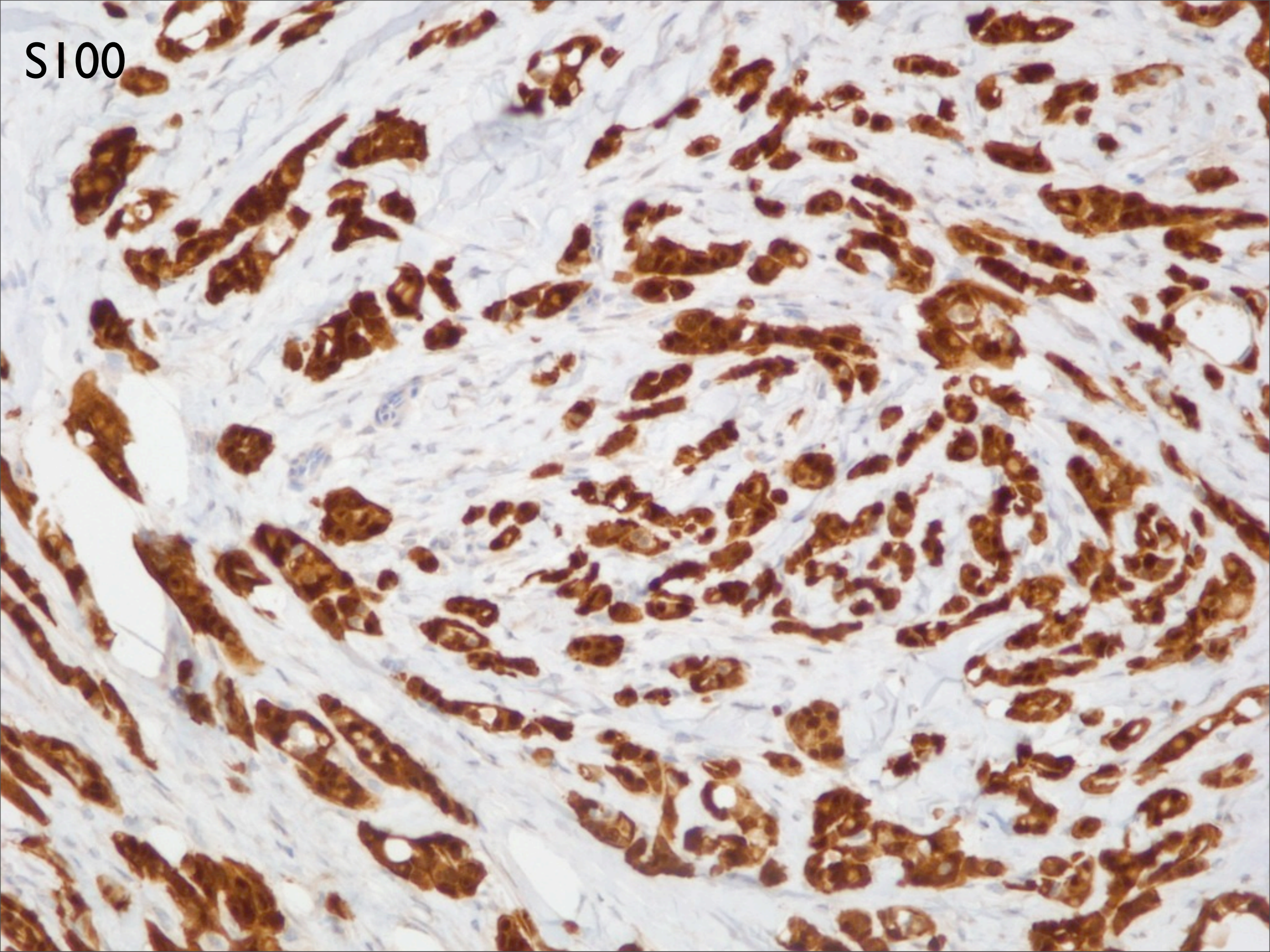


CEA



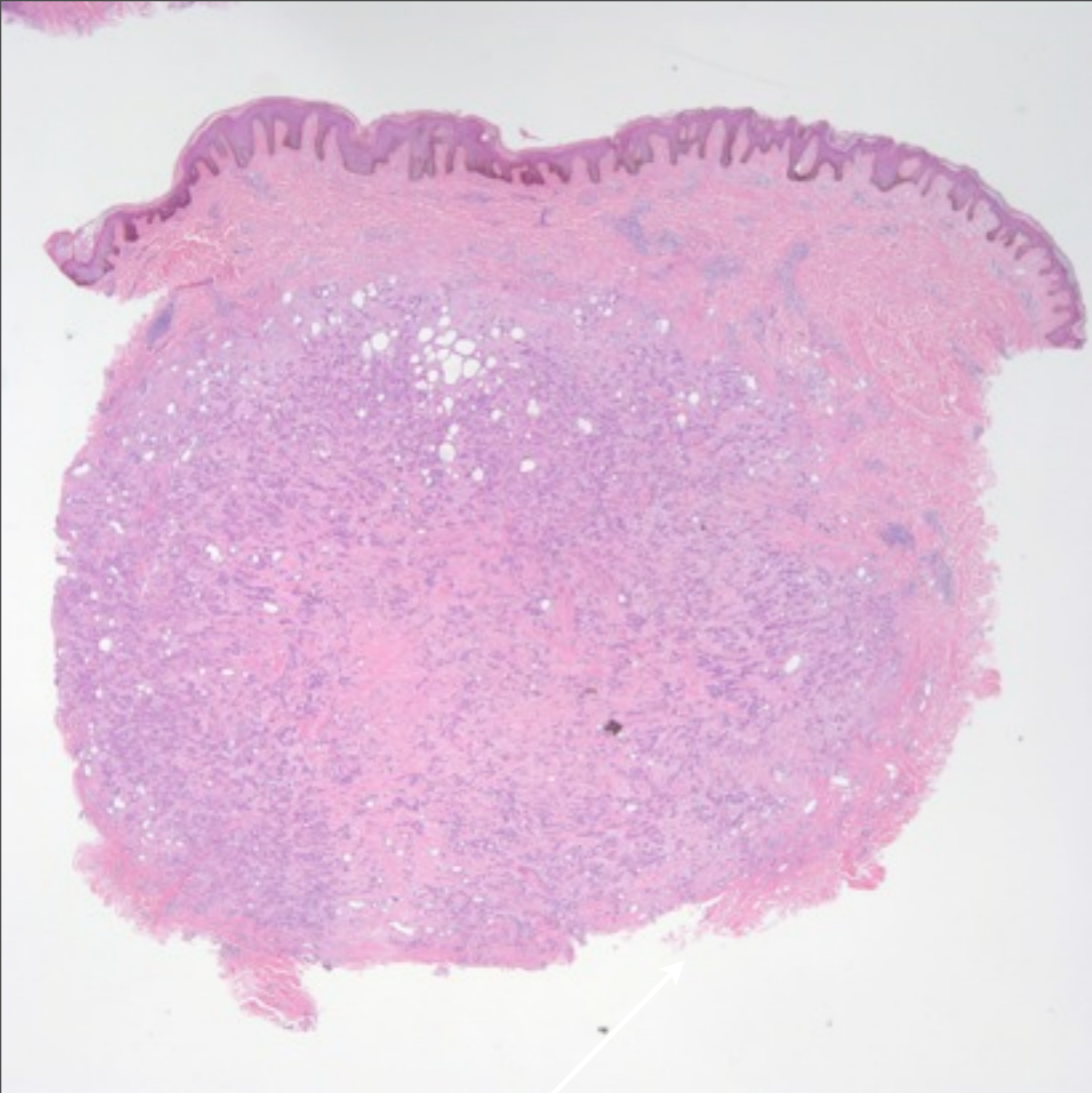
S100



Microcystic Adnexal Carcinoma (Sclerosing Sweat Duct

Notes

- Microcystic adnexal carcinomas are thought to be an adnexal carcinoma showing mixed lineage with eccrine, apocrine, and pilar differentiation noted
- Sclerosing sweat duct carcinoma has been applied to tumors that generally lack pilar differentiation, as in this current case
- Eccrine differentiation supported by glands showing CEA and S100 positivity



Cords and Ductal Structures
Minimal Cytological Pleomorphism

Rare Mitotic Figures

Deeply Infiltrative Tumor

