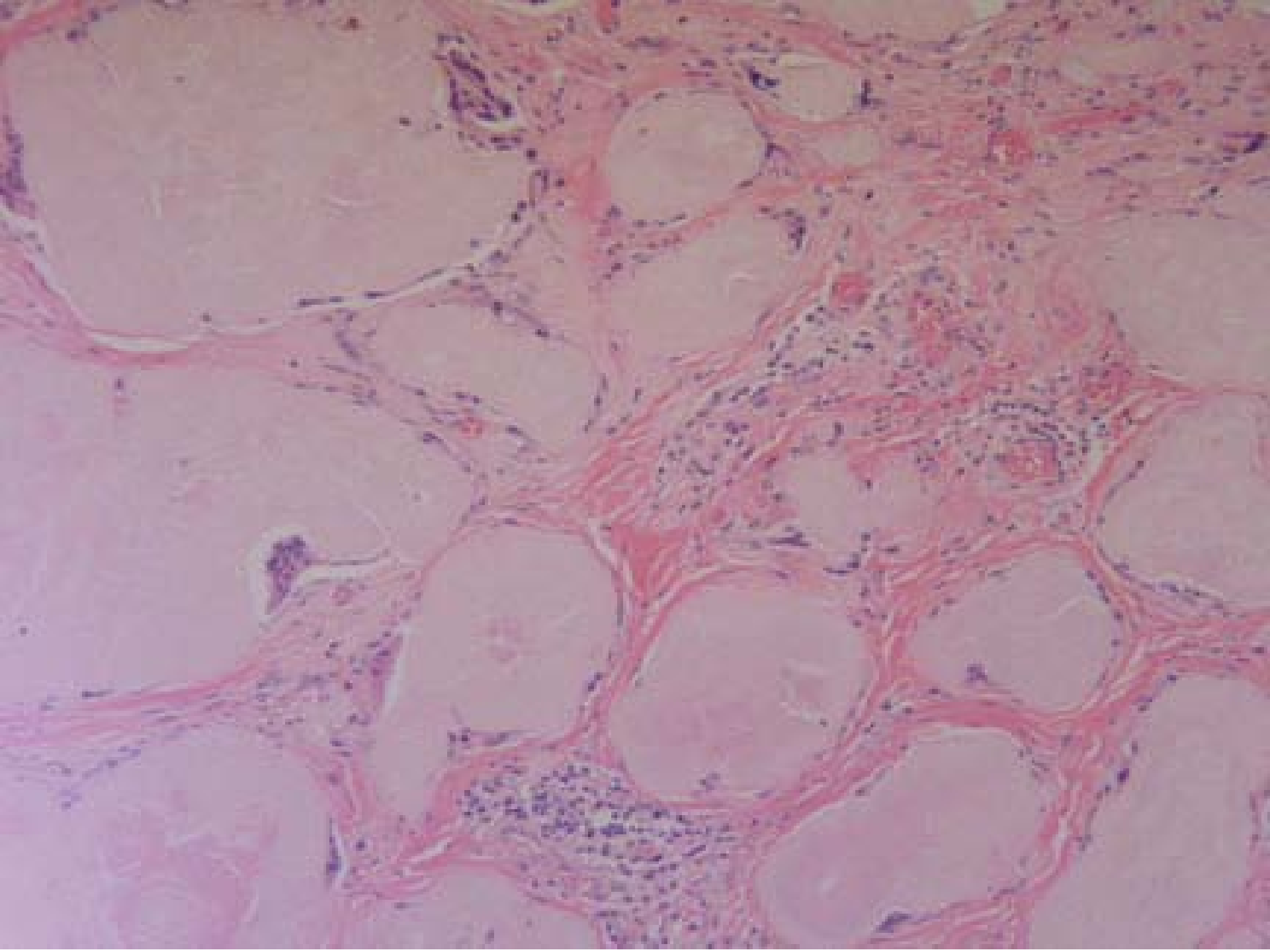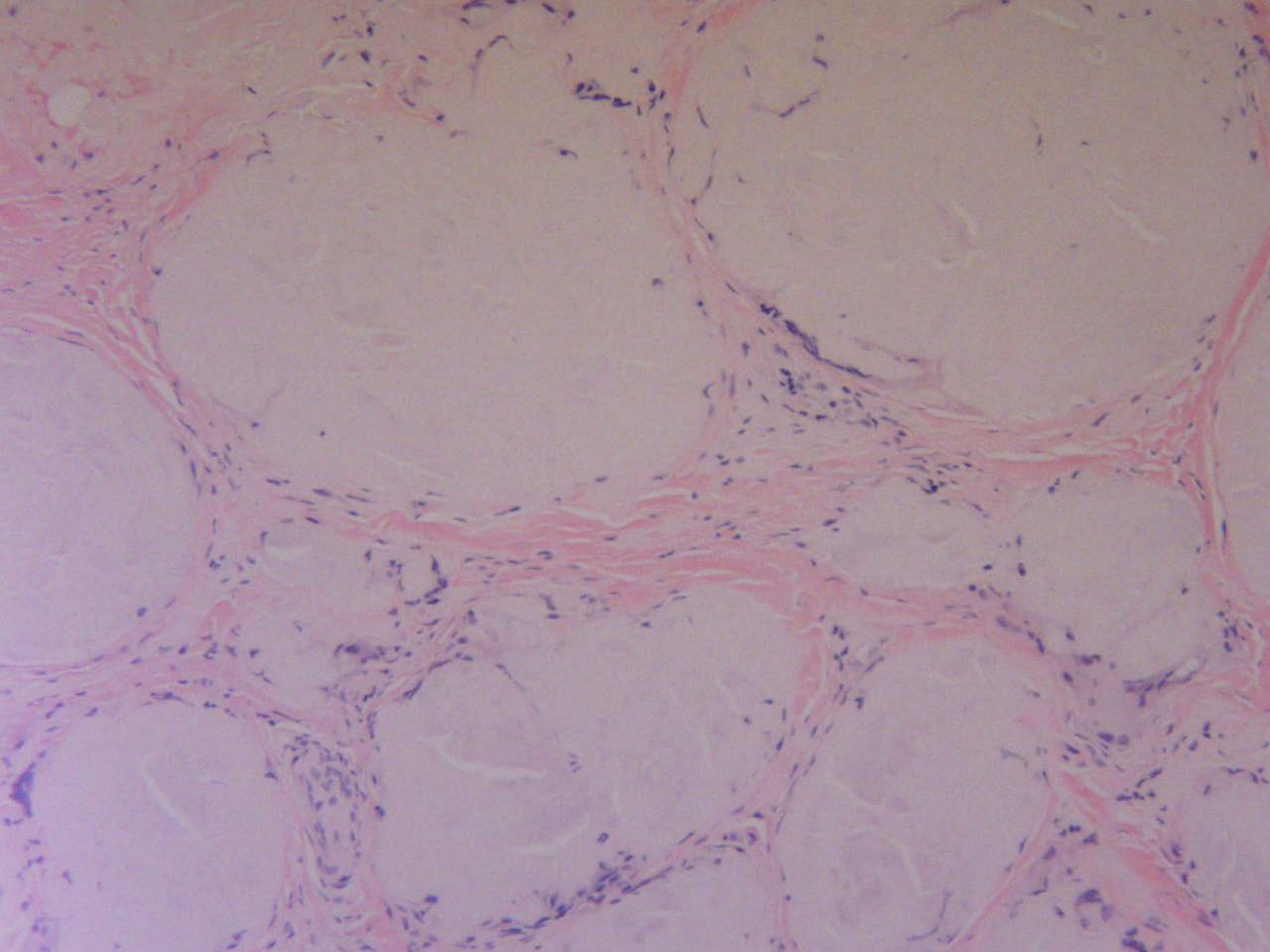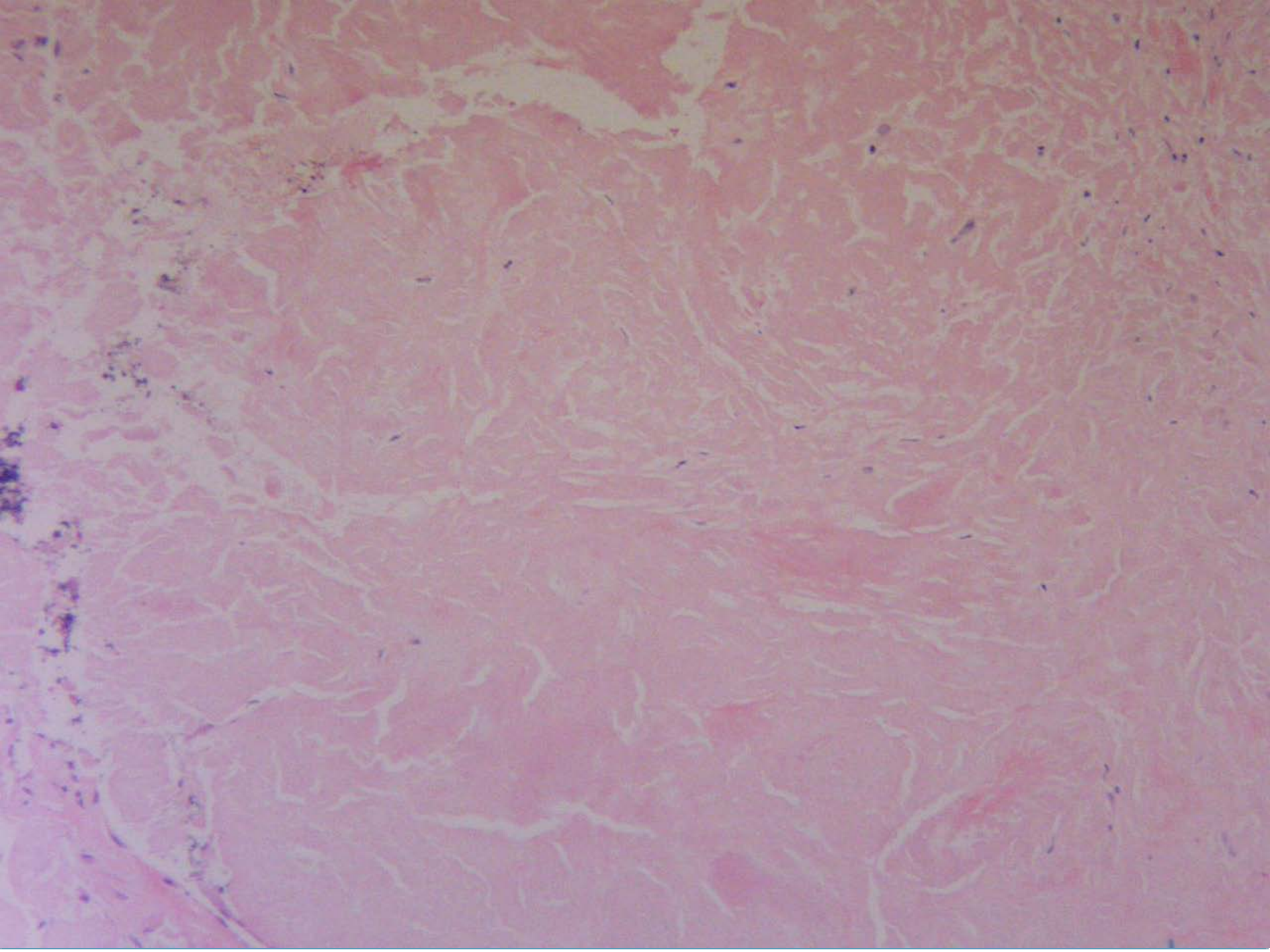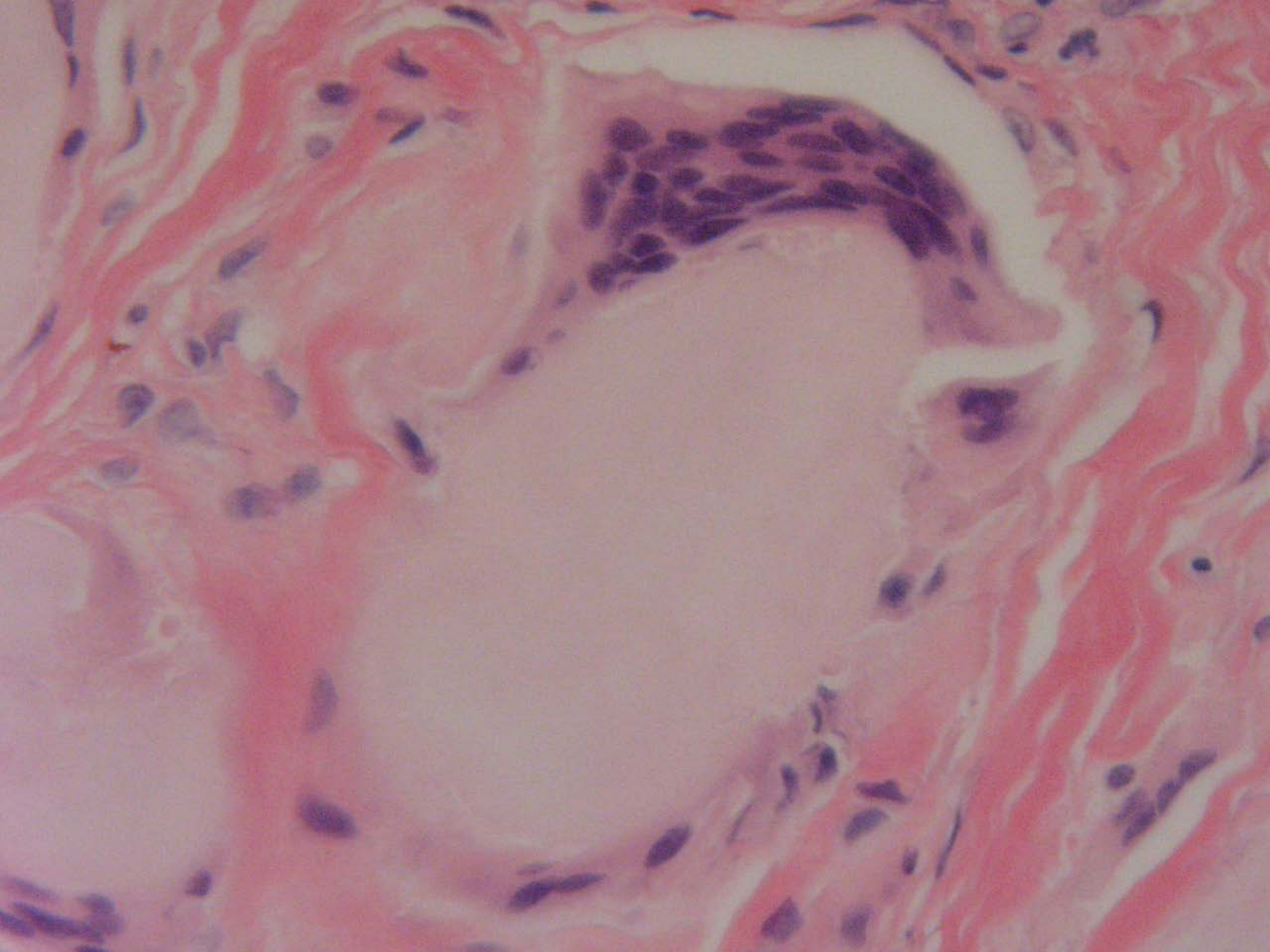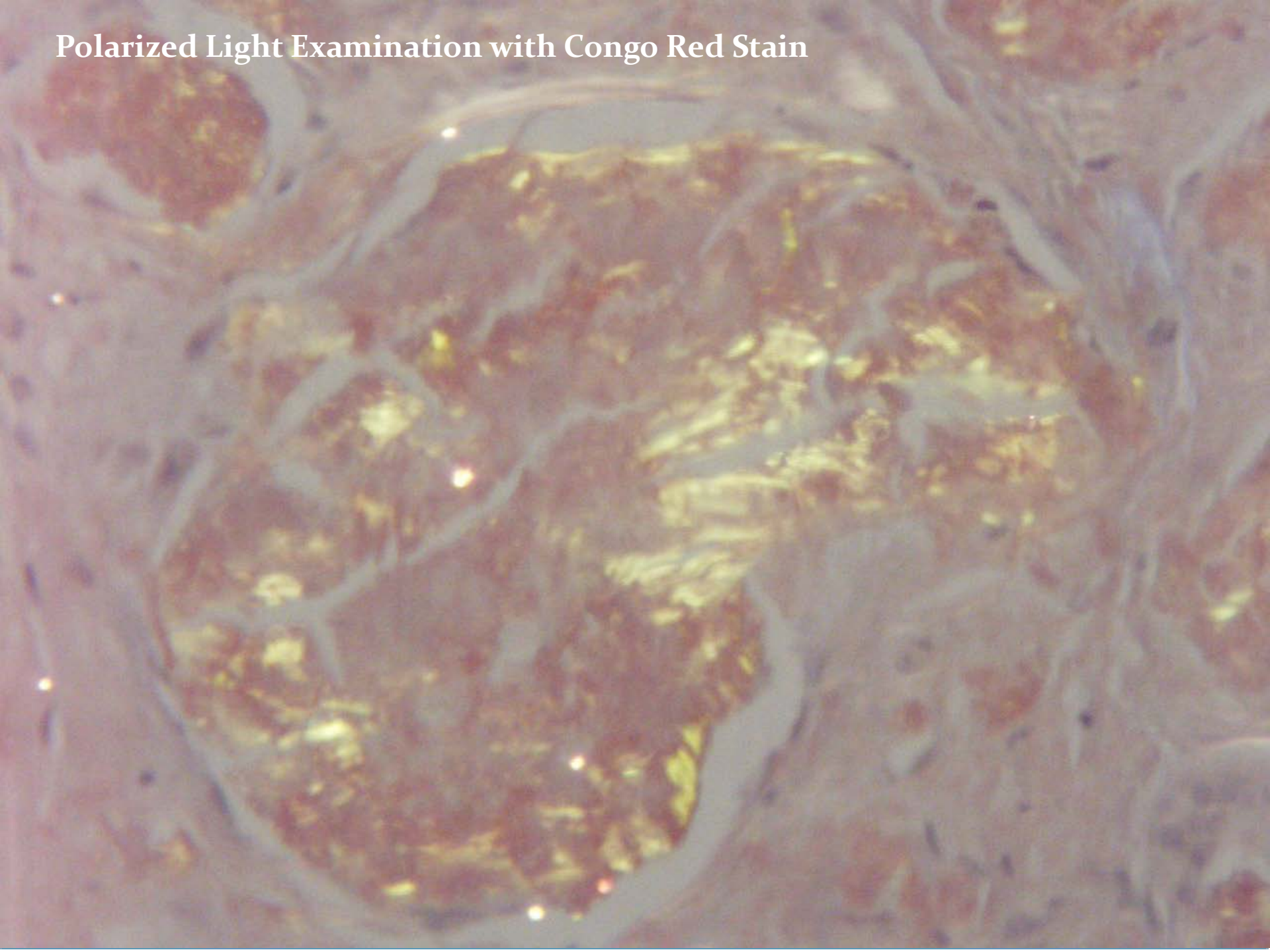
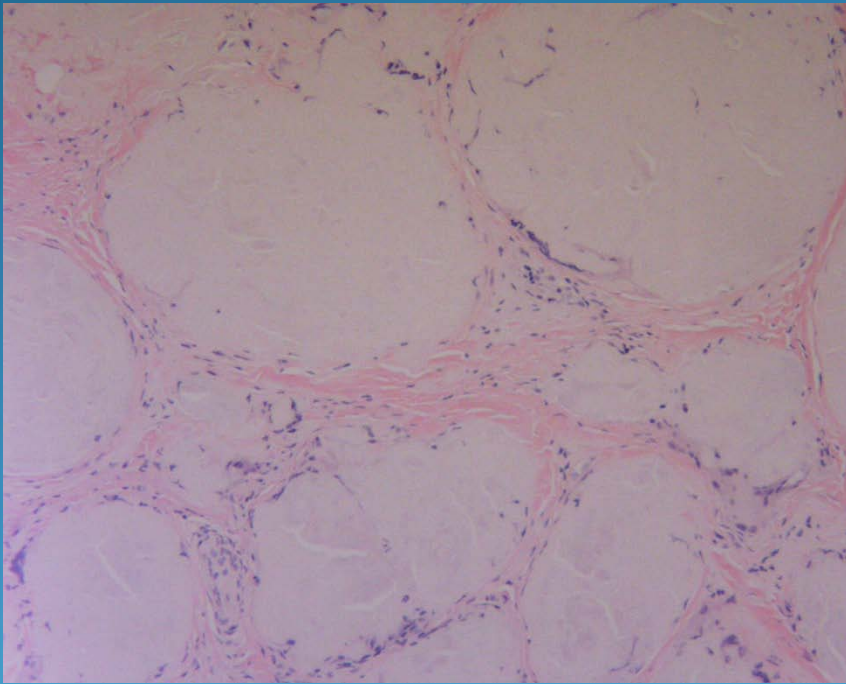


Nodular Amyloid

Polarized Light Examination with Congo Red Stain



Pearls



- Large deep pink nodules in dermis
- Cannot differentiate from colloid milium
- Lipoid proteinosis usually no globules, just diffuse pink material