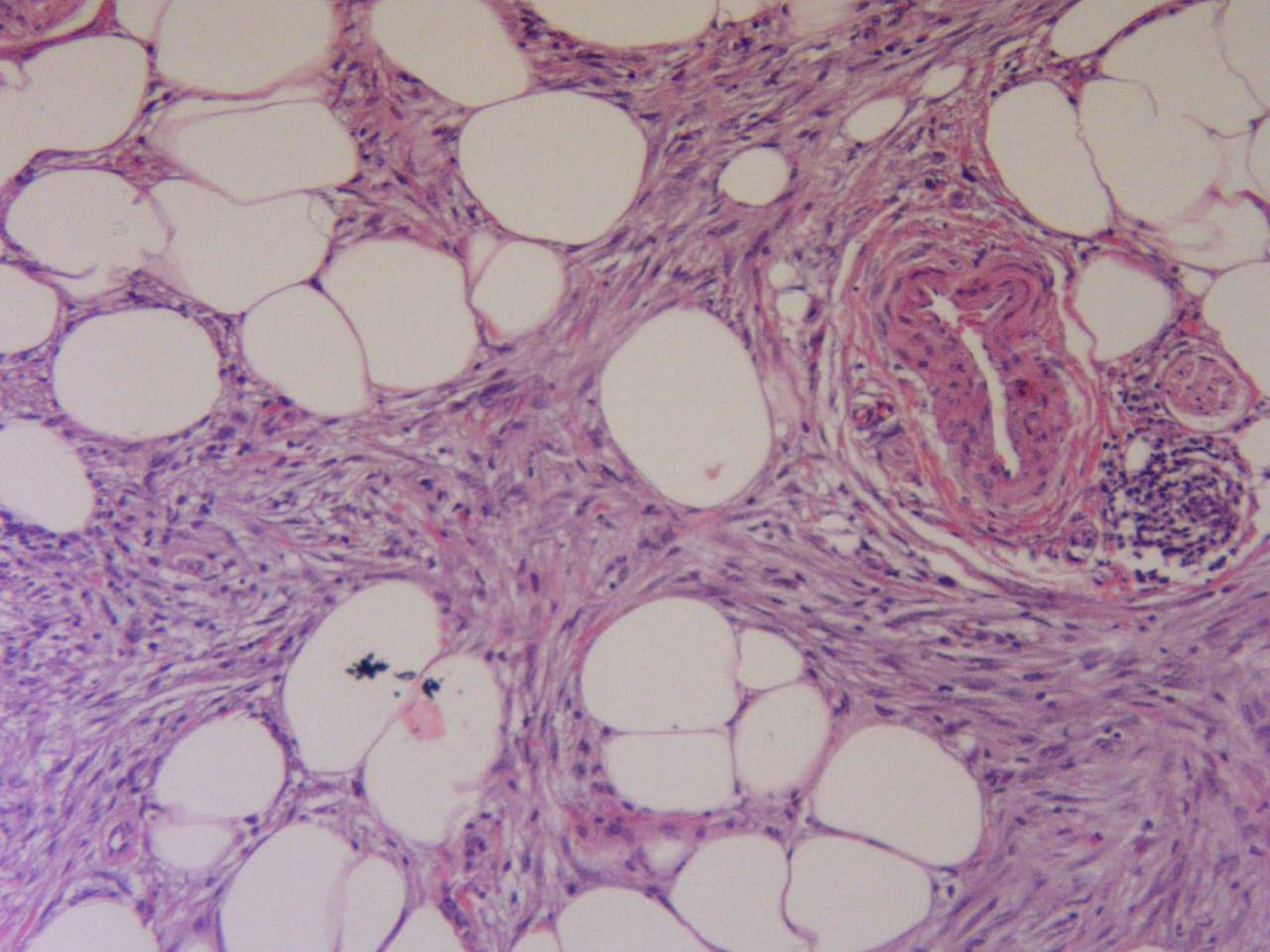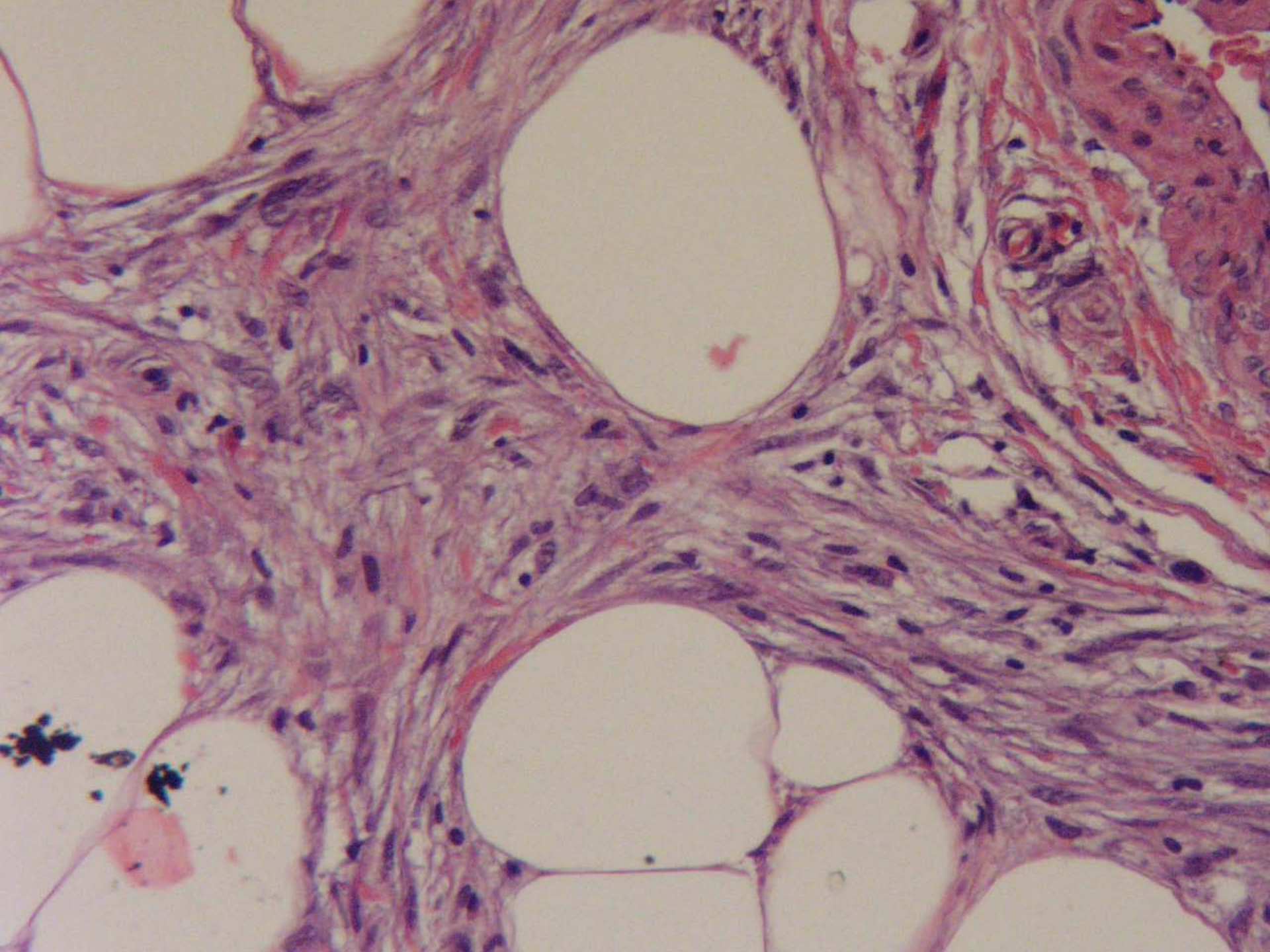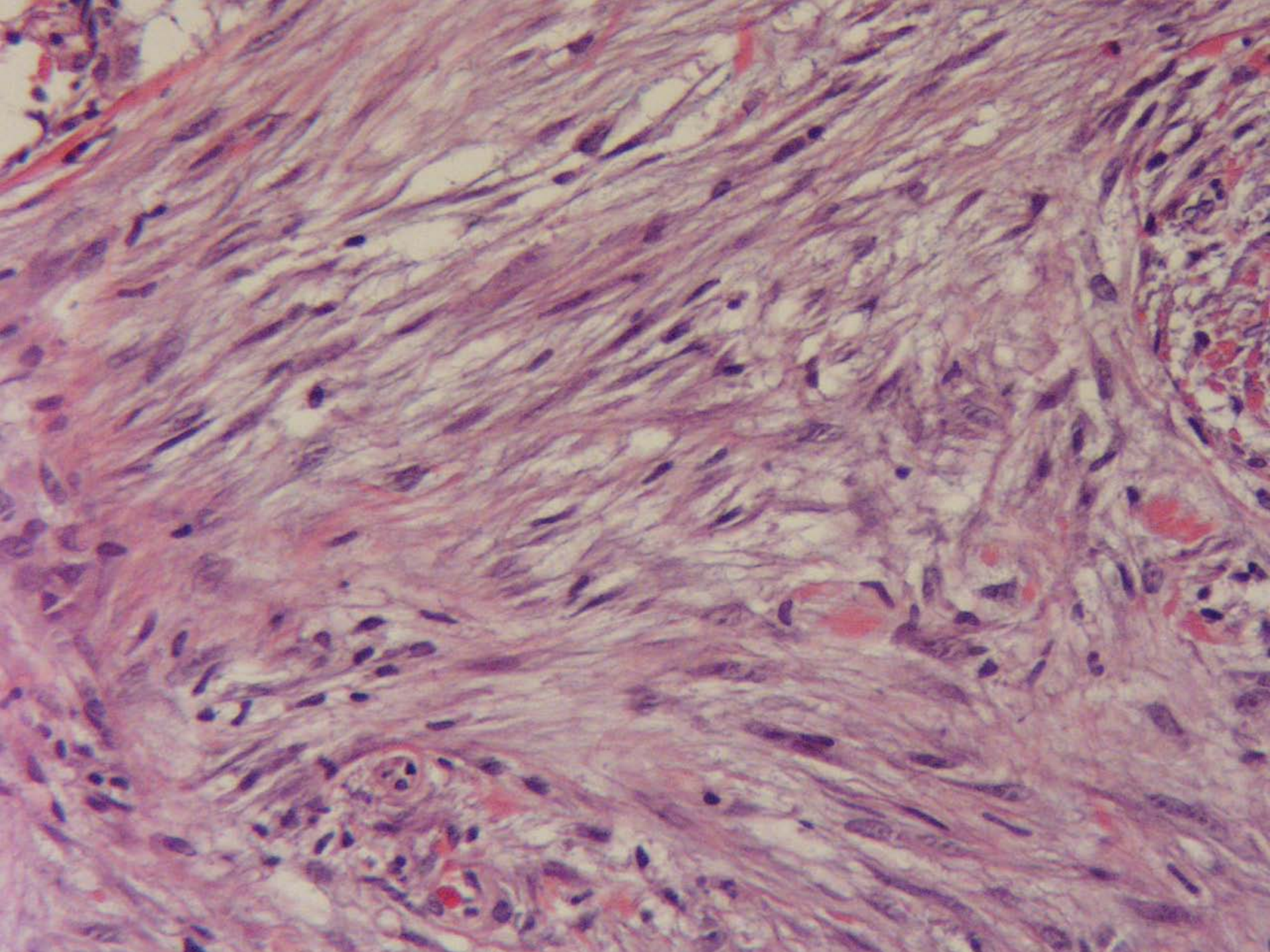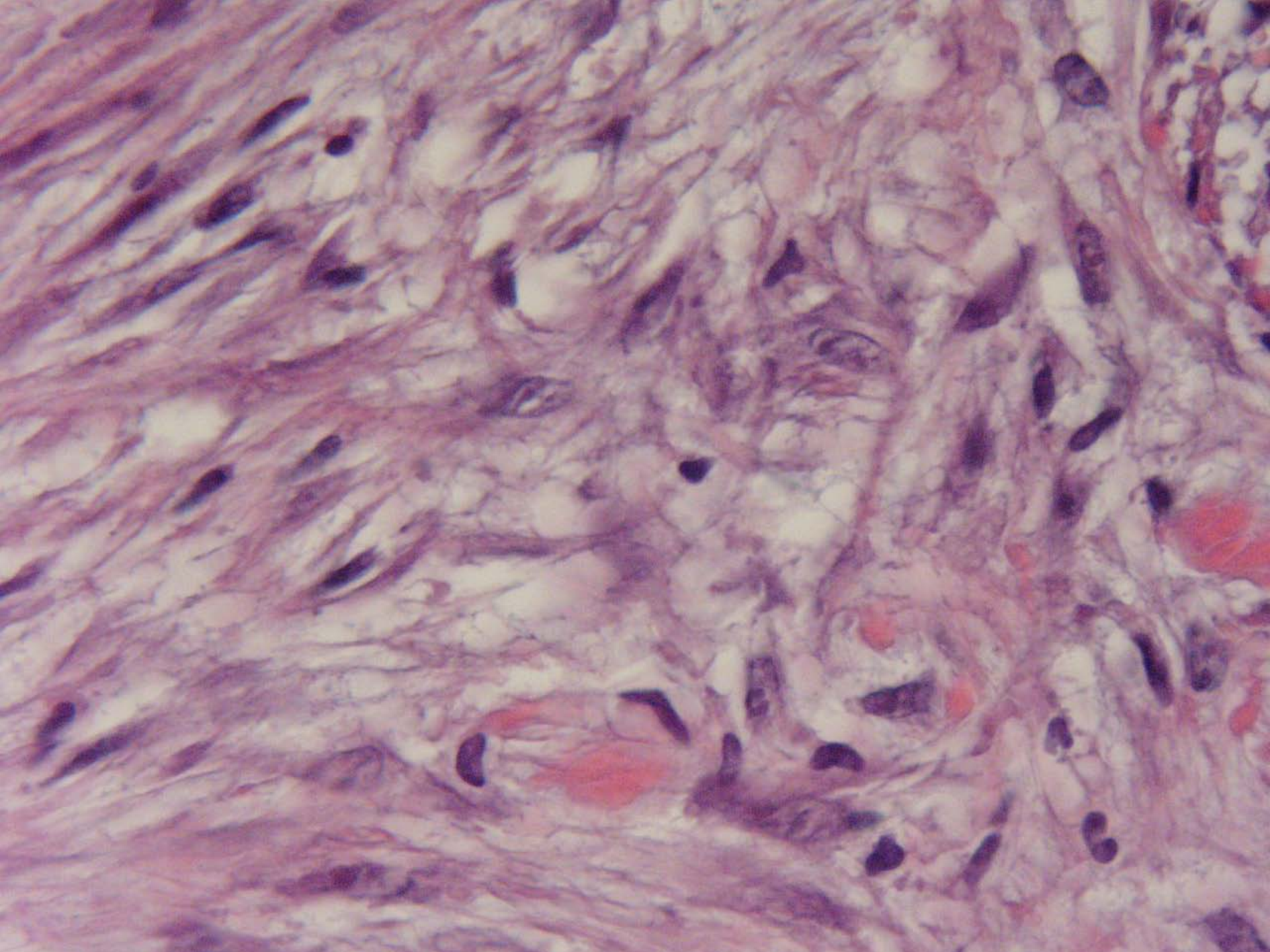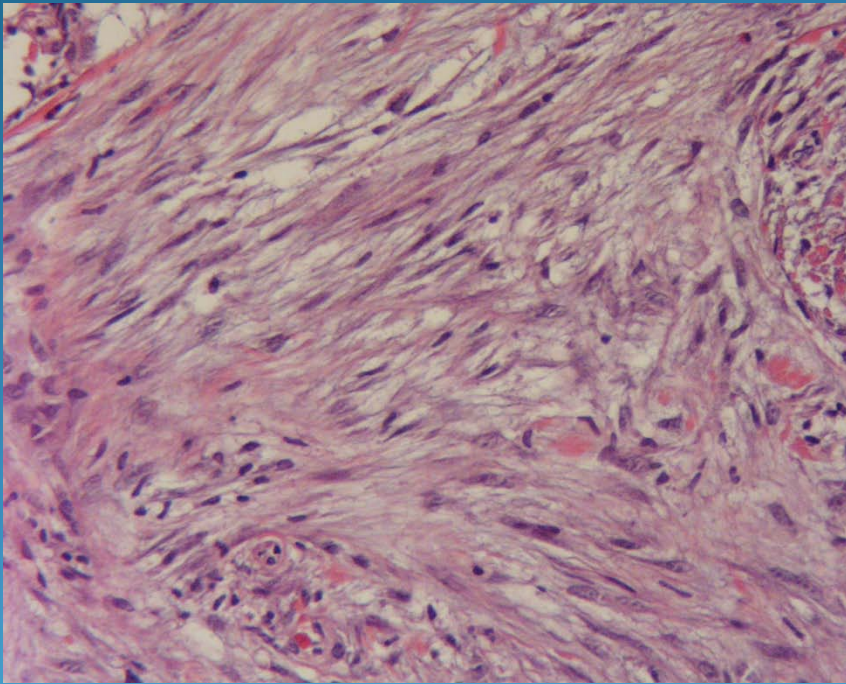


Nodular fasciitis

Pearls



- Variant of deep scar with proliferation of scar-like fibroblasts-usually no epidermis
- Myxoid feathery spindle cell tumor
- Mitoses common but no atypical mitotic figures
- No collapsed vessels like myxoid liposarcoma