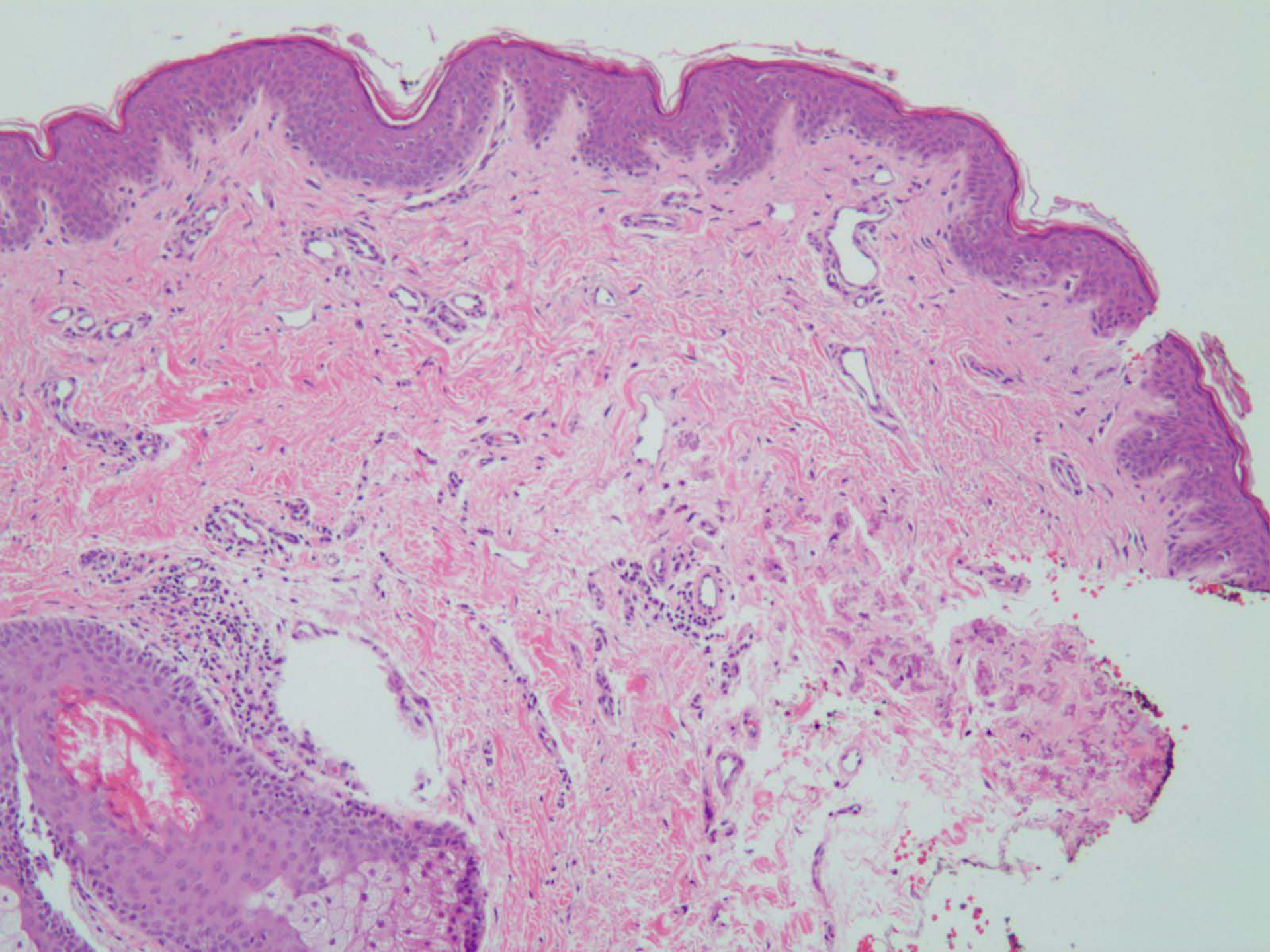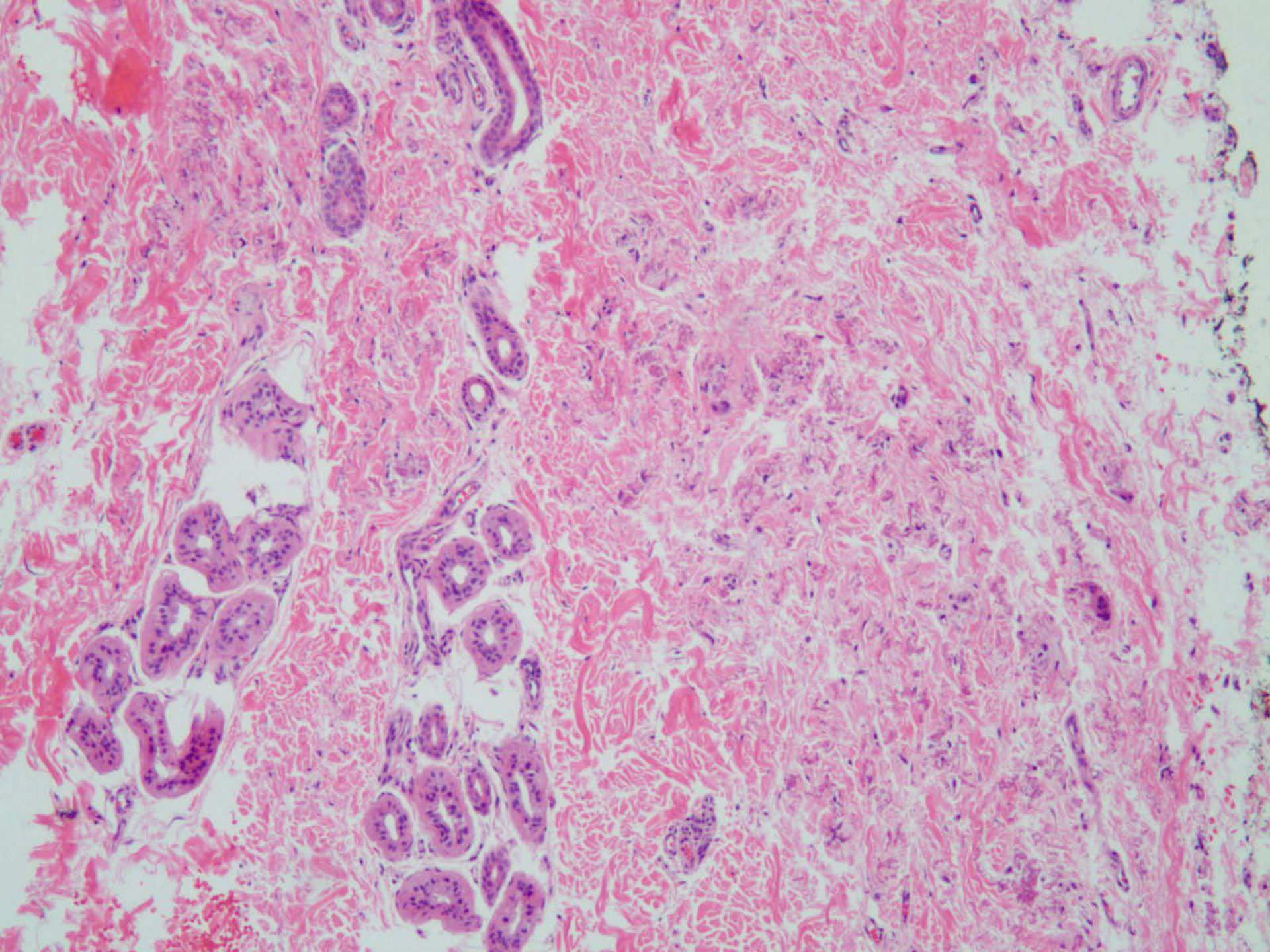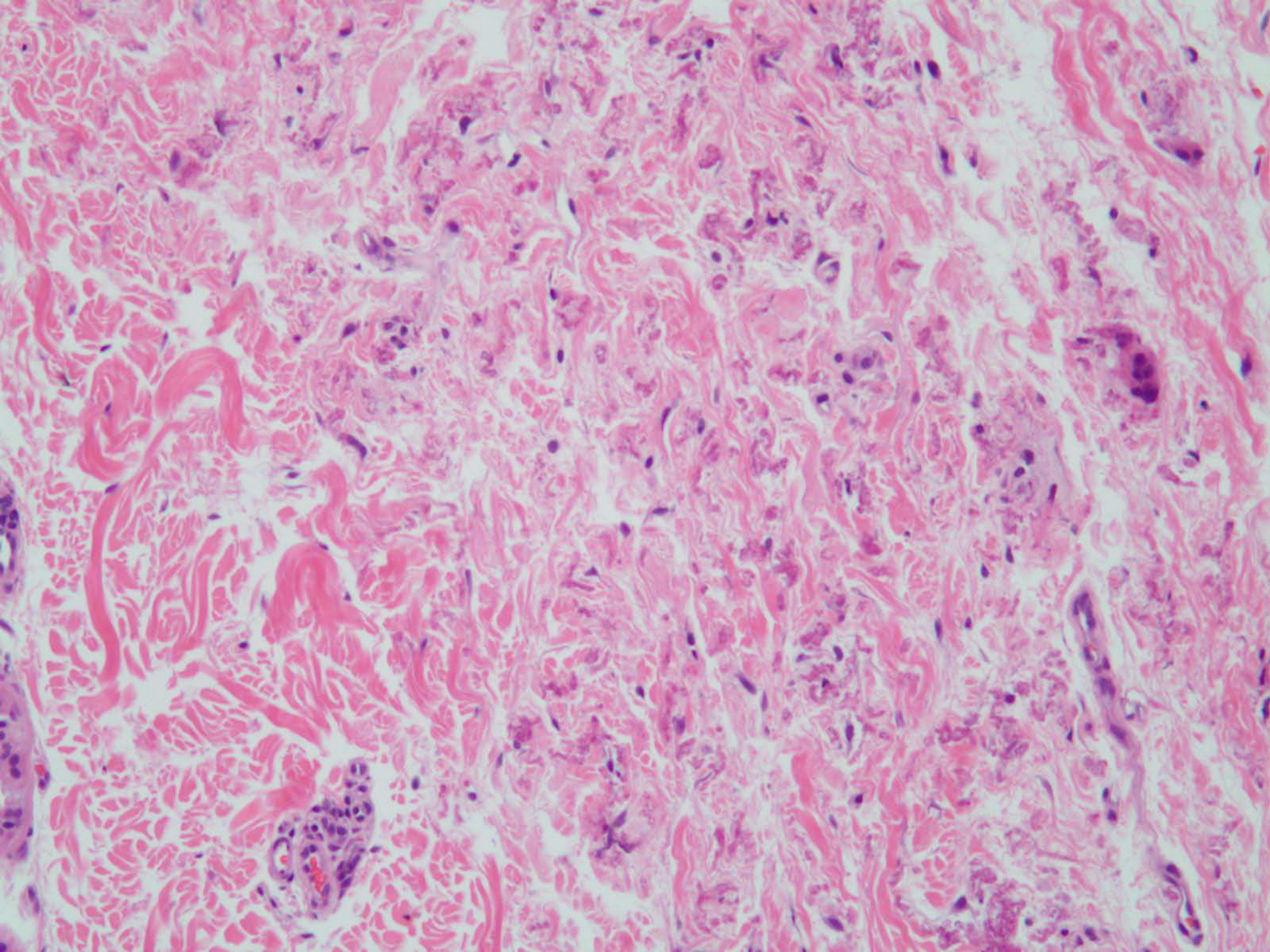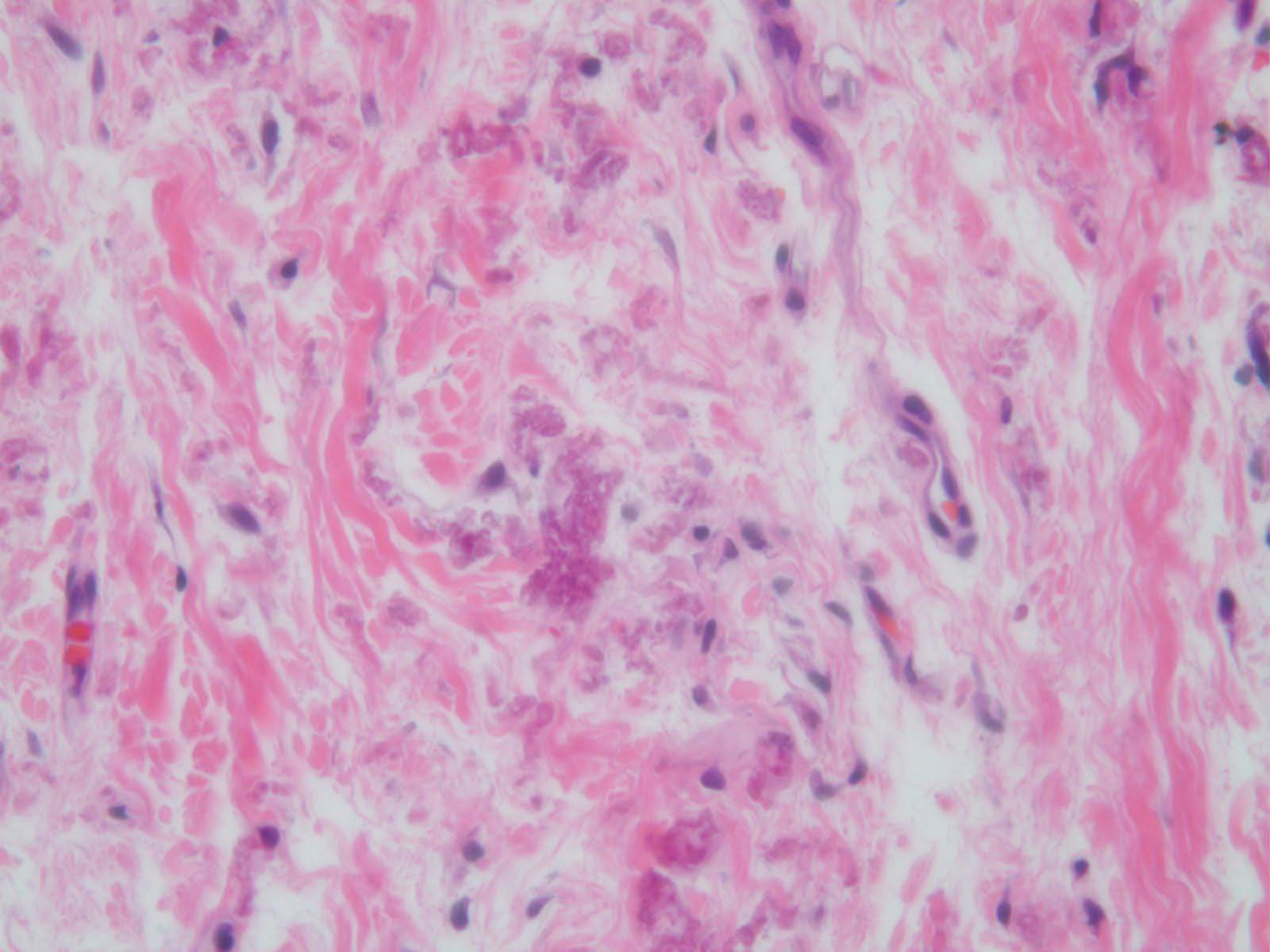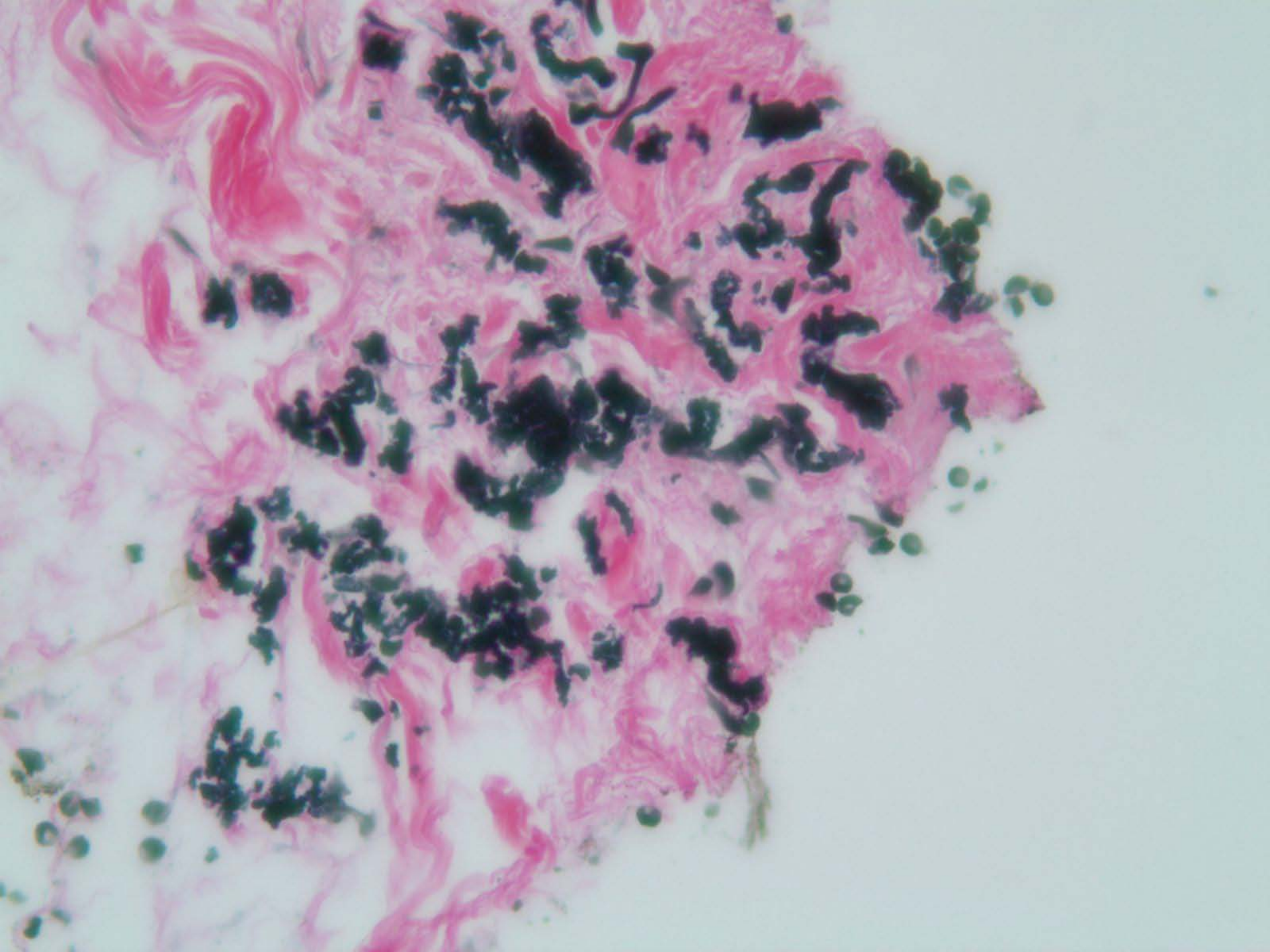
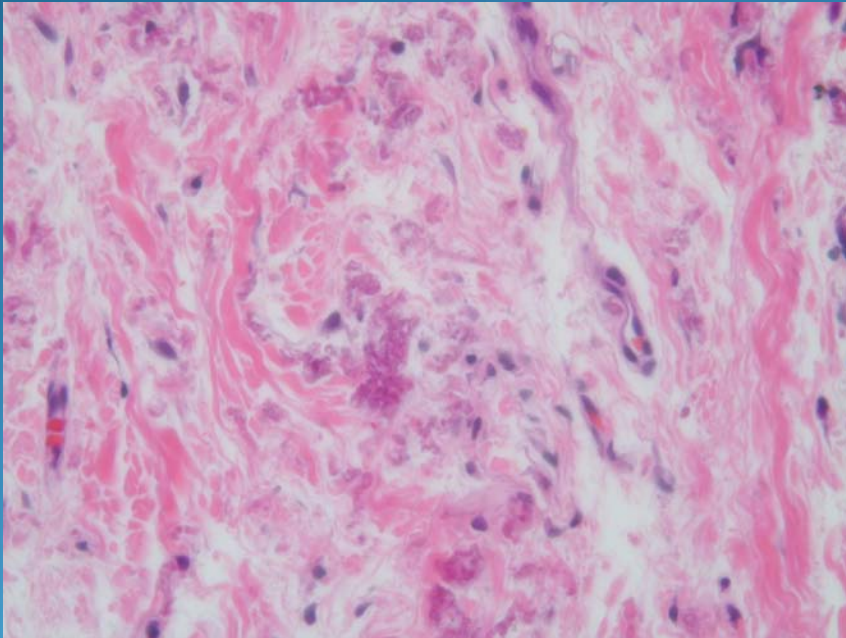


Pseudoxanthom Elasticum



Pearls



- Pink “squiggly disease” with material in dermis that may calcify
- If see calcified nodule, look for squiggly lines before diagnosing calcinosis cutis