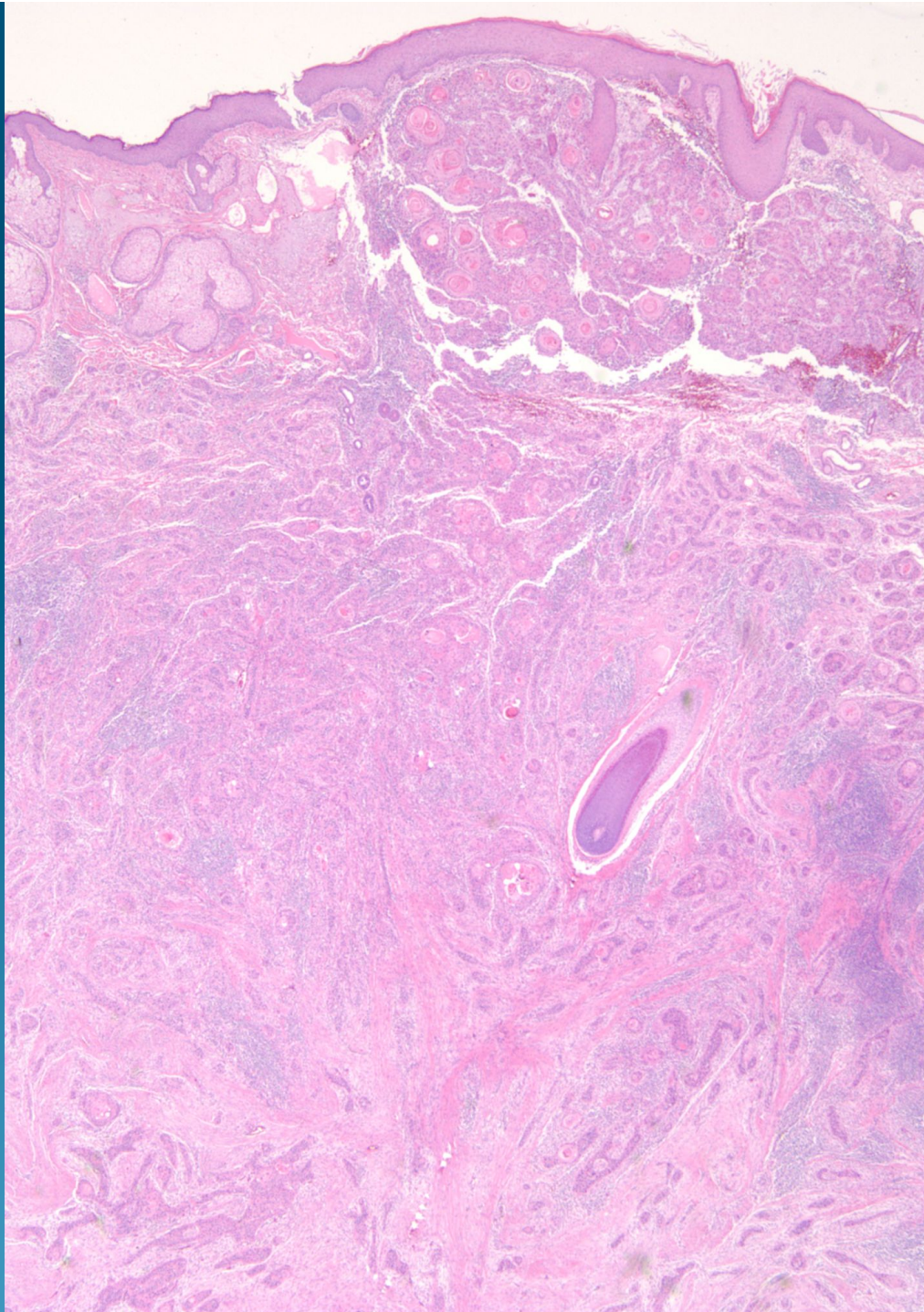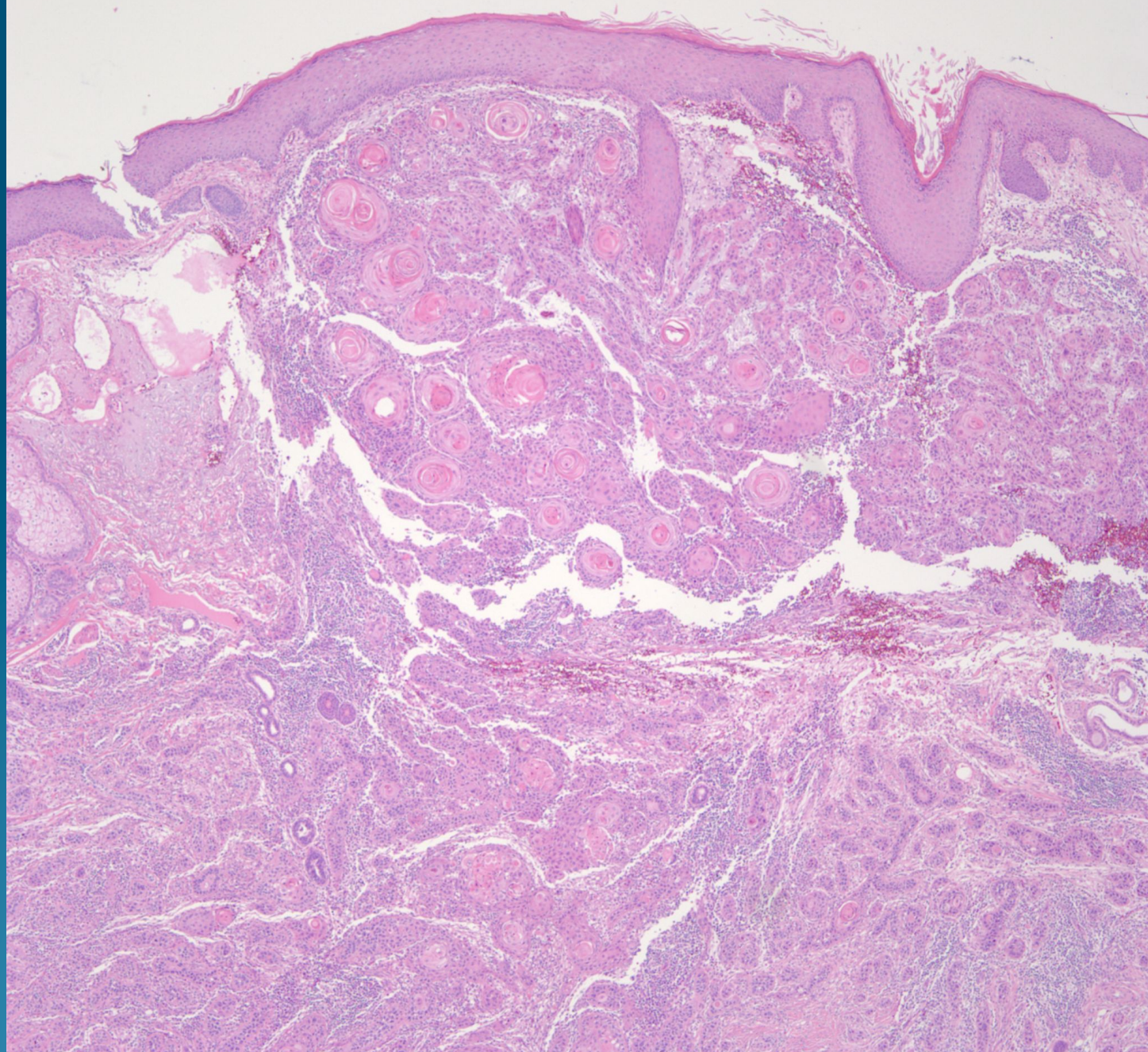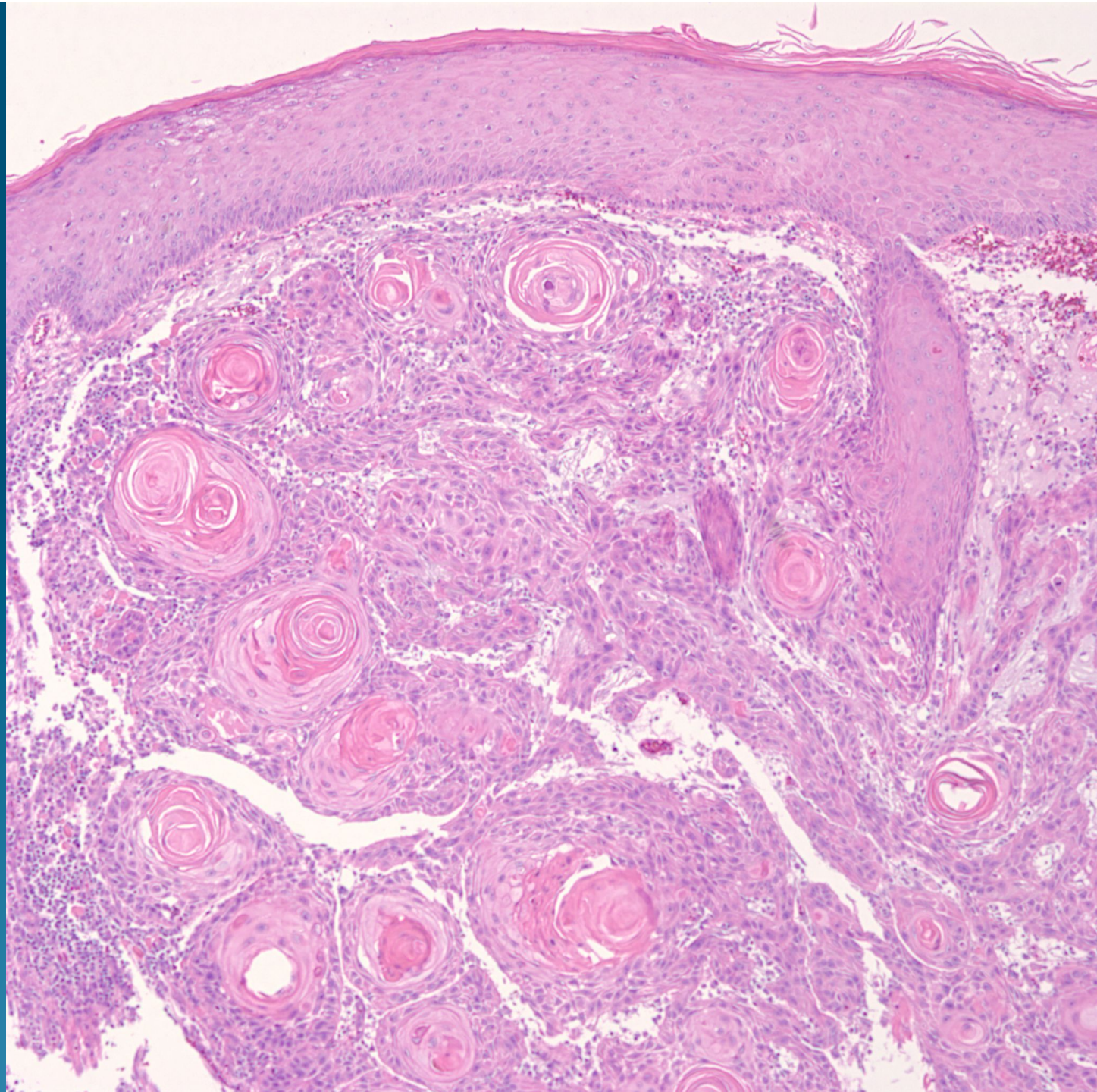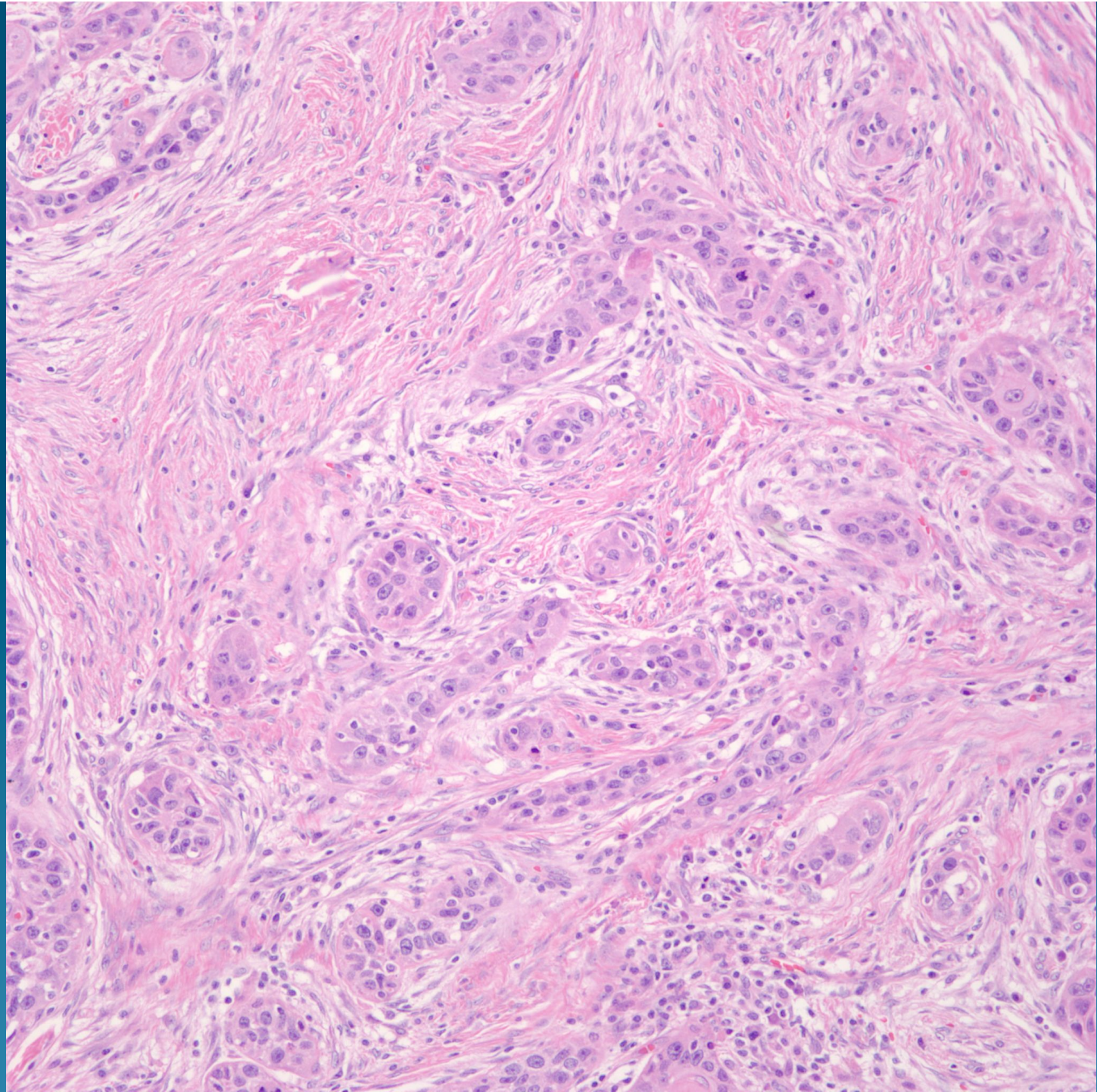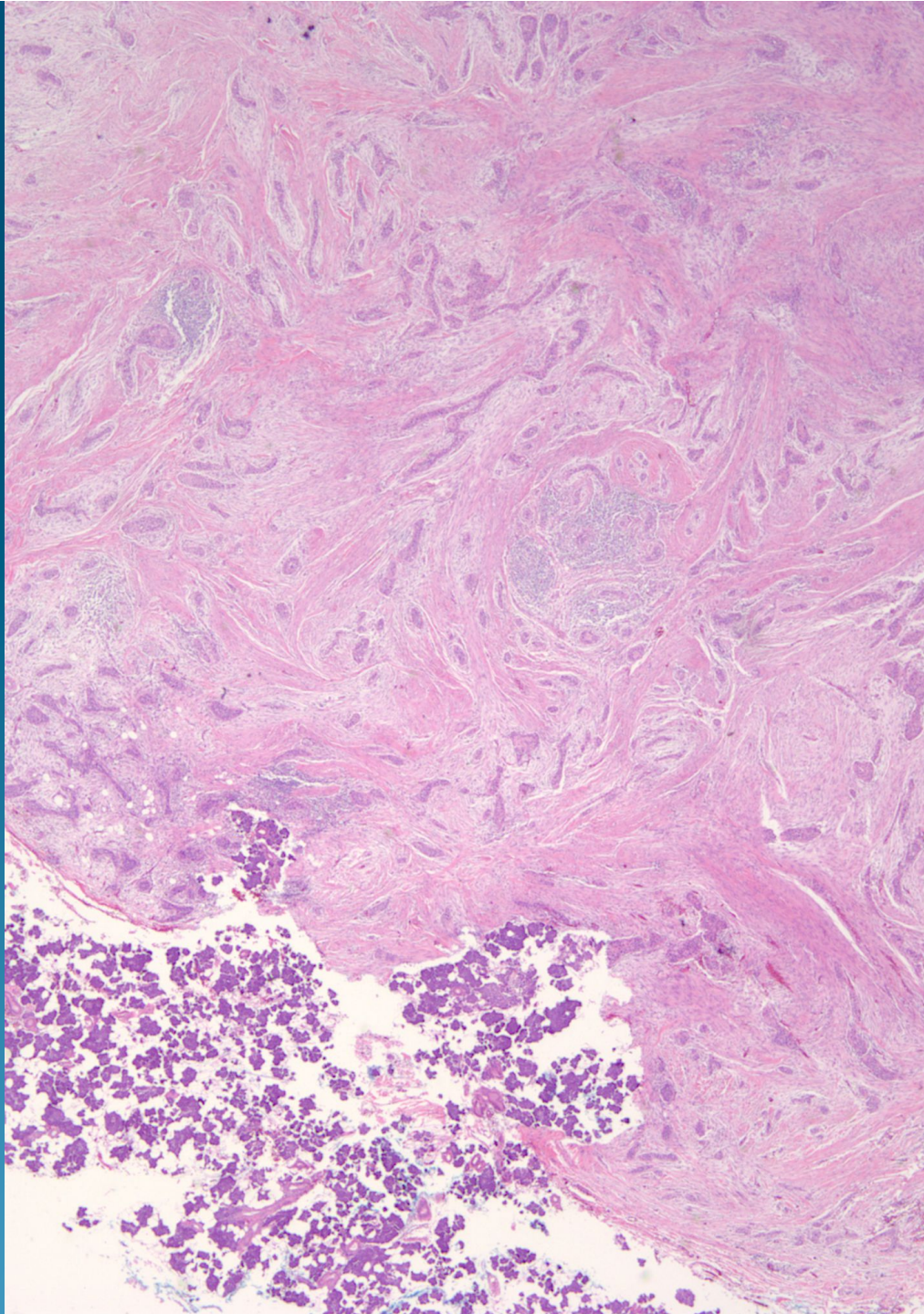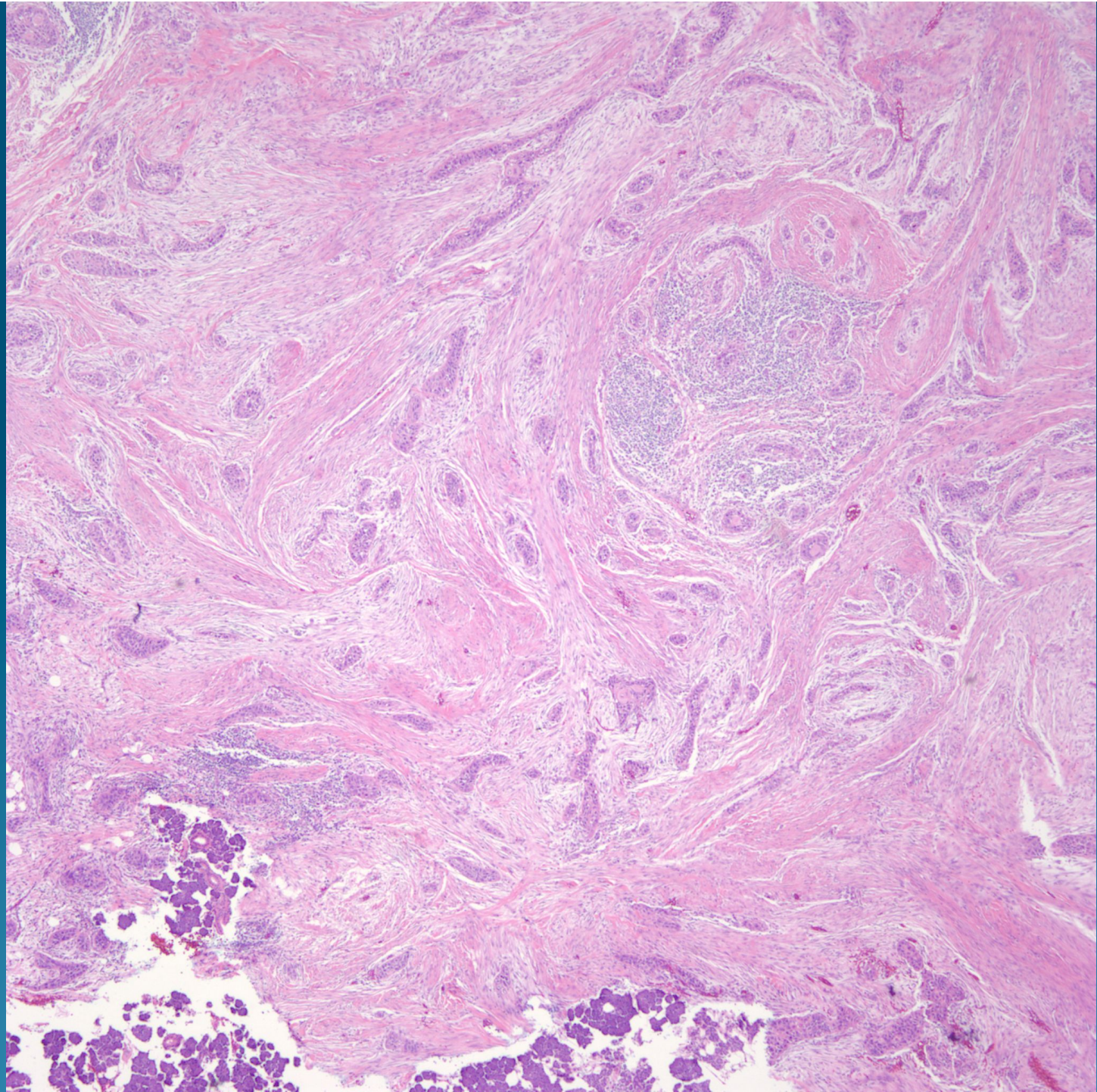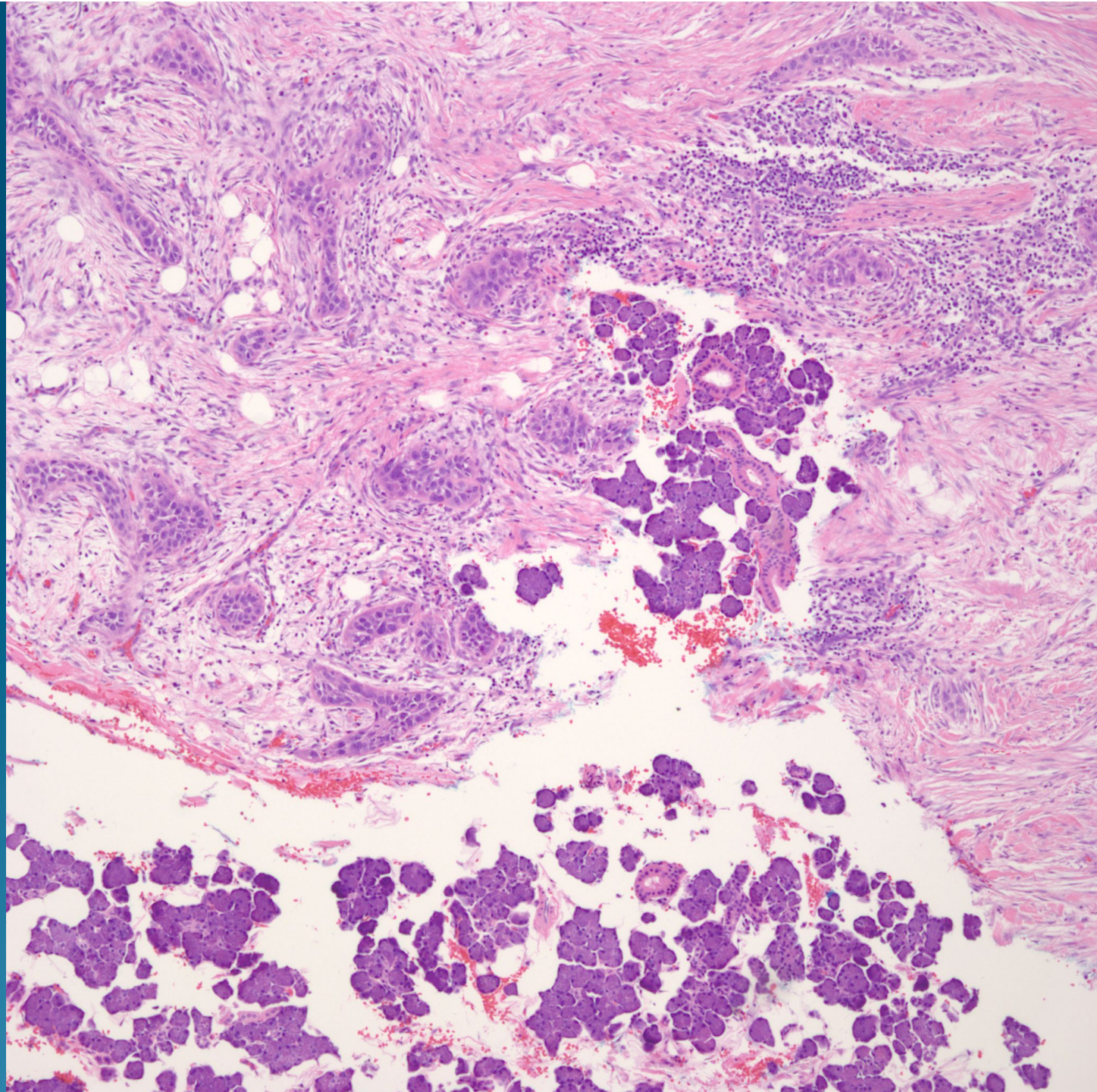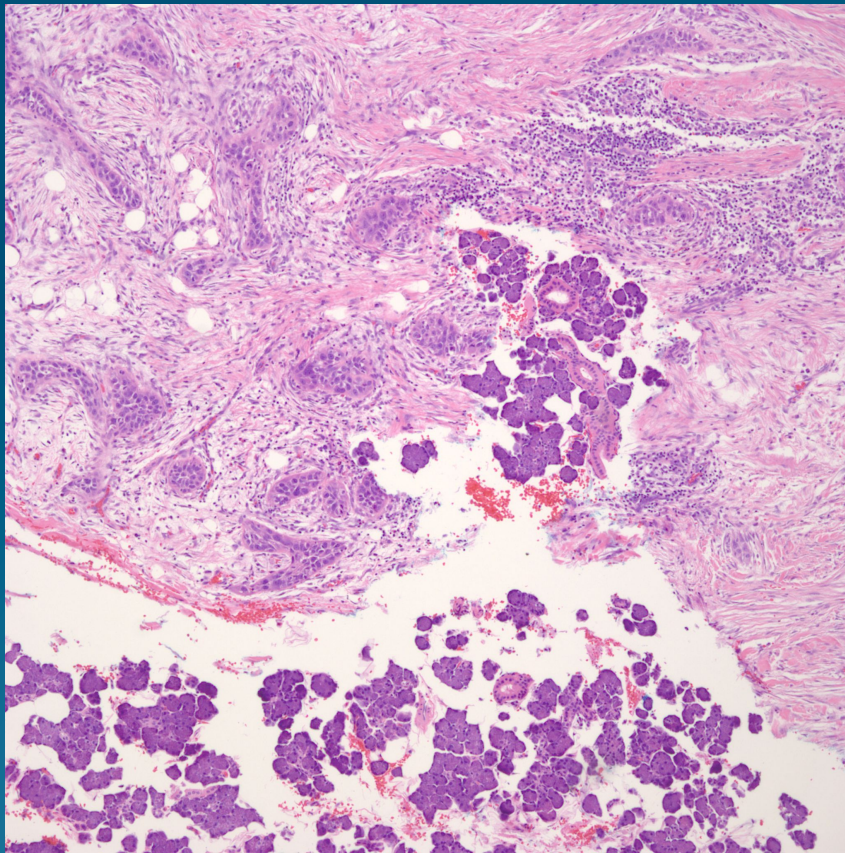


What is the best diagnosis?

- A. Collision tumor-Squamous cell carcinoma and basal cell carcinoma
- B. Basosquamous Cell Carcinoma
- C. Microcystic Adnexal Carcinoma
- D. Merkel Cell Carcinoma
- E. Squamous cell Carcinoma invasive into Parotid Gland

Squamous Cell Carcinoma Invasive into Parotid Gland

Pearls



- Conventional squamous cell carcinoma of varying differentiation
- Parotid gland has predominance of serous glands-other salivary gland may have admixture of mucinous glands, depending upon location
- Beware of primary salivary gland carcinomas with squamous differentiation invading into skin-far worse prognosis

