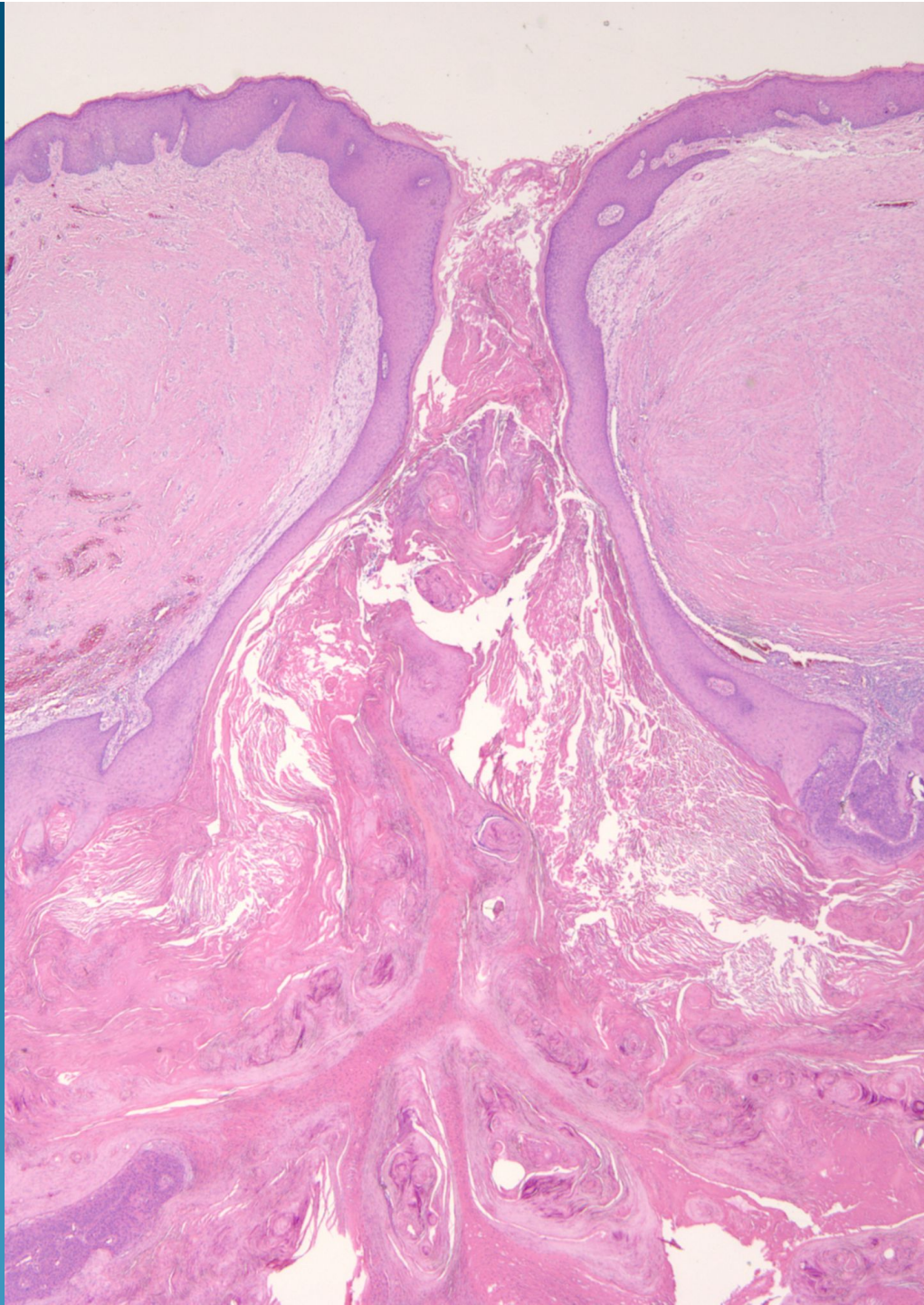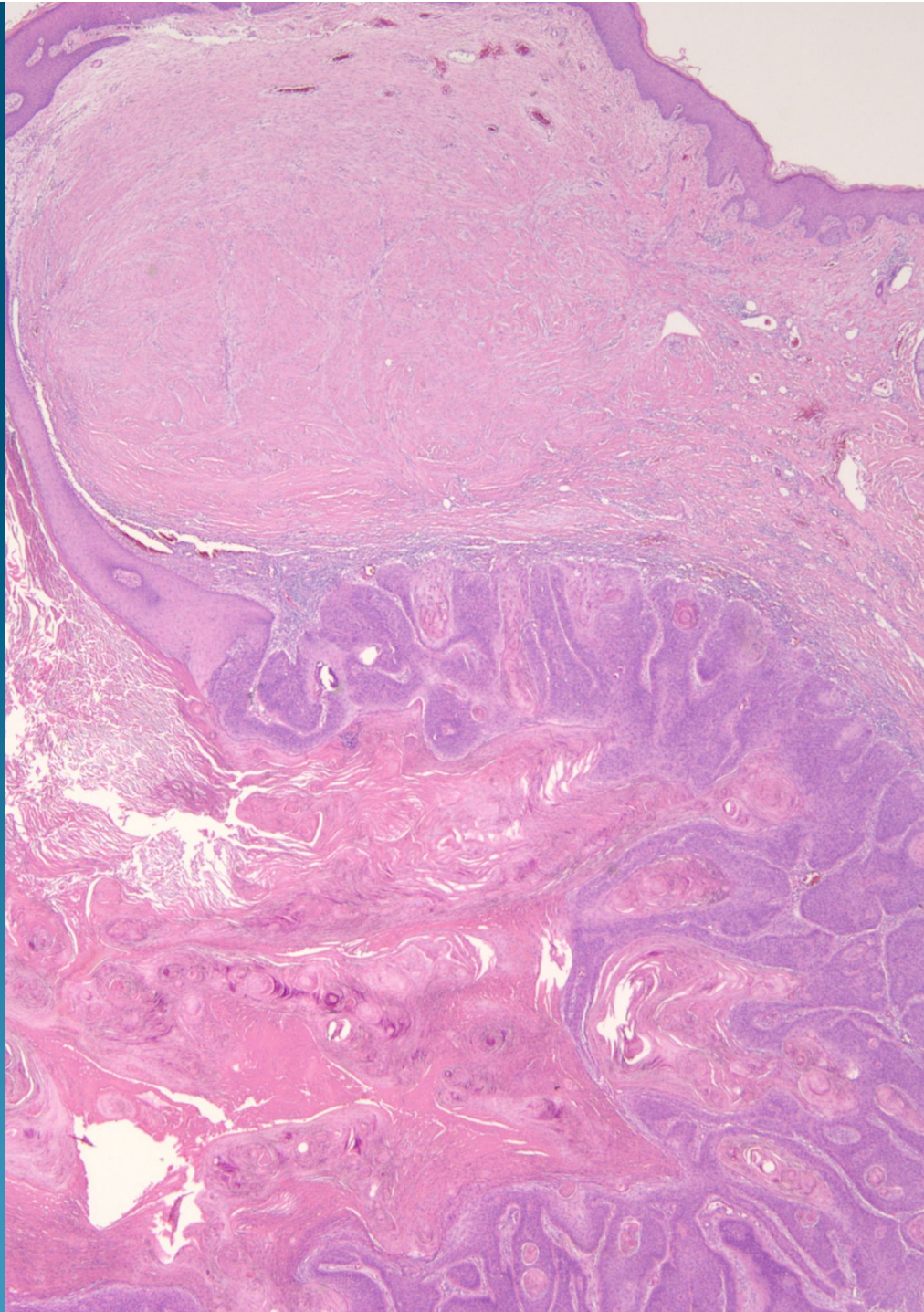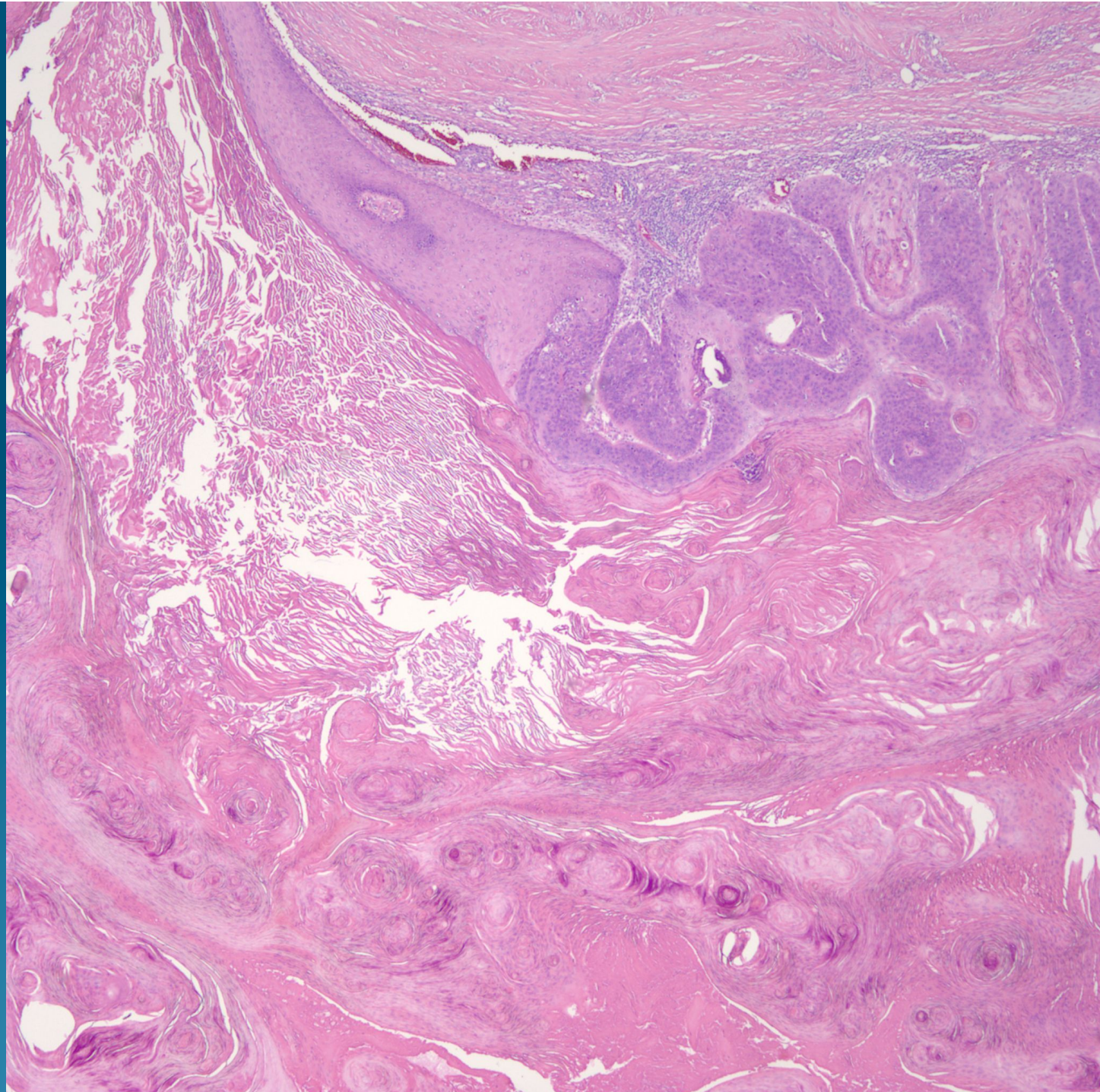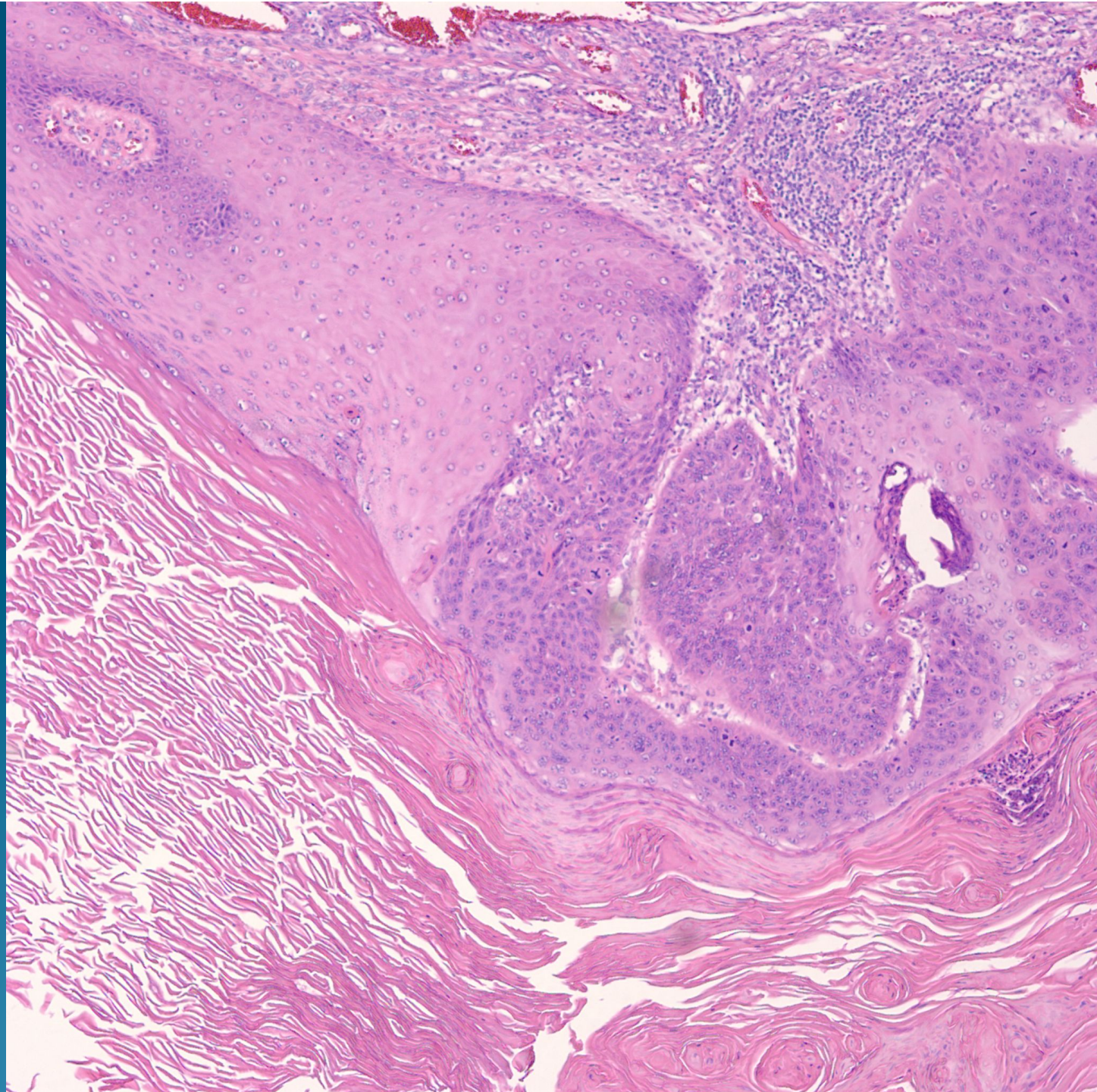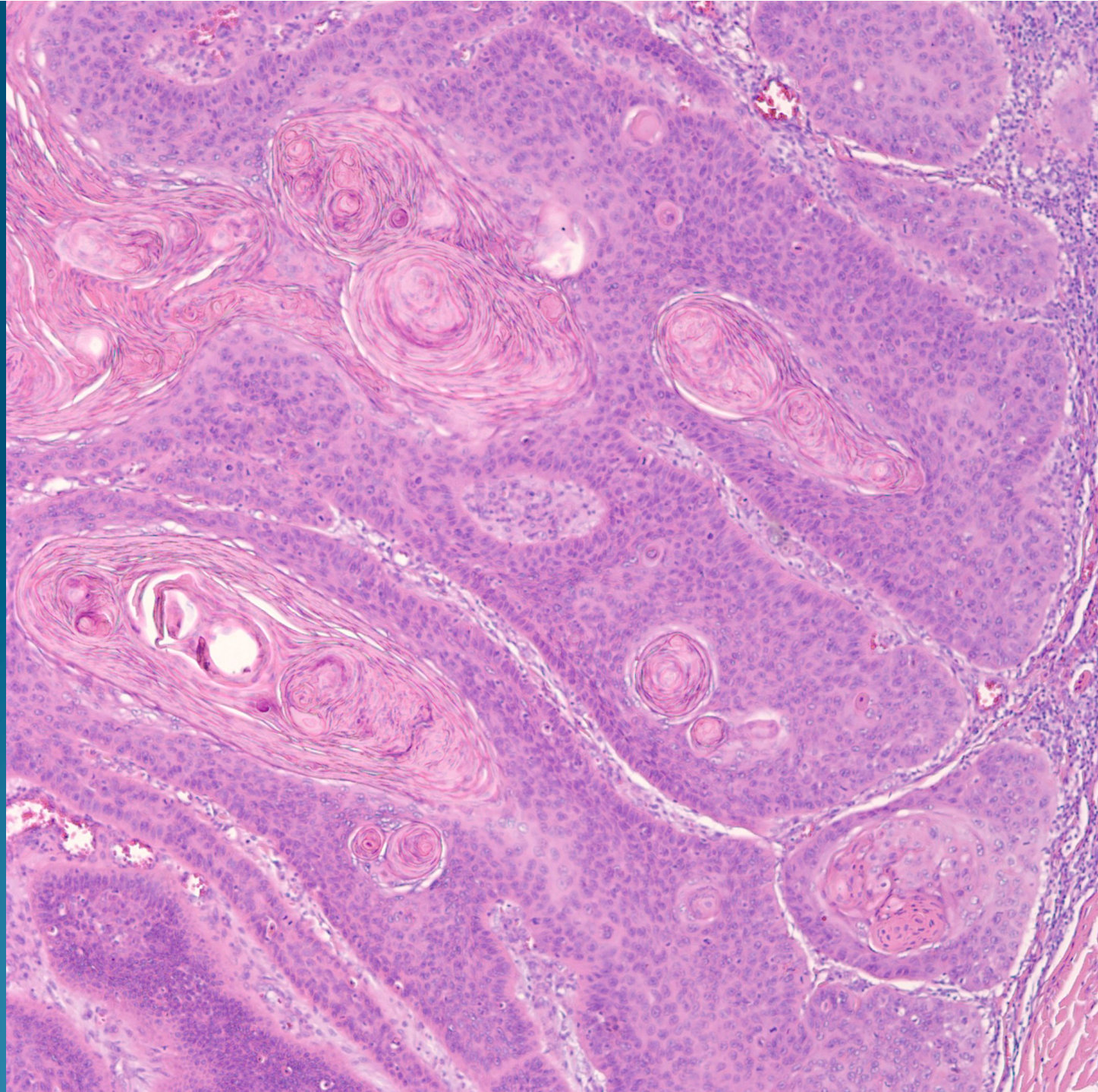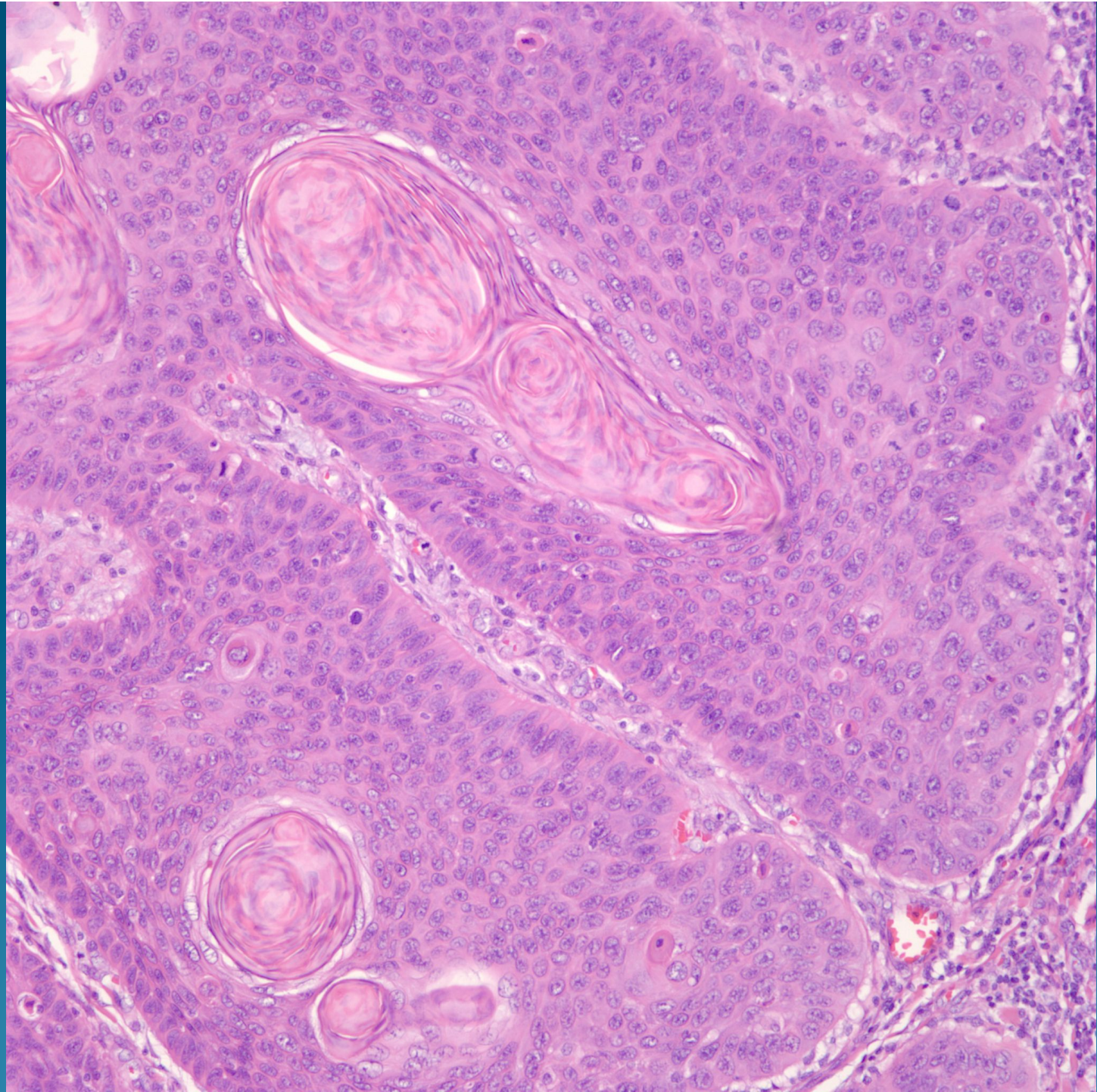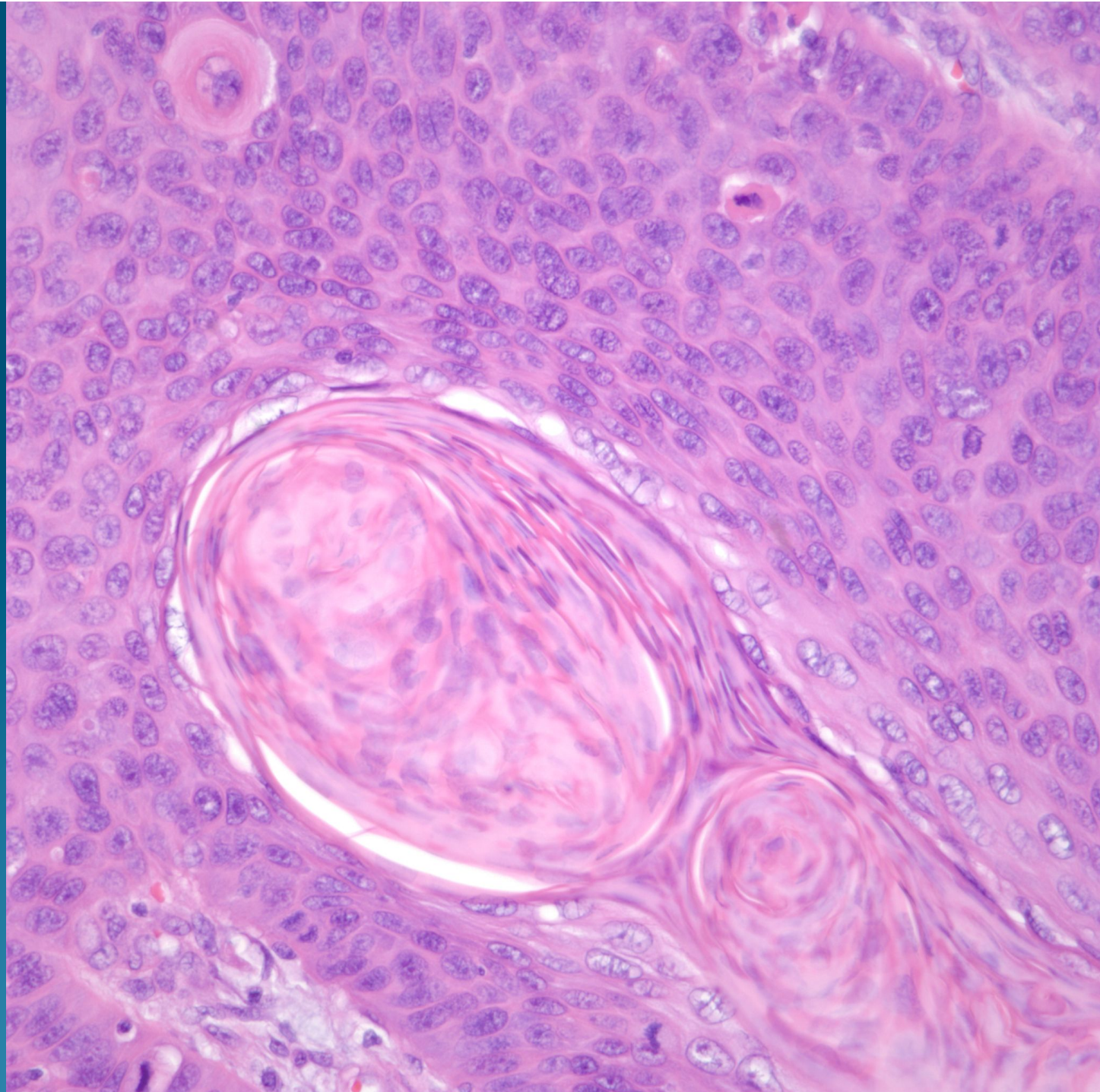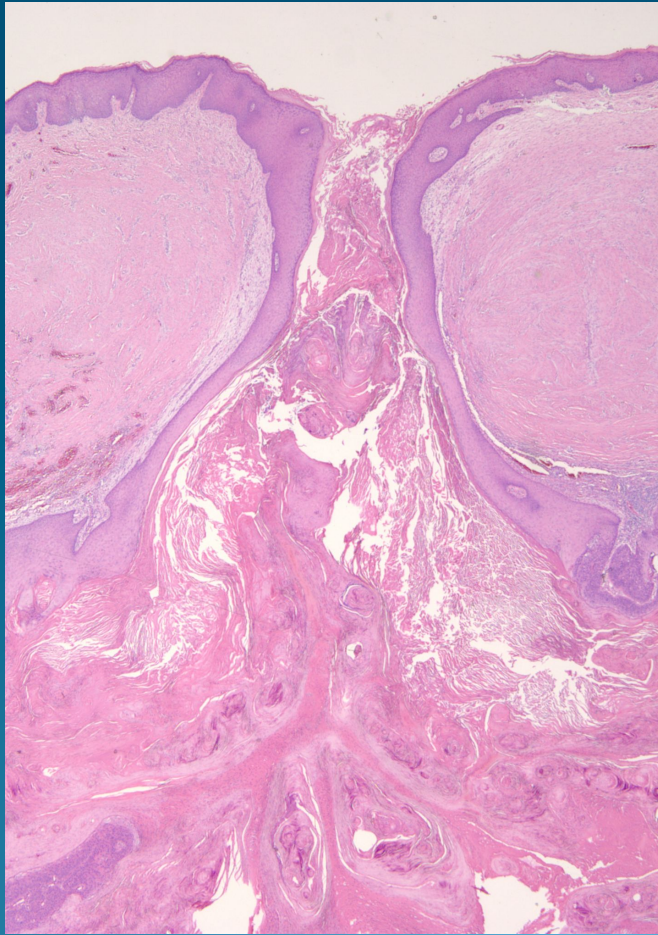


What is the best diagnosis?

- A. Folliculocentric basal cell carcinoma
- B. Nodular hidradenocarcinoma
- C. Invasive squamous cell carcinoma
- D. Pilomatrical carcinoma
- E. Sebaceous carcinoma

Invasive Squamous Cell Carcinoma arising with an epidermal cyst

Pearls



- Rare presentation of cutaneous squamous cell carcinoma
- Superficial shave biopsy may miss deeper carcinoma
- Conventional histopathology of SCCA