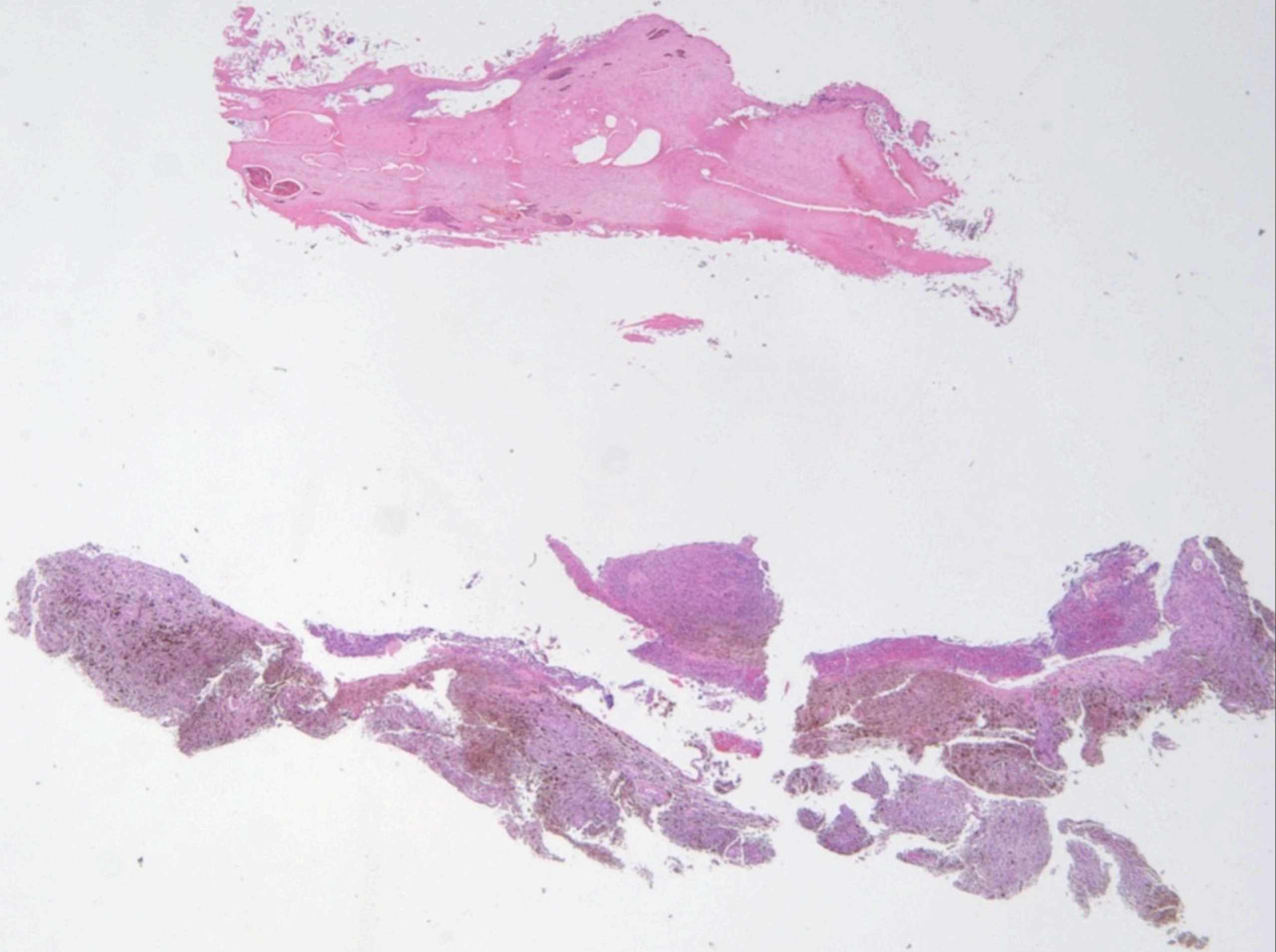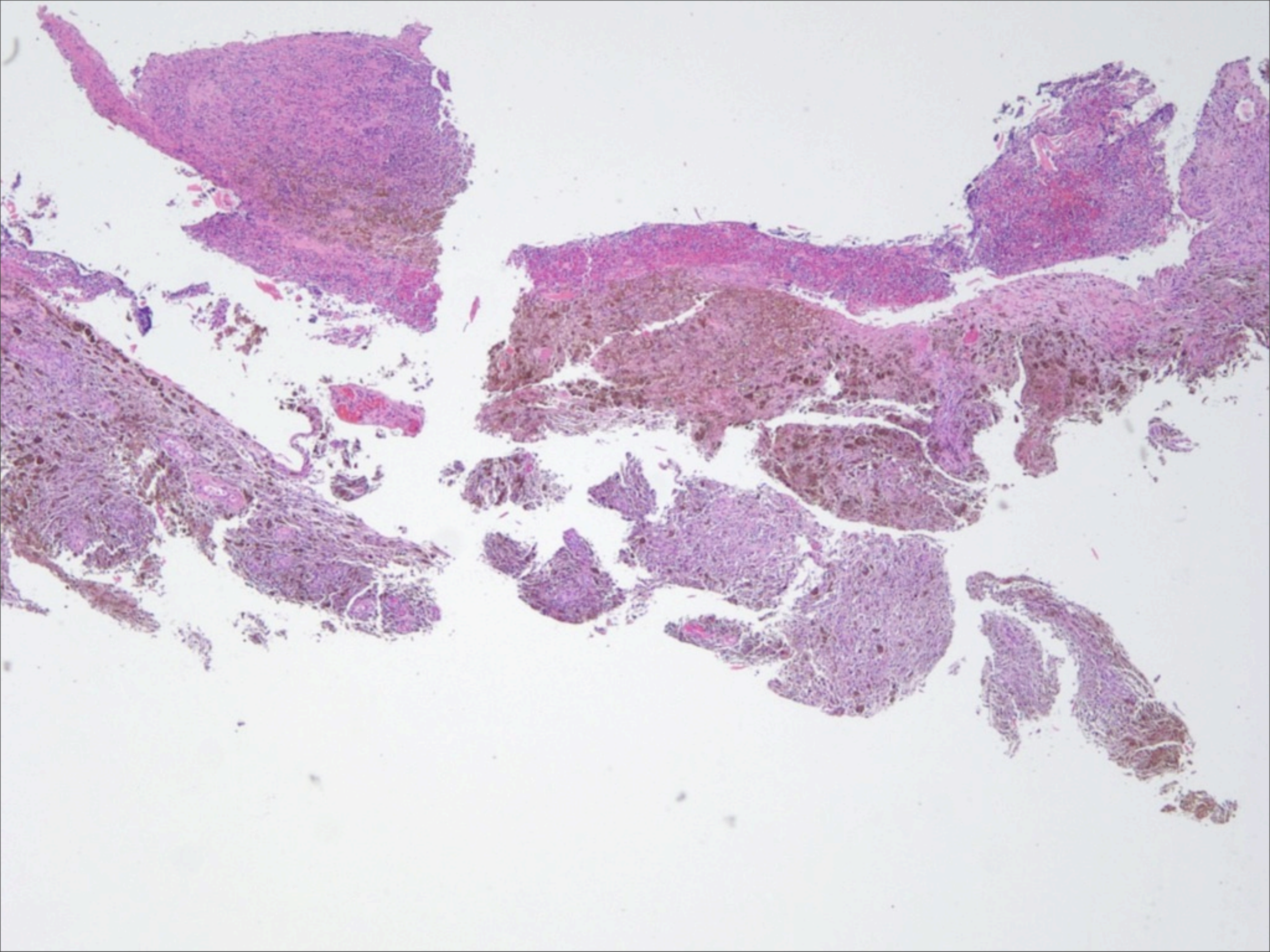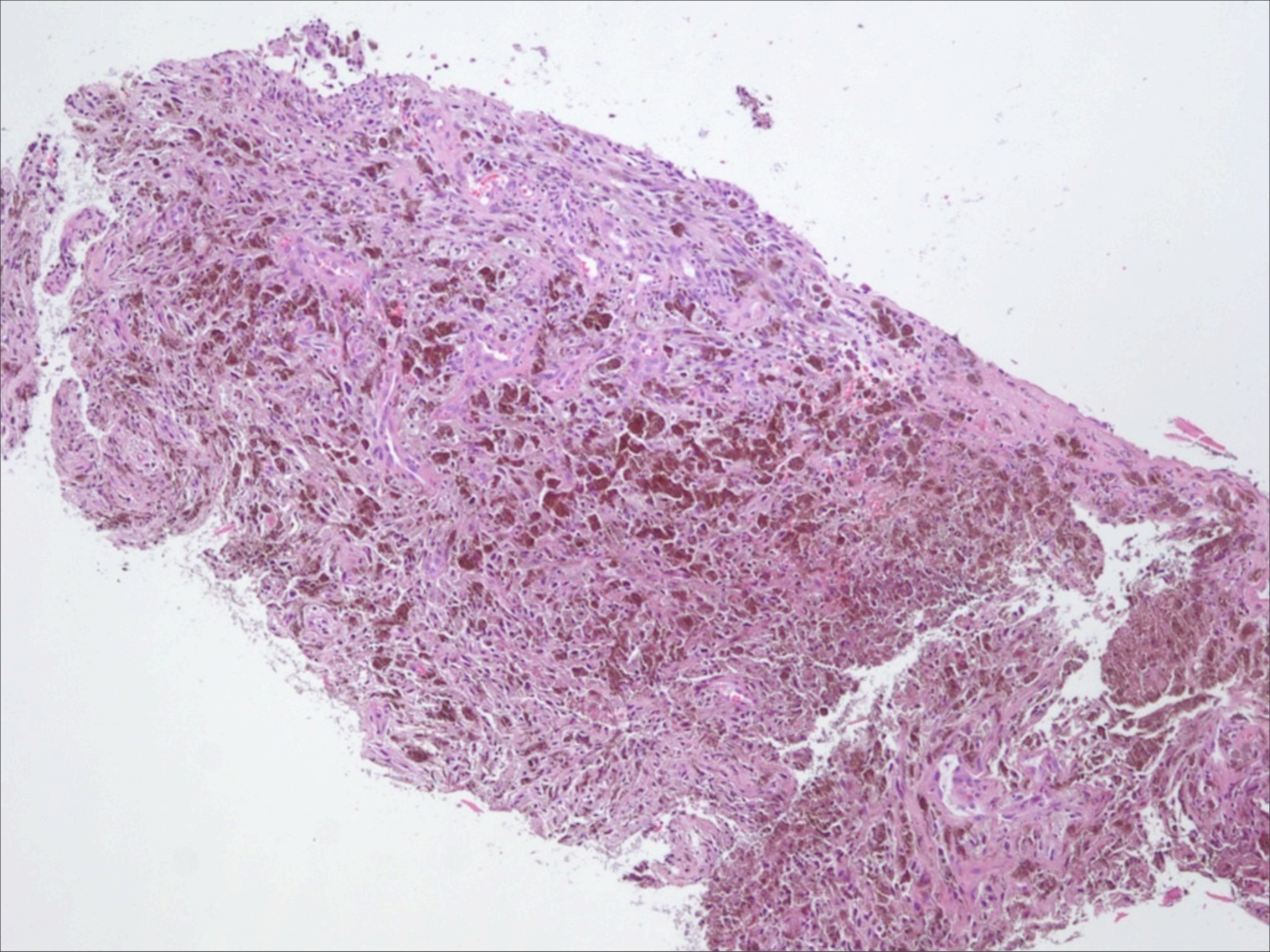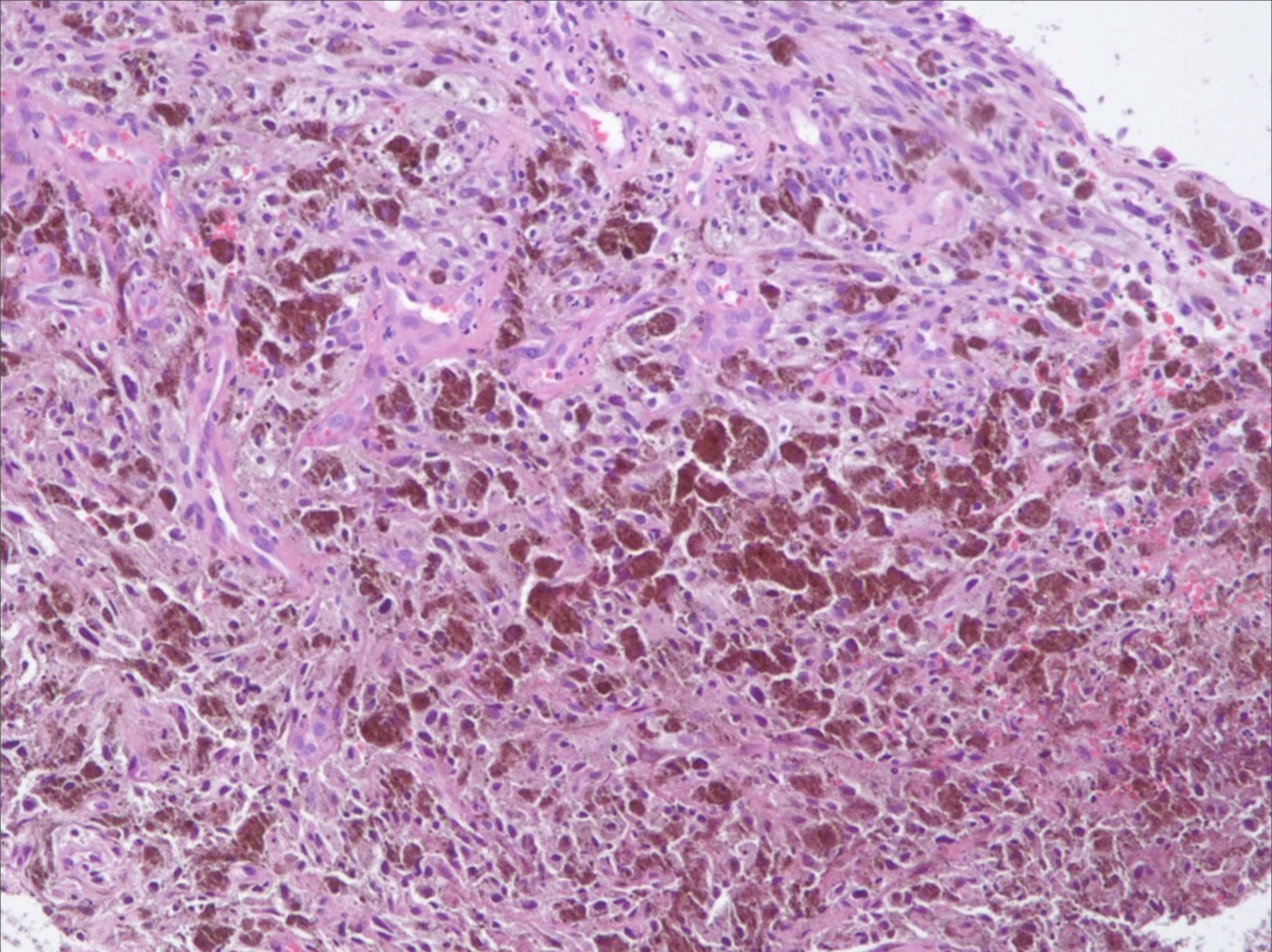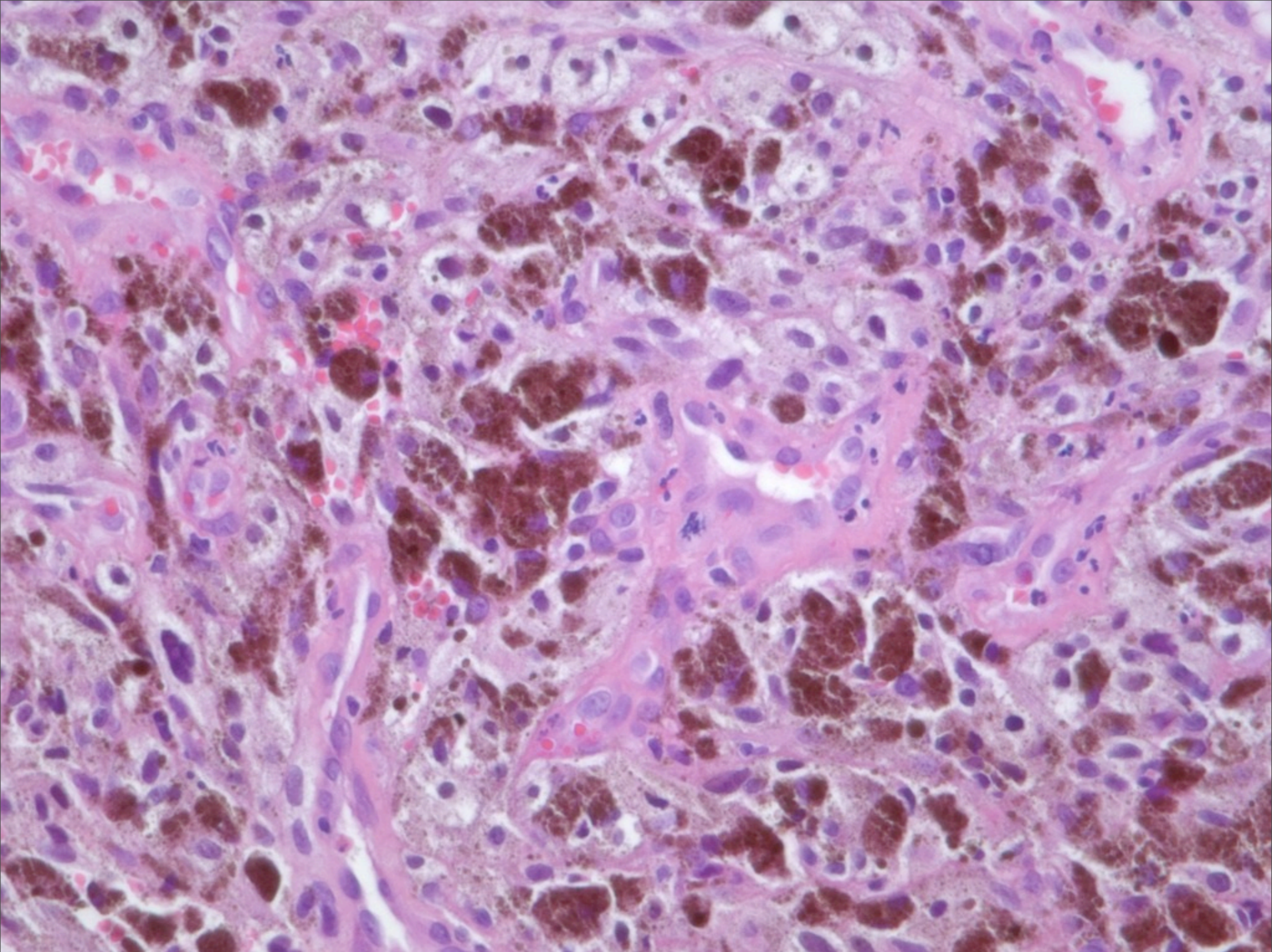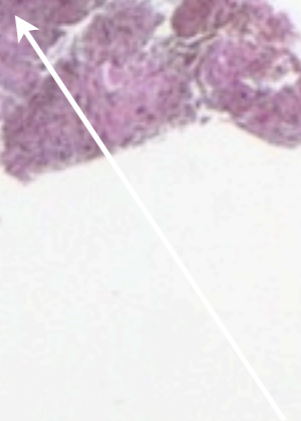
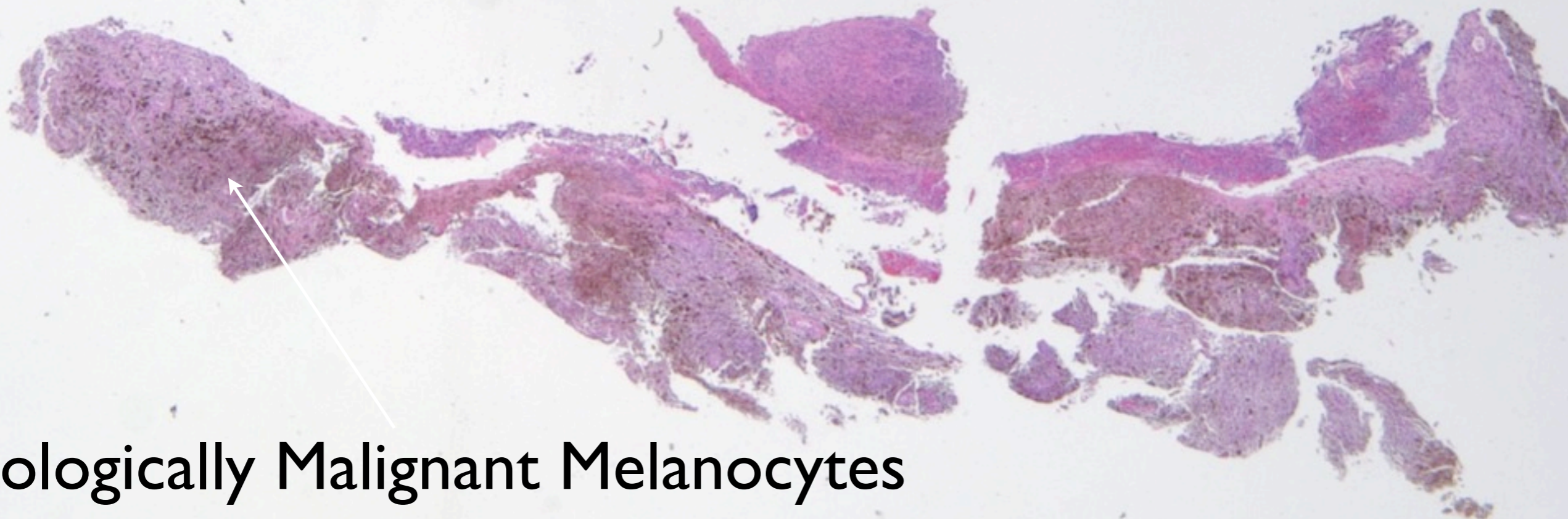
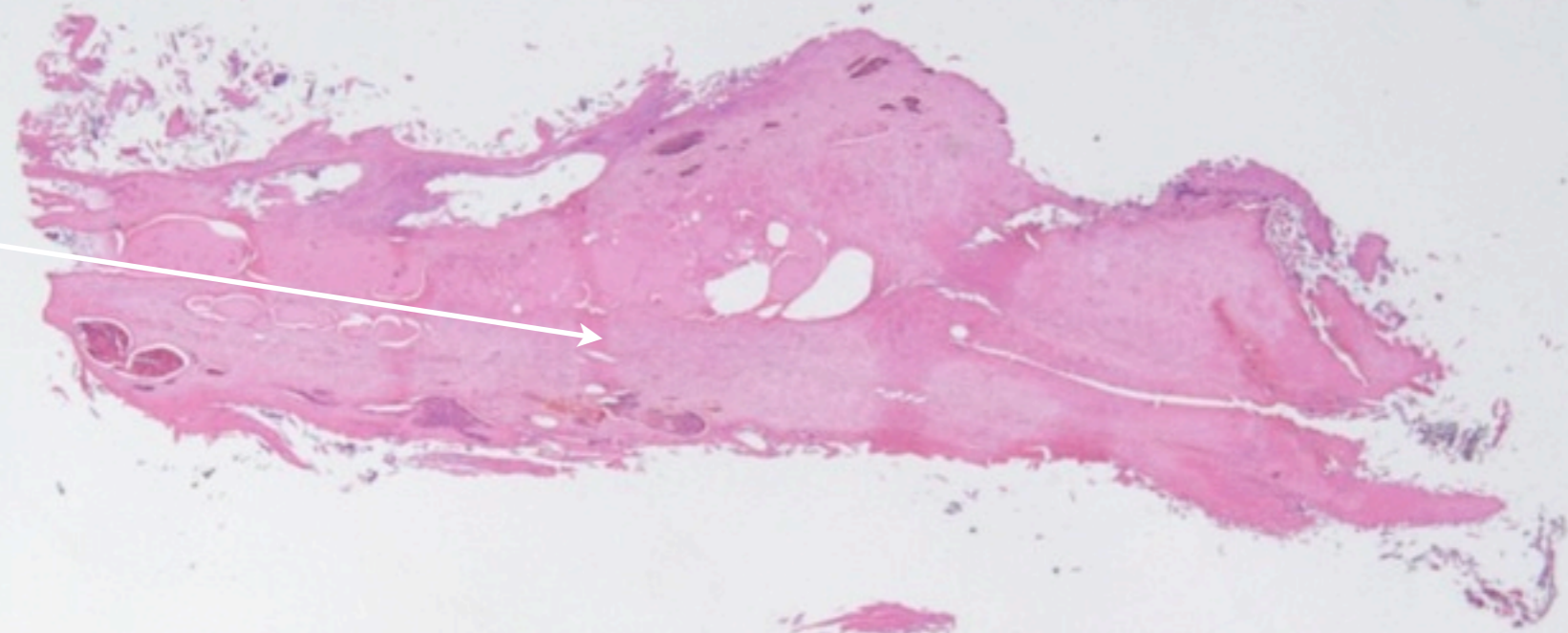
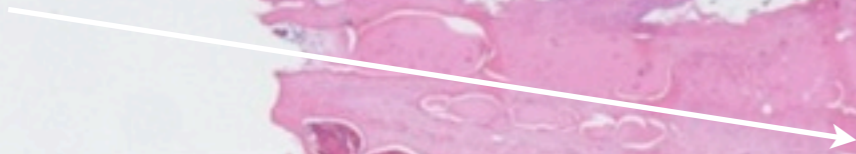


Subungual Melanoma

Nail



Cytologically Malignant Melanocytes